

Evaluation of role of subchondral ulno-radial k wire to avert collapse in non-comminuted extra and intra-articular fracture of distal end radius

Rajendra Butala¹, Vinit Karn^{2,*}, Kuldeep Jain³, Sohrab Ahmed⁴, Udit Kapoor⁵

¹Assistant Professor, ²Registrar, ^{3,4,5}Junior Resident, Dept. of Orthopaedics & Trauma, D.Y Hospital, Navi Mumbai

***Corresponding Author:**

Email: drvinitkarn@gmail.com

Abstract

Background: A prospective study was done in the Department of Orthopedics in D.Y Hospital, Navi Mumbai from October 2015 to February 2017 to evaluate role of subchondral ulno-radial k wire to avert collapse in non-comminuted extra and intra-articular fracture of distal end radius.

Methods: All the patients attending OPD and emergency with non-comminuted distal end radius fracture without ulna fracture were admitted and operated in our hospital over a period of 1 year and 6 months. A total of 30 patients were included in our study and fixed with percutaneous k-wires (Bicortical cross) along with a transverse trans ulno-radial k wire directed from distal ulnar metaphysis to distal radius subchondrally, so as to fix DRUJ & maintain ulnar variance and radial height by preventing its immediate as well as late collapse. AO classification for fractures was used and only type A (extra-articular A1& A2), type C (Complete articular C1) were included. Type B (partial articular) was excluded from study.

Results: All the 30 subjects (n=30) of fracture distal end radius, were managed by closed reduction and percutaneously fixed bicortical k-wires along with subchondrally placed distal trans ulno-radial k wire.

Anatomical evaluation was done according to the Sarmiento's modification of Lindstrom Criteria. Clinical and functional outcomes were evaluated according to the demerit point system of Gartland and Werley with Sarmiento modification.

Conclusion: To accomplish anatomical reduction with DRUJ congruence and neutral to negative ulnar variance along with maintenance of radial height in extra articular and intra articular distal radius fracture only k wire fixation is not competent enough and needs augmentation with trans ulnoradial k wire. Trans ulno-radial k wire provides add-on to rigid fixation and helps in prevention of early and late collapse thus ensuring better anatomical, functional and radiological outcome.

Keywords: Distal radius, Percutaneous Fixation, Transulno radial k wire, Collapse, DRUJ.

Introduction

Ponteau in 1783 was the first to outline fractures of the distal radius which was subsequently named as "Colle's fracture" after Abraham Colle's in 1814. Fractures of distal end radius represents approximately 1/6 of all fractures handled by Orthopaedic surgeons in OPD and emergency. It is one of the commonest injuries of upper extremity. Majority of patients are elderly and osteoporotic (Fragility fractures) and post-menopausal females with history of fall on outstretched hand, whereas in younger individual Fracture of distal radius usually occurs as a result of high velocity trauma where simple Colle's fracture are rare and are usually comminuted. Distal radial fractures presents with dorsal and lateral angulations, shortening due to impaction and articular incongruity plus damage to distal radio ulnar joint which may lead to residual deformity and loss or impairment of functions if reduction achieved does not fall within acceptable criteria's. With emergence of 3D CT reconstruction and MRI it has become possible to understand fracture geometry and architecture and hence management of this fracture has undergone drastic evolution from cast to pinning to plating.

Post operatively anatomical restoration with rigid and resolute fixation is the keystone to minimize the risk displacement and residual deformity and ultimately post traumatic arthritis.

Though conventionally it was treated conservatively, but now a days due to generalized osteoporosis in society with variable presentation of extra as well as intra articular distal radial fractures, only plaster techniques has been obsolete and modalities like Closed reduction plus Percutaneous pinning with plaster has become mainstay.

However only pinning and plastering is not sufficient and augmentation with transverse trans ulno-radial k wire is advisable to prevent early and late collapse and simultaneously stabilize the DRUJ in both young adults as well as in the fragility fractures.

To achieve better anatomical and functional outcome, and impede the chances of early as well as late post reduction collapse, role of trans ulno-radial k wire for the treatment of fractures of distal end radius has been studied.

Materials and Methods

This prospective study was done in Dept of Orthopaedics, D.Y hospital; Navi Mumbai and a total of 30 patients presenting with non-comminuted distal end radius fracture in OPD and emergency without ulna fracture were incorporated.

The inclusion criteria were:

1. Patients willing to undergo procedure with explained consent.

2. Non comminuted fractures of distal radius (may or may not with ulnar styloid) with radiographic displacement of
 - a. More than 15 degree of angulations (Volar or dorsal)
 - b. Positive Ulnar Variance
 - c. More than 2mm of radial shortening
1. Patients above 18 and below 60 years of age.
2. Patients without other associated fractures in the ipsilateral upper limb.

Patients were excluded from study who presented with

1. Compound fractures of distal radius. Barton and severely comminuted fractures were not included.
2. Pathological fractures and fractures with Diaphyseal extension and Poly trauma patients with expected delay in primary and immediate fixation were also excluded.
3. Immune-compromised patients, uncontrolled Diabetes, chronic steroid therapy and severely debilitated.

All the patients were evaluated clinically and radiographic examination was done. Antero-posterior (AP) and lateral views of the wrist joint on both sides were obtained before giving slab. The radiographs were assessed on the basis of loss of palmar tilt or presence of dorsal tilt, radial shortening (Ulnar variance) and loss of radial inclination. AO classification into type A (extra-articular), type C (complete articular) was used and Type B was excluded. All the patients of fracture distal end radius were operated on Elective basis after proper pre-anesthetic Checkup.

Following factors were considered prior to fixation.

1. AO classification based fracture type.
2. Comminution & Quality of bone
3. Age of patient & associated general and medical condition of the patient.

The patients were followed up for maximum up to 12 months years and clinical, radiological and functional outcomes were assessed at 3rd week (when transverse k wire was removed), 6th week, 12th week and 6th month. Transverse k wire was removed at end of 3 weeks by making window in the cast and again dressing was done and cast was retained for total 6 weeks. Radiological assessment was done in terms of residual dorsal angulations, radial shortening (positive ulnar variance) and loss of radial inclination. The results were graded according to the Sarmiento's modification of Lindstrom Criteria. Clinical and functional evaluation was done at the last follow-up according to the demerit point system of Gartland and Werley with Sarmiento et al modification.

Observations

Total 30 patients were included in this study. The youngest patient in this series was 22 years and oldest was 60. Fractures were classified as per AO type. Most common type was A2.

Table 1: Patients as per AO classification

Type	Number of Cases
A1	6
A2	20
C1	4

For anatomical evaluation residual dorsal tilt, radial shortening and radial inclination were evaluated and the results are shown in Table 6. Majority of patients had excellent results in terms of anatomical evaluation.

Table 2: Maximum patients were in age group of 51-65 years contributing to 40%

Age group (years)	Number of Cases
20-35	8
36-50	10
51-65	12

Table 3: There were 11 male (36.6%) and 19 females (63.6 %)

Sex	Number of Cases
Male	11
Female	19

Table 4. Right being the dominant hand was affected in 21 cases (70%)

Side	Number of Cases
Right	21
Left	9

Table 5: The mode of injury was fall in 22 cases (73.3%) and road traffic accidents in 8 cases (26.7%)

Mode of injury	Number of Cases
Fall	22
RTA	8

Correction of dorsal tilt of the distal radial Articular surface: 73.3% of cases showed excellent results, 23.3% good results in the study showing advantage of this technique in achieving better correction of dorsal tilt.

Correction of radial shortening: The study showed 93.3% excellent result and 6.77 % good results proving its efficacy in preventing late collapse and maintaining radial height.

Correction of radial inclination: The study demonstrated that 93.3% excellent result and 6.77 % good results.

Clinical and functional evaluation was done based on

- a) Residual deformity
- b) subjective evaluation
- c) Objective evaluation
- d) complications.

Residual deformity: None the parameters included had loss of Palmar tilt, presence of dorsiflexion, ulnar and radial deviation which was concomitant with other outcomes as only less than 10% had residual deformity.

Subjective evaluation: None of the patients had poor results. The technique of pin and plaster with distal

transverse ulno radial k-wire had overall excellent subjective evaluation.

Objective evaluation: The loss of movement at wrist and grip strength/pain at the distal radio-ulnar and radio carpal joint were related with the age of patients, residual deformity, inadequate anatomical restoration and patient compliance. Pain at wrist joint was observed in only 10% cases and grip strength was near to normal in almost 90% cases. The result is shown in Table 6.

Complication: Complications found in our study were Reflex Sympathetic Dystrophy (RSD) in 3 patients and Pin track infection was found in 4 patients treated with Pin and Plaster technique.

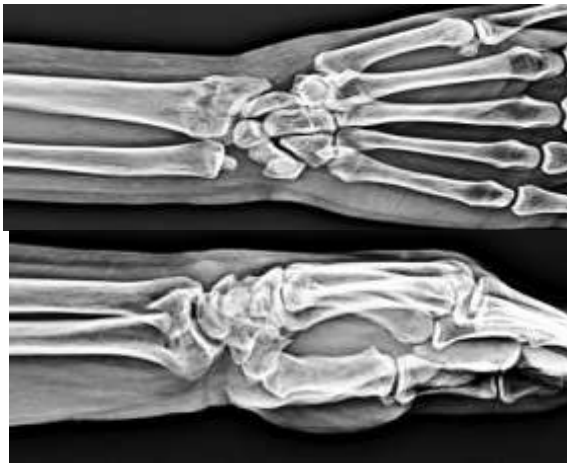Reflex Sympathetic Dystrophy (RSD) responded well to aggressive physiotherapy and was treated conservatively. Pin track infection also responded to dressing and oral antibiotics and resolved.

Table 6: Results of objective evaluation in terms of clinical and functional evaluation

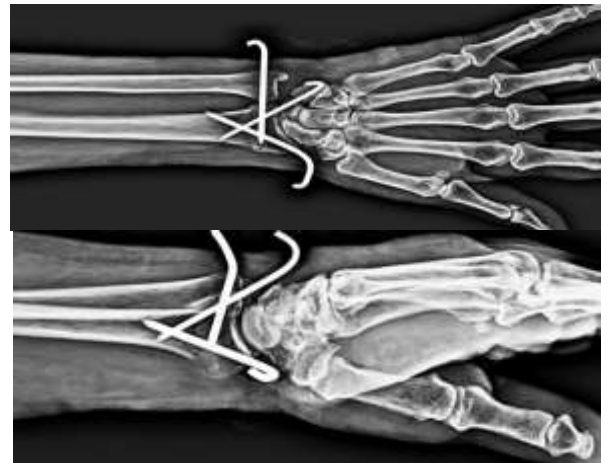
Group	Dorsiflexion <45°	Palmar flexion <30°	Ulnar deviation <15°	Radial deviation <15°	Supination <50°	Pronation <50°	Grip strength <60° of opposite side	Loss of Circumduction	Pain at DRUJ
Pin & Plaster	0	0	0	2	0	0	2	1	3

DRUJ: Distal radioulnar joint

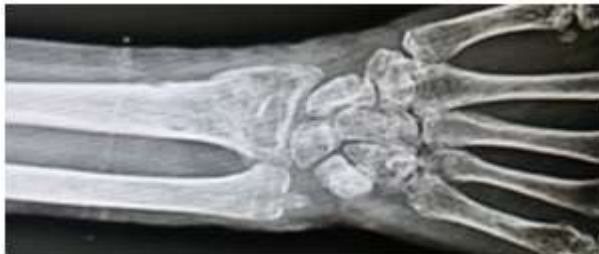Case 1



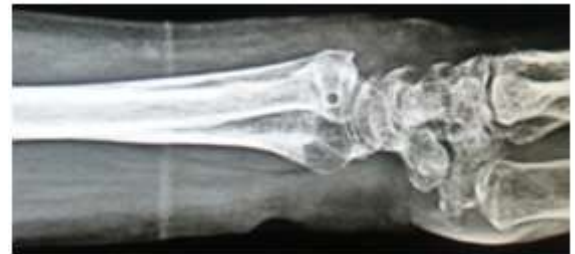Pre-operative X-ray: AP & Lateral (48yr/m)



Post-operative OP X-ray: AP & Lateral



AP & Lateral (12 weeks post op)

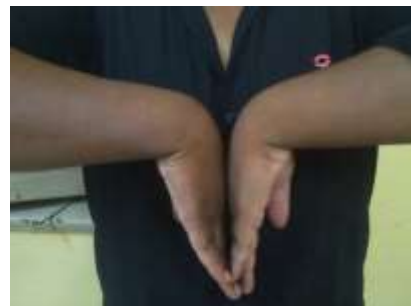

AP & Lateral (12 weeks post op)

Fig. 1



Dorsiflexion (3months)



Palmarflexion(3 months)

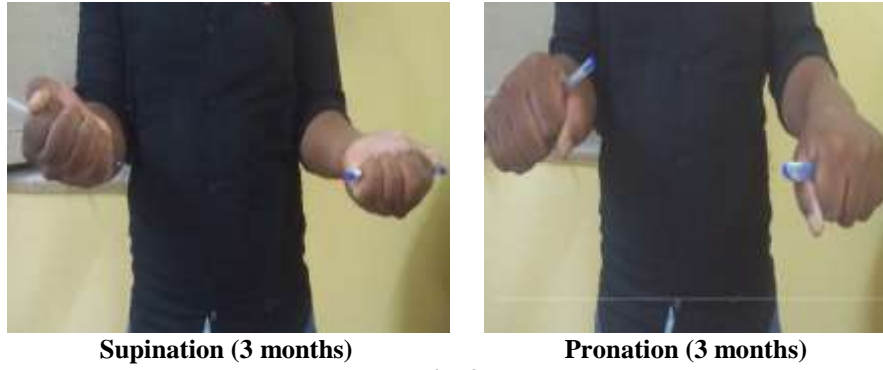

Fig. 2

Case 2

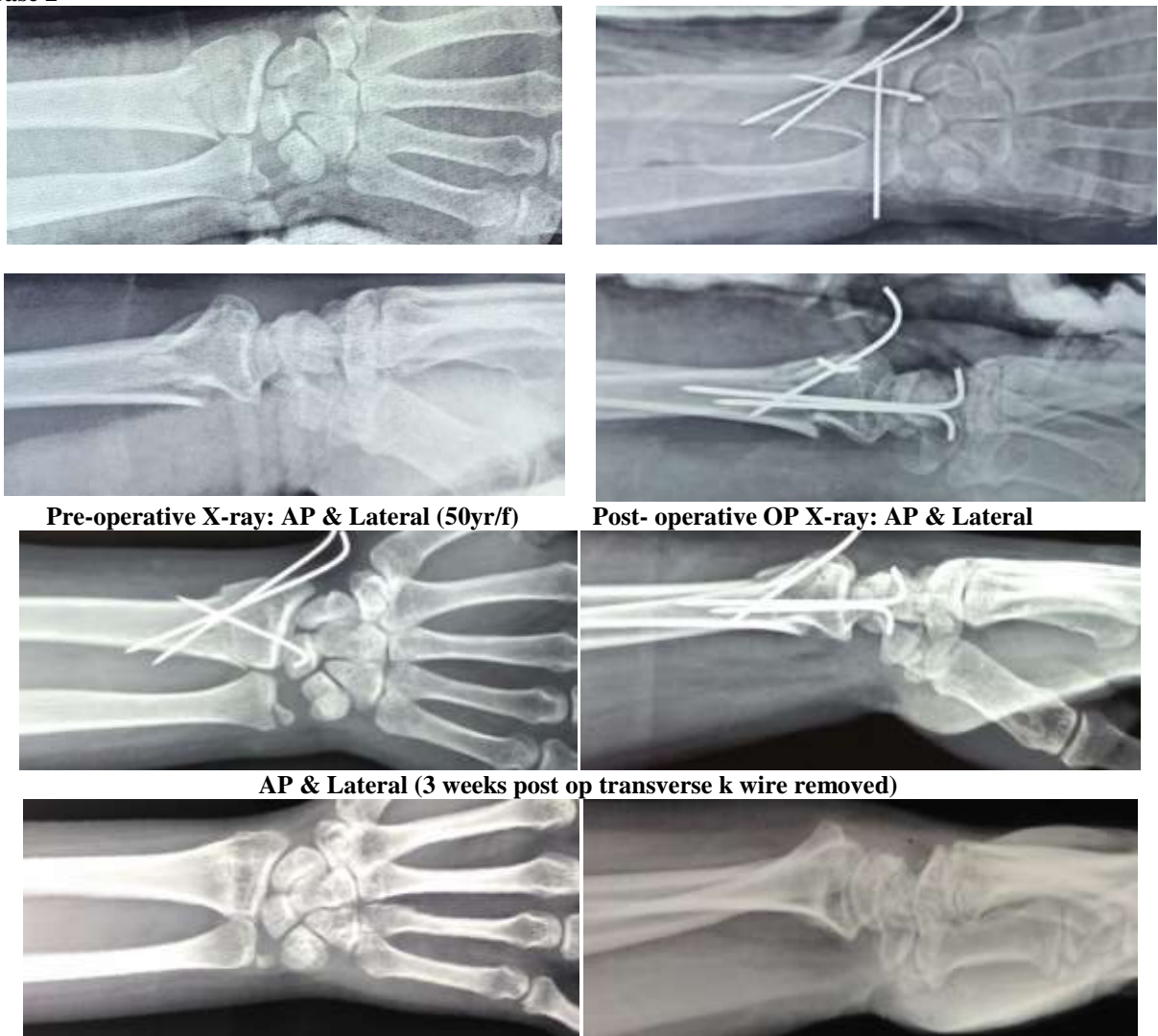


Fig. 3

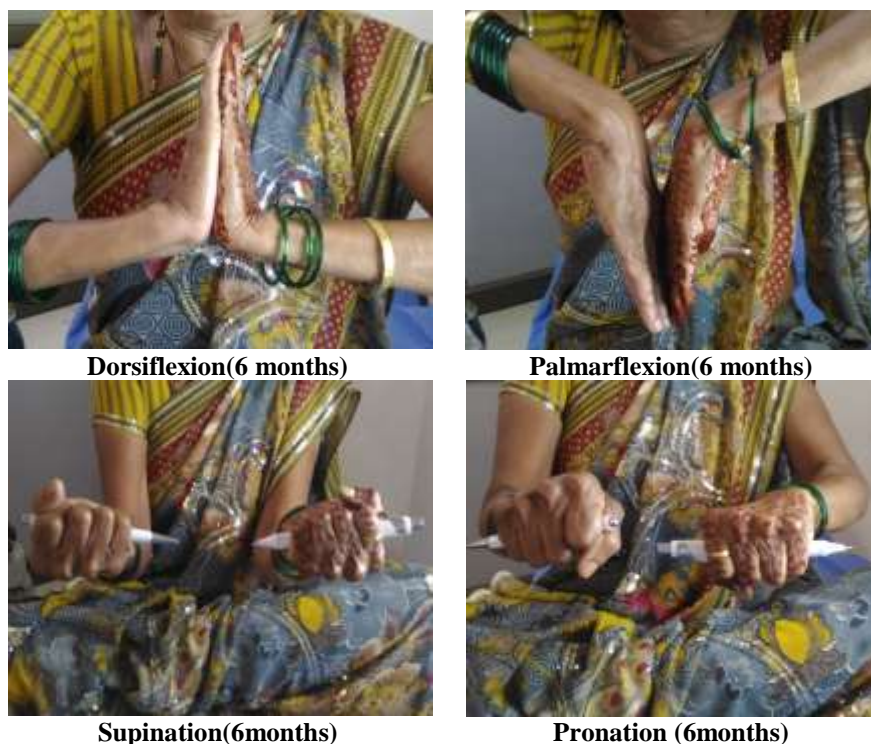

Fig. 4

Conclusion

Fracture distal end radius presents with innumerable types of fracture patterns with archetypal dorsal angulation and tilt, lateral angulation and tilt, supination and impaction. During the reduction of fracture the longitudinal traction disimpacts the collapsed element which is eventually absorbed and results in late collapse which leads to radial shortening or positive ulnar variance. The extent of shortening can be correlated to loss of function and movement at wrist joint. Simplest method of cast application with volar and ulnar tilt is still procedure of choice in primary and secondary centres which can avoid surgery and other complication related to it, however, method of closed reduction and cast doesn't prevent collapse at fracture site. As swelling subsides there may be loosening of the reduction in simple cast with angular displacements and hence bicortical k wire is essential to avoid these complications.

The transverse wire serves to prevent collapse of radius because it was found this collapse was more in patients treated with cast or cross k wires only.

In our study the trans ulno-radial k wire also helps to maintain radio-ulnar stability and variance. Hence use of our surgical technique of insertion of subchondral ulno-radial k wire and keeping in situ for 3 weeks can help to reduce the deformity arising out of collapse and thus resulting in better functional outcomes of these fractures.

References

1. Knirk JL, Jupiter JB. Intra-articular fractures of the distal end of the radius in young adults [J]. *J Bone Joint Surg Am* 1986;68(5):647-597.
2. Kurup HV randomized clinical multi-center trial. Trials, Mandalia V, Shaju A, Beaumon A. Bicortical K-wires for distal radius fracture fixation: 2011;12:84. How many? *Acta Orthop Belg* 2007 12.
3. Sarmiento A, Pratt GAW, Berry NC, et al. Colles' fractures. Functional bracing in supination [J]. *J Bone Joint Surg Am* 1975;57(3):311-7.
4. Gartland JJ, Werley CW. Evaluation of healed Colles' fractures. *J Bone Joint Surg Am* 1951;33(4):895-907.
5. Gartland JJ, Werley CW: Evaluation of healed Colles' fractures, *J Bone Joint Surg Am* 33:895-907,1951.
6. Leung F, Ozkan M, Chow SP. Conservative treatment of intra-articular fractures of the distal radius—factors affecting functional outcome [J]. *Hand Surg* 2000;5(2):145-53.
7. Smilovic J, Bilic R. Conservative treatment of extraarticular Colles' type fractures of the distal radius: prospective study [J]. *Croat Med J* 44(6):740-5.
8. Haus BM, Jupiter JB. Intra-articular fractures of the distal end of the radius in young adults: reexamined as evidence based and outcomes medicine [J]. *J Bone Joint Surg Am* 2009;91(12):2984-91.
9. Singer BR, McLauchlan GJ, Robinson CM, et al. Epidemiology of fractures in 15,000 adults: the influence of age and gender [J]. *J Bone Joint Surg Br* 1998;80(2):243-8.
10. Kreder HJ, Hanel DP, McKee M, et al.: Consistency of AO fracture classification for the distal radius, *J Bone Joint Surg Br* 78:726-731,1996.
11. Rahul R Bagul, Ashwin D et al.: *MJDRDYPU* 2014 Volume: 7 Issue: 5 Page: 590-595.
12. Moroni A, F Vannini, C Faldini, F Pegreff: Cast Vs External Fixation: A Comparative Study in Elderly

- Osteoporotic Distal Radial Fracture Patients, Scandinavian Journal of Surgery 93: 64–67, 2004.
13. Chin-En Chen, Rei-Jahn Juhn, Jih-Yang Ko. T 11. Treatment of Distal Radius Fractures with Percutaneous Pinning and Pin-in-plaster fractures of the distal radius: *Hand* 2008;3:245-50.
 14. DePalma AF: Comminuted fractures of the distal end of the radius treated by ulnar pinning, *J Bone Joint Surg Am* 34:651-662, 1952.
 15. Handoll HH, Vaghela MV, Madhok R: Percutaneous pinning for treating distal radial fractures in adults, *Cochrane Database Syst Rev* 3:CD006080, 2007.