

## Direct lateral approach to shaft of radius – a cadaver study

Backiaraj Devaraj<sup>1\*</sup>, A. Navaneethan<sup>2</sup>

<sup>1</sup>Assistant Professor, Dhanalakshmi Srinivasan Medical College & Hospital, Tamil Nadu, <sup>2</sup>Professor, Dept. of Orthopaedics, Chennai Medical College & Research Centre, Trichy, Tamil Nadu

**\*Corresponding Author:**

Email: backyacoll@yahoo.co.in

### Abstract

**Introduction:** Shaft of radius is traditionally approached by Henry's volar approach and Thomson's dorsal approach. Direct lateral approach is described by Muhammed Hanif et al in 2014. We wanted to evaluate the direct lateral approach through cadaver study.

**Materials and Method:** Direct lateral approach utilizes the plane between brachioradialis (BR) and extensor carpi radialis longus(ECRL). Ten forearms from 5 adult cadavers were used for this study. We evaluated the anatomic features of the plane and limitations of this approach.

**Results:** Direct Lateral approach provides 64.5% of radius on lateral aspect without sacrificing any major neuro vascular structure. The average distance of posterior Interosseous nerve from radiocapitellar joint is 3.5 cm. Abductor pollicis longus(ABL) and extensor pollicis brevis(EPB) crosses the radius from posterior to lateral at 5.1 cm from the tip of radial styloid.

**Conclusions:** Shaft of radius can safely be exposed by direct lateral approach. It has some disadvantages which could be addressed with our modification of using the plane between ECRL and Extensor carpi radialis brevis(ECRB) for the proximal exposure. But we need more clinical studies to consider this as an alternate approach to shaft of radius exposure.

**Keywords:** Lateral approach to radius, Exposure of radius, Forearm fracture, Radius fracture.

### Introduction

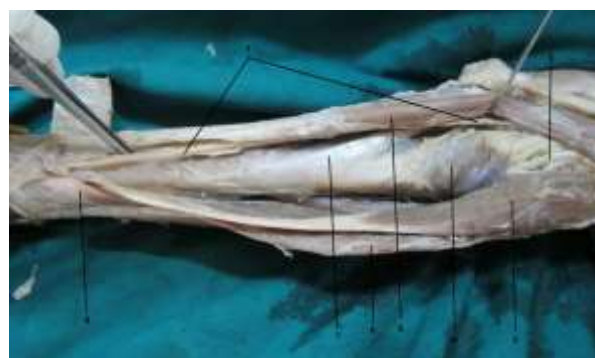Both bone fracture forearm and isolated radial shaft fractures are treated with open reduction and fixation with dynamic compression plates. Commonly used approaches for diaphyseal fractures of the radius are the Henry's volar approach<sup>(1)</sup> and Thompson's dorsal approach.<sup>(2)</sup> Henry's approach utilizes the internervous plane between BR and pronator teres and flexor carpi radialis. Thompson's approach is through the plane between ECRB and extensor digitorum. Both the approach has its own advantages and disadvantages.

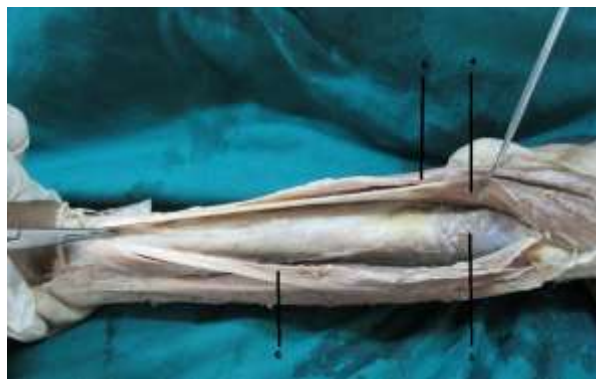
Direct lateral approach is described by Muhammed Hanif et al<sup>(3)</sup> in 2014. This is performed through the plane between BR and ECRL. BR originates from upper two third of lateral supracondylar ridge and inserted into base of radial styloid. ECRL originates from lower third of lateral supracondylar ridge of humerus, along with the tendon of ECRB, it passes beneath the extensor pollicis brevis (and abductor pollicis longus in distal forearm through the 2<sup>nd</sup> extensor compartment of wrist and get inserted into base of second metacarpal bone. Both the muscles are innervated by radial nerve before it divides as superficial radial nerve (SRN) and posterior interosseous nerve (PIN).

### Materials and Method

The direct lateral approach to radius was performed in 5 fresh-frozen adult cadavers (ten upper-limb specimen). None of the specimen had evidence of previous surgery or trauma about the elbow, forearm or wrist. All procedures were performed by a single orthopedic surgeon in the following manner.

Limbs were positioned in full supination and the lateral aspect facing upward. Incision was made from lateral most part of flexor crease of elbow (middle of mobile wad of Henry) to the base of anatomical snuff box. Subcutaneous tissue and fascia were incised along the skin incision. Branches of antebrachial cutaneous nerve and cephalic vein were crossed in the proximal half of the wound during our exposure. ECRL was identified by its longest tendon. The plane between BR and ECRL was identified more clearly in distal part of wound. By retracting the BR volarly and the ECRL dorsally we exposed the lateral surface of radial shaft. It is covered with supinator in proximal third, Pronator teres(PT) in middle third(Fig. 1). The distal third was free from muscle attachment, but it was crossed by tendon of first dorsal compartment which contains Abductor pollicis longus (APL) and extensor pollicis brevis(EPB) and SRN. PIN was exposed by splitting the supinator muscle.





1. Superficial radial nerve
2. Posterior interosseous nerve
3. Extensor carpi radialis longus
4. Supinator
5. Brachioradialis
6. Extensor carpi radialis brevis
7. Pronator teres
8. Abductor pollicis longus tendon

Following four measurements were recorded using digital caliper:

1. Total length of Radius (distance between the tip of radial styloid to radiocapetellar joint)
2. The distance between radiocapetellar joint and PIN where it crosses the midpoint of lateral surface of Radius.
3. The distance between tip of radial styloid to proximal border of APL tendon on midpoint of lateral surface of Radius.
4. Total length of radius was exposed by this approach. (distance between the PIN and APL)

## Results

There were two male cadavers and three female cadavers and its average age was about 73.3 years (range 57-86 years). There were 5 right and 5 left upper extremities and its average height was about 171 cm (range 181.2-178.6).

Average length of radius was 24.26 cm (range 23.3-25.1). Average distance between radiocapetellar joint to PIN was 3.9 cm (range 1.5-4.6). Average distance between tip of radial styloid to proximal border of APL tendon on midpoint of lateral surface of Radius was 5.1 cm (range 4.5 – 5.7). Average length of radius exposed was 15.65cm (range 16.2-19.7) and its total percentage length of radius measuring about 64.5% (range 60.7%-71.1%).

Specimen no	A	B	C	D	D%
1R	23.8	3.6	4.8	15.4	64.7
1L	23.8	3.1	4.5	16.2	68.1
2R	24.9	1.5	5.7	17.7	71.1
2L	24.9	2.7	5.9	16.3	65.4
3R	24.2	4.3	5.2	14.7	60.7

3L	24.2	4.6	5.4	14.2	58.6
4R	23.3	3.8	4.6	14.9	63.9
4L	23.3	3.4	4.5	15.4	66.1
5R	25.1	4.2	5.3	15.6	62.1
5L	25.1	3.9	5.1	16.1	64.1
Average	24.26	3.5	5.1	15.65	64.5

- A. Total length of Radius (between the tip of radial styloid to radiocapetellar joint)
  - B. The distance between radiocapetellar joint and PIN where it crosses the midpoint of lateral surface of Radius.
  - C. The distance between tip of radial styloid to proximal border of APL tendon on midpoint of lateral surface of Radius.
  - D. Length of radius exposed. (between the PIN and APL)
- D% Length of radius exposed in percent.

## Discussion

Open reduction with internal fixation and compression plating is the standard treatment for diaphyseal fracture of radius. Traditionally Hendry (volar) approach and Thompson (dorsal) approach were used to expose the radius shaft. Internal fixation with plates allows excellent control for fracture fragments and there by permits accurate restoration of the anatomy. It remains the key principle in treating forearm fractures as it preserves the maximum forearm function.<sup>(4,5,6)</sup>

Volar approach<sup>(1)</sup> is the plane between the brachioradialis and pronator teres (proximally)/ flexor carpi radialis (distally). The radial artery is retracted medially for deep dissection. For which the branches of radial artery to brachioradialis needs to be sacrificed. This approach also involves dividing or elevating the pronator teres tendon and elevating the origin of flexor pollicis longus / pronator quadratus from the radius for further application of plate on the volar surface.<sup>(7)</sup>

Dorsal approach<sup>(2)</sup> is the plane between the extensor digitorum communis and extensor carpi radialis brevis. This approach involves the identification and preserving the PIN and its branches. This approach is limited by the first compartment distally and the posterior interosseous nerve proximally and also sacrifices no arterial branches. But there are chances for the paralysis of the extensor digitorum communis.<sup>(8)</sup>

Direct lateral approach<sup>(3)</sup> utilizes the plane between BR and ECRL. Unlike volar and dorsal approaches the Lateral approach is devoid of major neurovascular structures. By this approach we can expose 64.5% of radius on the lateral aspect. Like dorsal approach, it is also limited by the first compartment distally and the posterior interosseous nerve proximally. Advantages of this approach, its devoid of major neurovascular structure and it is safer compared to other alternate

approaches available. So the operating time also decreases.<sup>(3)</sup> Plates can be contoured and applied on the tensile surface (lateral) of radius. This provides better stability to the construct.

The concerns of direct lateral approach are the close proximity of the SRN in the proximal most and distal most part of exposure. The plane of ECRL is anterolateral to the shaft of radius and it needs to be retracted posteriorly for lateral plate application. To avoid these, we recommend the plane between ECRL and ECRB for proximal exposure (Fig. 2). This approach is away from BR and SRN. The plane of ECRB is posterolateral to the shaft of radius so not much retraction is needed for lateral plate application. However the distal part of exposure remains the same (between ECRL and ECRB tendons and BR tendon).

### Conclusion

The lateral surface of radial shaft between PIN and APL can be exposed safely with direct lateral approach. It has the advantages of without any major neurovascular structure, less operating time and plate application over tensile surface.<sup>(3)</sup> It has some disadvantages which can be avoided by using the plane between ECRL and ECRB for the proximal exposure. But before recommending this approach as an alternative to the other standard approaches we need to prove these findings by more clinical studies.

### References

1. Henry AK. Complete exposure of the radius. In: Exposures of Long Bones and Other Surgical Methods. Bristol, England: John Wright & Sons Ltd 1927;9-12.
2. Thompson JE. Anatomical methods of approach in operations on the long bones or extremities. *Ann Surg.* 1918;68(3):309-29.
3. Muhammad Hanif, Muhammad Saeed Akhtar, Raza Elahi Rana, Shahzad: Direct Lateral Approach to Shaft of Radius. *Journal of Pakistan Orthopaedic Association* 2014;26 (3):11-14.
4. Anderson LD, Sisk D, Tooms RE, et al: Compression-plate fixation in acute diaphyseal fractures of the radius and ulna. *J Bone Joint Surg Am* 1975;57(3):287-287.
5. Rosacker JA, Kopta JA. Both bone fractures of the forearm: A review of surgical variables associated with union. *Orthopaedics* 1981;4:1353-1356.
6. Schemitsch EH, Jones D, Henley MB, et al. A comparison of malreduction after plate and intramedullary nail fixation of forearm fractures. *J Orthop Trauma* 1995;9(1):8-16.
7. Louis W. Catalano III, Dan A. Zlotolow, Phillip B. Hitchcock, et al. Surgical Exposures of the Radius and Ulna: review article. *J Am Acad Orthop Surg* 2011;19:430-438.
8. Spinner RJ, Berger RA, Carmichael SW, Dyck PJ, Nunley JA. Isolated paralysis of the extensor digitorumcommunis associated with the posterior (Thompson) approach to the proximal radius. *J Hand Surg Am.* 1998;23(1):135-41.