

## Management of distal tibial metaphyseal fractures by expert tibial nail

Ramachandra N. Badami<sup>1,\*</sup>, M. Shantharam Shetty<sup>2</sup>, M. Ajith Kumar<sup>3</sup>

<sup>1</sup>Senior Resident, <sup>2</sup>Chairman & Professor, <sup>3</sup>Senior Consultant, Dept. of Orthopaedics, Tejasvini Hospital & SSIOT, Mangalore

**\*Corresponding Author:**

Email: rmbadami@gmail.com

### Abstract

**Introduction:** Distal tibial metaphyseal fractures causes extensive musculoskeletal damage and needs an accurate fixation with minimal soft tissue damage. The optimal method of fixation remains debatable. Open reduction and internal fixation cause devascularizing fracture fragments with soft tissue and skin problems. Intramedullary nailing interlocking tibial nails are reported with high complication rates. Expert Tibia Nail (ETN) provides an alternative to these fractures. We studied the efficacy of the ETN in treating distal tibial metaphyseal fractures.

**Materials and Method:** We did a retrospective analysis of distal tibial metaphyseal fractures treated with ETN done between June 2010-May 2012. 72 patients with AO type 4.3. A1, A2, A3 were included in the study. The outcome was assessed based on fracture union, fracture alignment, range of knee and ankle movements, secondary procedure rate and postoperative complications within 1yr.

**Results:** The average time of fracture healing was 16 wks. Delayed union was seen in 11.11%. Reoperation rate including dynamisation was 12.5%. Primary malalignment was reported in 6.9% of the cases and 2.7% had secondary malalignment. Majority of patients had good to excellent knee and ankle range of motion. Four patients had wound dehiscence and 3 had infections.

**Discussion:** The results of our study validate the efficacy of ETN in distal tibial metaphyseal fractures. Fracture union was demonstrated in about 90% of the cases within 6 months of surgery and all patients achieved fracture union within 1 year after surgery. Stability and alignment of fracture were achieved with an additional fixation of fibula without increasing risk of delayed union. Expert tibia nail due to its multiplanar locking options, locking option at the tip of nail, provides angular stability.

**Conclusion:** ETN provides stable internal fixation, early ROM knee and ankle, provides angular stability and hence provides excellent clinical and radiological outcome.

### Introduction

Fractures of the distal tibial metaphysis often result from high-energy trauma combined with extensive soft-tissue damage. Treatment is often complicated by contusion, infections, delayed-union and non-union, all pointing to secondary or revision surgeries.<sup>(1)</sup> Distal tibial metaphyseal fractures needs a stable fixation while minimizing damage to the soft tissues by the surgical dissection and implants. The optimal method of fixation remains debatable. Open reduction and internal fixation has its issues of devascularizing the bone fragments and also causes problems of soft tissue and the surgical wound. Minimal invasive percutaneous plate osteosynthesis (MIPPO) reduces these risks, but has a risk of secondary skin necrosis due to prominence of precontoured and angular stable plates, especially in older patients with a compromised and very thin soft tissue sleeve.<sup>(2,3)</sup> Intramedullary nailing minimizes surgical trauma to the fracture and soft tissues and provide stability at the fracture site, hence is considered to be the gold standard for tibial shaft fractures.<sup>(4,5,6,7)</sup> But the same in distal tibial fractures are reported with high rates of primary and secondary malalignment, delayed union and increased reoperation rates.<sup>(8,9,10)</sup>

Expert Tibia Nail was designed as an adaption of the regular tibial interlocking nail specially designed for the metaphyseal fractures. They provide additional biomechanical stability than the conventional nails and plate osteosynthesis.<sup>(11,12)</sup> ETN has multiple proximal

and distal locking options and hence is useful in all extraarticular tibia fractures. It has five locking options in proximally and four locking options distally in various planes.<sup>(13)</sup> This design of the implant helps in achieving stable fixation and improved locking in most extraarticular tibial fractures.

In this study we reported our experience of Expert Tibia Nail in treating distal tibial metaphyseal fractures and its efficiency as an implant in such fractures.

### Materials and Method

We conducted a retrospective study after obtaining the ethical committee clearance. We studied 72 Cases of distal tibial metaphyseal fracture treated by Expert Tibia Nail (ETN; Synthes AG, Switzerland) from June 2010 to May 2012. The age of the patients ranged from 18 to 65 yrs with a mean age of 36 yrs. Road traffic accident was the most common mode of injury in the study.

All the fractures were within 5 cm of the tibial plafond and were classified using AO/ASIF classification.<sup>(14)</sup> Fractures types 4.3. A.1, A.2 & A.3 were included in the study. There were 23 patients with A1 type fractures, 25 patients with A2 type fractures and 24 patients with A3 type fractures. 15 of the 60 fractures were open fractures. They were classified based on Gustilo Anderson classification.<sup>(15)</sup> Of which 7 were Gustilo Anderson type-1, 6 were type-2 and 2 were type-3 open fractures. Patients with multiple injuries

were excluded from the study. Open fractures were thoroughly debrided; fractures reduced and nailed using the same nailing system. Immediate skin cover was given by a plastic surgery team.

Surgeries were performed with the knee flexed at 90–100 degrees on a radiolucent fracture table. Closed reduction of the fractures were achieved. The entry point was taken at the anterior edge of the tibial plateau in line with the intramedullary canal.<sup>(16)</sup> Guide wire passed, serial reaming done. The length, axis and rotation were restored and the appropriate size ETN was inserted. Distal locking was done by free hand technique. Fracture gap, if any, was closed with a backstroke technique. Proximal interlocking was done with the help of the jig. At least 2 distal locking and 1 proximal locking was achieved in all cases. 38 patients had concomitant fibula fractures. Those within 5 cm of the syndesmosis were fixed with a 3.5 system 1/3<sup>rd</sup> tubular plate (23 fractures). Distal fibula fixation was done first followed by the tibia nailing surgery.

Postoperatively the patients were started on non weight bearing mobilization immediately for about 4 wks, along with knee bending and quadriceps exercises. The patients were followed up monthly for 1<sup>st</sup> 3 months followed by bi monthly visit thereafter till the fracture union or up to a maximum of 1yr. At each follow up patients were clinically and radiologically assessed. X-ray of leg with ankle in AP and lateral views were taken. Fracture union and the fracture alignment were noted on the radiographs in each follow up. Also, the knee and ankle range of motion was measured. Soft tissue healing and the associated complications were noted.

The outcome was assessed on following parameters: Fracture union, fracture alignment, range of knee and ankle movements, secondary procedure rate and postoperative complications within 1yr. Delayed union was defined as an obvious progress in fracture healing but lacks complete union at the fracture site at the 6 month follow-up. Deformities (varus/valgus, re-/ante-curvatum, malrotation and shortening) and malalignment or loss of alignment was assessed by the method of Freedman and Johnson<sup>(17)</sup> from radiographs taken immediately after surgery and during follow-up. Range of motion of knee and ankle was graded into excellent (difference within 10<sup>0</sup> of the range on normal side), good (difference between 10<sup>0</sup> – 20<sup>0</sup> of the normal side) and poor (difference greater than 20<sup>0</sup> of the opposite side).

## Results

The average time of fracture healing was 16 wks with an average of 14.1 wks for A1, 15.6 wks for A2 and 21 wks for A3 fractures. Delayed union was seen in 8 patients (11.11%), of which 2 were AO type A1 fractures, 2 were A2 type fractures and 4 were A3 fractures. Of which 5 cases were open fractures and 3 was closed. In 4 of the 8 delayed unions fibula plating

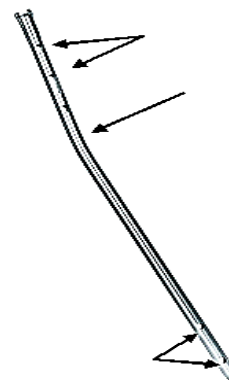
was done and in 4 cases of delayed union fibula was not plated. In this study, fibula plating was done for fibula fractures from 5cm of the syndesmosis. Both factors for delayed union in distal metaphyseal tibial fractures were statistically insignificant. There were no cases of non union.

There were 5 cases (6.9%) with primary malalignment, of which 4 cases had valgus angulation of the fracture of about 5-8 degrees and one patient had external rotation malalignment (<5 degrees). We also found a secondary malalignment (loss of primary alignment) in 2 cases (2.7%). Both cases were A1 type fractures with a long spiral element.

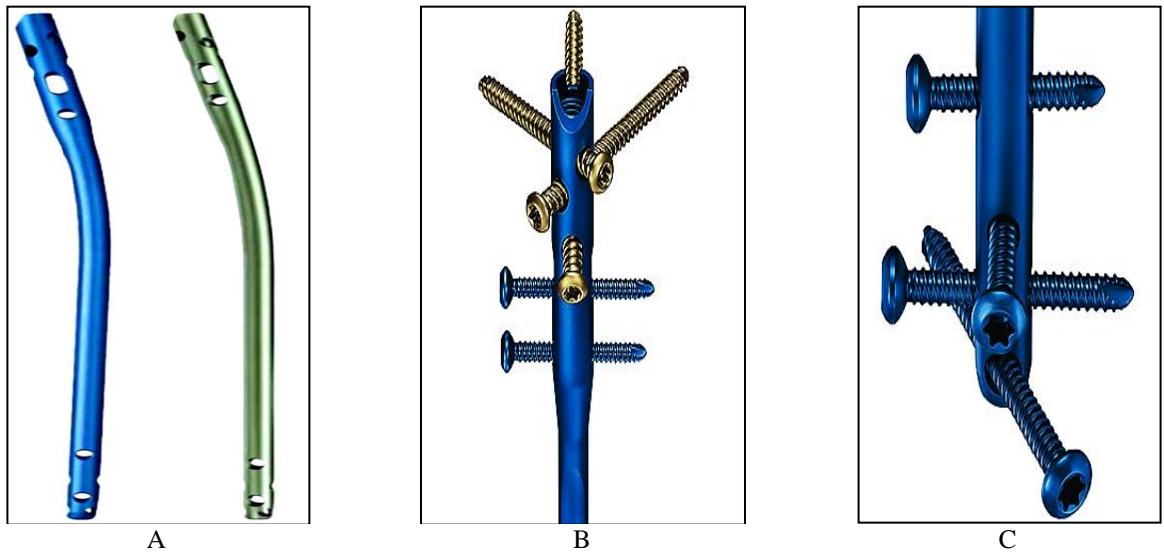
With respect to knee and ankle range of motion 56 patients (77.77%) were graded as excellent, 12 patients (16.66%) as good and 4 patients (5.55%) as poor.

There were no cases of screw breakage or any implant related problems. Soft tissue/wound complications were reported in 4 cases (5.55%), 3 of which were on the fibular side. Infection was documented in 3 cases (4.16%). Of which 1 was a superficial infection which subsided with IV antibiotics. Whereas other 2 were deep infections, both of which were open fractures. There were no cases of compartment syndrome, thrombosis or death in our series.

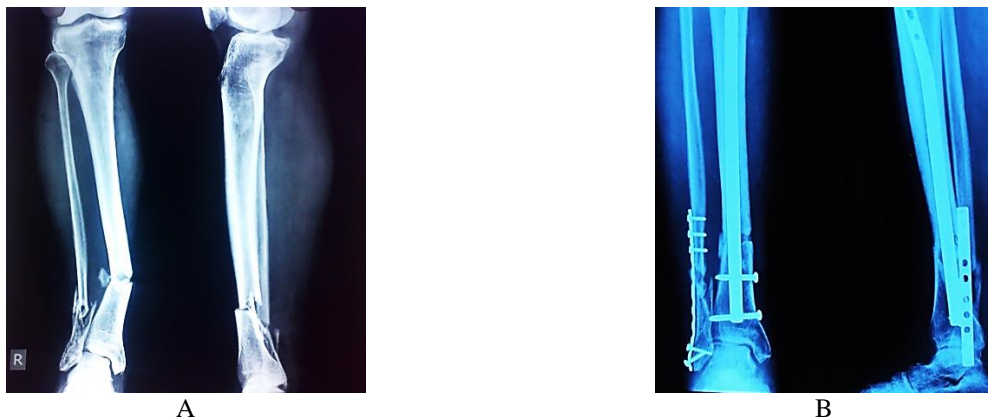
Re-operations excluding dynamization procedures was done in 8 cases (11.11%). Dynamization was done in 4 cases. Bone grafts were used in 3 cases. Bone marrow infiltration and fibular osteotomy were done in 2 cases to promote healing. One patient required exchange nailing with a larger diameter nail for secondary malignment. In 2 other primary malalignment cases (>5deg) a revision surgery with a distal tibial locking plate was undertaken. One case with deep infection required ETN removal and ring fixator application. The other case of deep infection subsided with fibular plate removal and antibiotic beads insertion.



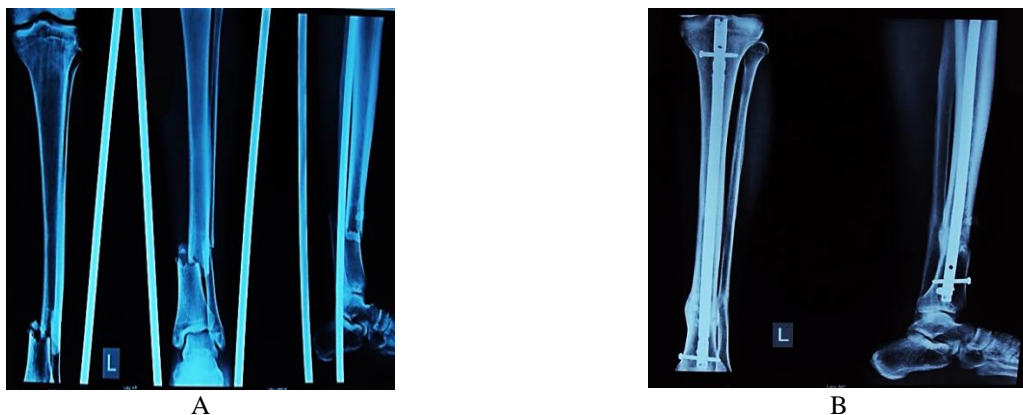
**Fig. 1: Regular interlocking nail having a single plane medio-lateral locking, Herzog's bend at a lower level and distal locking holes may coincide with the fracture site (arrow marks)**



**Fig. 2:** Expert Tibia Nail with optimum Herzog's bend (A), multiplanar locking options and locking option at the tip of the nail (B, C)



**Fig. 3:** a) Pre operative X-Ray showing lower third fracture both bones right leg with a valgus angulation. b) 4wks post-operative X-Ray showing internally fixed fibula fracture and a well aligned tibial fracture fixed with an ETN



**Fig. 4:** a) Pre operative X-Ray showing isolated fracture lower third tibia. b) 12 wks post-operative X-Ray showing united tibial fracture without any malalignment internally fixed with an ETN

## Discussion

Distal tibial metaphyseal fractures are as a result of axial and rotational force. Court-Brown et al found that 37.8% of the tibial fractures were located in the distal third of the tibia.<sup>(18)</sup> The major challenge posed in this region is due to the particular local anatomic characteristics, high degree of comminution, soft tissue trauma all contribute. The regular interlocking nails have the shortcoming of Single plane medio-lateral locking in majority of the nails, Herzog's bend is at a lower level in most of the commercially available nails, distal locking holes are not situated at the tip of the nail, coincide with the fracture site (Fig. 1). Several authors tried a few improvisations to nail these fractures. Pascarella R et al used of cut/sawed nails to facilitate the distal locking screw cross the fracture site in distal tibial fractures.<sup>(19)</sup> Use of poller screws to prevent nail translation in distal tibial fractures was advocated by Ricci WM et al.<sup>(20)</sup>

The expert tibia nail have multiplanar locking options with locking option at the tip of nail, provides angular stability, has provision for compression, can be used as reamed/unreamed and has an optimum Herzog's bend (Fig. 2). All these features make ETN an ideal implant for the tibial metaphyseal fractures, especially in of the distal metaphyseal fractures of tibia.

ETN in distal tibial metaphyseal fractures proved to be an efficient implant in our study population. Fracture union was demonstrated in about 90% of the cases within 6 months of surgery and all patients achieved fracture union within 1 year after surgery. The rate of delayed union in our study was 11.11% which is comparable to the other published studies.<sup>(21,22)</sup> The delayed unions were treated with dynamisation alone in one patient, dynamisation with fibular osteotomy in one patient, dynamisation with autologous bone marrow infiltration in 2 patients, 3 patients required bone grafting at the fracture site and in one patient bone grafting with united fibular osteotomy was done to achieve fracture union. The rate of primary and secondary malalignment and the risk of malunion of >5 degrees is very low (5.2%). Markmiller et al. in his study of fractures of the distal tibia treated with intramedullary nail, reported that nearly half of his study population had a malalignment at the fracture site.<sup>(23)</sup> Egol et al. in a similar study reported a lower rate of malalignment of about 10%.<sup>(24)</sup> Rene Attal Et al conducted a study on distal tibial fractures which were treated with ETN and found the rate of malalignment to be very low, of about 5.4%, which is comparable to our study results. In addition, the percentage of reoperations including dynamisation was 12.5% which is better than or comparable to other published reports on intramedullary nailing of distal tibia fractures.<sup>(21,22)</sup>

When the fibula fracture is at the same level as the distal tibia fracture, fixation of the fibula provides additional stability to distal tibia fracture.<sup>(22)</sup> In our study fibula plating was done for all associated fibula

fractures which are within 5cm from the syndesmosis. The literature reports varied results following fixation of the fibula in the distal tibial fractures.<sup>(25-30)</sup> Few authors reported that fixation of fibula does not increase the risk of delayed union of the distal tibial fracture,<sup>(25,26,27)</sup> whereas some others have reported an increased risk of delayed/nonunion of tibia fractures following fixation of the fibula.<sup>(28,29,30)</sup> Rene Attal Et al found eightfold higher risk of delayed union of the tibia fracture after fixation of the fibula.<sup>(22)</sup> In the present study, we did not find any statistically significant risk of delayed union of tibia fractures after fixation of the fibula. Instead, fixation of fibula helps in alignment of the distal tibia fractures and prevent primary and secondary malalignment (Fig. 3, 4).

There were no cases of locking screw breakage in our series of ETN. Rene Attal et al. reported 3.2% locking screw breakage rate in their series of patients treated with ETN,<sup>(22)</sup> whereas, Markmiller Et al. in his study of unreamed tibial nail reported a breakage rate of 14%.<sup>(23)</sup> This is due to the higher fatigue strength and a double lead thread screw design. ETN locking screws also have a larger diameter, higher bending stability and has more strong contact with the bone interface as compared to the locking bolts of regular interlocking tibial nail.<sup>(22)</sup> The main limitation of this study was that we did not compare the efficacy and outcome of the ETN with the other surgical modalities advocated for distal tibia fractures.

## Conclusion

The ETN demonstrated significant benefits in the treatment of distal tibia fractures. It increases the rate of fracture union, reduce the rate and risk of delayed and non-union, prevent knee and ankle stiffness, reduces the risk of primary and secondary malalignment and thus have a very low reoperation rates. The modified locking options are able to provide more planes for screw fixation especially at the distal end of the implant, thereby increasing the stability between the implant and bone fragments.

## References

1. Sebastian Kuhn, Philipp Appelmann, Philip Pairon, Dorothea Mehler, Pol M. Rommens the Retrograde Tibial Nail: Presentation and biomechanical evaluation of a new concept in the treatment of distal tibia fractures Injury, Int. J. Care Injured 45S (2014) S81–S86.
2. Ahmad MA, Sivaraman A, Zia A, Rai A, Patel AD. Percutaneous locking plates for fractures of the distal tibia: our experience and a review of the literature. J Trauma Acute Care Surg 2012;72(February (2)):E81–7.
3. Hazarika S, Chakravarthy J, Cooper J. Minimally invasive locking plate osteosynthesis for fractures of the distal tibia—results in 20 patients. Injury 2006;37(September (9)):877–87.
4. Batten RL, Donaldson LJ, Aldridge MJ (1978) Experience with the AO method in the treatment of 142 cases of fresh fracture of the tibial shaft treated in the UK. Injury 10:108–114.

5. Blachut PA, O'Brien PJ, Meek RN, Broekhuysen HM (1997) Interlocking intramedullary nailing with and without reaming for the treatment of closed fractures of the tibial shaft. A prospective, randomized study. *J Bone Joint Surg Am* 79:640–646.
6. Chiu FY, Lo WH, Chen CM, Chen TH, Huang CK (1996) Unstable closed tibial shaft fractures: a prospective evaluation of surgical treatment. *J Trauma* 40:987–991.
7. Court-Brown CM, Will E, Christie J, McQueen MM (1996) Reamed or unreamed nailing for closed tibial fractures. A prospective study in Tscherne C1 fractures. *J Bone Joint Surg Br* 78:580–583.
8. Freedman EL, Johnson EE (1995) Radiographic analysis of tibial fracture malalignment following intramedullary nailing. *Clin Orthop Relat Res* 315:25–33.
9. Im GI, Tae SK (2005) Distal metaphyseal fractures of tibia: a prospective randomized trial of closed reduction and intramedullary nail versus open reduction and plate and screws fixation. *J Trauma* 59:1219–1223.
10. Robinson CM, McLauchlan GJ, McLean IP, Court-Brown CM (1995) Distal metaphyseal fractures of the tibia with minimal involvement of the ankle. Classification and treatment by locked intramedullary nailing. *J Bone Joint Surg Br* 77:781–787.
11. Hansen M, Mehler D, Hessmann MH, Blum J, Rommens PM (2007) Intramedullary stabilization of extra articular proximal tibial fractures: a biomechanical comparison of intramedullary and extramedullary implants including a new proximal tibia nail (PTN). *J Orthop Trauma* 21:701–709.
12. Hansen M, Mehler D, Voltmer W, Rommens PM (2002). The extraarticular proximal tibial fractures. *Unfallchirurg* 105:858–872
13. Kuhn S, Hansen M, Rommens PM. Extending the indications of intramedullary nailing with the Expert Tibial Nail. *Acta Chir Orthop Traumatol Cech* 2008;75(April (2)):77–87.
14. Müller ME, Nazarian S, Koch P, Schatzker J (1990). The comprehensive classification of fractures of long bones. Springer, Berlin.
15. Gustilo RB, Anderson JT (1976) Prevention of infection in the treatment of one thousand and twenty-five open fractures of long bones: retrospective and prospective analyses. *J Bone Joint Surg Am* 58:453–458.
16. Buehler KC, Green J, Woll TS, Duwelius PJ (1997). A technique for intramedullary nailing of proximal third tibia fractures. *J Orthop Trauma* 11:218–223.
17. Freedman EL, Johnson EE (1995). Radiographic analysis of tibial fracture malalignment following intramedullary nailing. *Clin Orthop Relat Res* 315:25–33.
18. Court-Brown CM, Mc Birnie J. The epidemiology of tibial fractures. *J Bone Joint Surg Br* 1995;77 (May (3)):417–21.
19. Pascarella R et al, *Chir Organi Mov*. 2004 Apr-Jun;89(2).
20. Ricci WM et al, *J Orthop Trauma*. 2001 May;15(4):264–70.
21. Mohammed A, Saravanan R, Zammit J, King R (2008) Intramedullary tibial nailing in distal third tibial fractures: distal locking screws and fracture non-union. *Int Orthop* 32:547–549.
22. Rene Attal et al., A multicentre case series of tibia fractures treated with the Expert Tibia Nail (ETN) *Arch Orthop Trauma Surg* (2012) 132:975–984.
23. Markmiller M, Tjarksen M, Mayr E, Rüter A (2000). The unreamed tibia nail. Multicenter study of the AO/ASIF. Osteosynthesefragen/ Association for the study of internal fixation. *Langenbecks Arch Surg* 385:276–283.
24. Egol KA, Weisz R, Hiebert R, Tejwani NC, Koval KJ, Sanders RW (2006) Does fibular plating improve alignment after intramedullary nailing of distal metaphyseal tibia fractures? *J Orthop Trauma* 20:94–103.
25. Obremskey WT, Medina M (2004) Comparison of intramedullary nailing of distal third tibial shaft fractures: before and after traumatologists. *Orthopedics* 27:1180–1184.
26. Shen WJ, Shen YS (1993) Fibular nonunion after fixation of the tibia in lower leg fractures. *Clin Orthop Relat Res* 287:231–232.
27. Stegemann P, Lorio M, Soriano R, Bone L (1995) Management protocol for unreamed interlocking tibial nails for open tibial fractures. *J Orthop Trauma* 9:117–120.
28. DeLee JC, Heckman JD, Lewis AG (1981) Partial fibulectomy for ununited fractures of the tibia. *J Bone Joint Surg Am* 63:1390–1395.
29. Sorensen KH (1969) Treatment of delayed union and non-union of the tibia by fibular resection. *Acta Orthop Scand* 40:92–104.
30. Vallier HA, Le TT, Bedi A (2008) Radiographic and clinical comparisons of distal tibia shaft fractures (4 to 11 cm proximal to the plafond): plating versus intramedullary nailing. *J Orthop Trauma* 22:307–311.