

A study of clinical and functional outcome of primary total hip replacement in osteoarthritis of hip

Jayaram BS¹, Shivananda S², Gazanfar Patel^{3,*}

¹Associate Professor, ²Professor & HOD, ³Junior Resident, Dept. of Orthopaedics, Kempegowda Institute of Medical Sciences & Research, Bangalore, Karnataka

***Corresponding Author:**

Email: gazanfar8806@gmail.com

Abstract

Introduction and Objectives: Osteoarthritis is the most common disorder associated with severe hip pain and disability in adult population.

Primary total hip replacement (THR) aims for immediate and long lasting effects on pain and function in osteoarthritic hip. The intend of this study was to evaluate the clinical and functional outcome of Primary total hip replacement using Modified Harris hip score.

Materials and Method: A prospective study of 50 hips (38 patients) of osteoarthritis managed by Primary total hip replacement in Kempegowda institute of medical sciences, Bangalore between June 2014 to February 2017. The patients were assessed clinically and functionally using Modified Harris Hip Score pre and post operatively. Patients were followed for a minimum period of 2 years and maximum of 2.5 years.

Results: 50 hips were operated in 38 patients for avascular necrosis (38), primary osteoarthritis (8), Ankylosing spondylitis (2) and Rheumatoid Arthritis (2).

The mean total pre-operative Modified Harris hip score was 30.60 which improved postoperatively to a mean score of 88.90.

We had complications in 8 patients, foot drop (2), superficial infection (2), limb length discrepancy (2), and posterior dislocation (2). We had good to excellent results in 84% and fair results in 12% patients.

Conclusion: Our study suggests that Primary total hip replacement provides excellent clinical and functional outcome in osteoarthritis of hip.

Keywords: Primary Total hip replacement, Modified Harris hip score, Osteoarthritis.

Introduction

A stable, painless and mobile hip is required for normal locomotion. At present the most common condition affecting hip of adult population is osteoarthritis; resulting in severe hip pain, restriction of movements and alteration in day to day activities.⁽¹⁾ Due to rapidly expanding and improving health care management, longevity of individuals has increased over past few decades; which has increased the occurrence of chronic disabling conditions of the hip such as osteoarthritis, inflammatory arthritis.

Primary total hip replacement (THR) has enhanced the quality of life by improving enormously the immediate and long lasting outcomes in terms of pain and function in osteoarthritic hip.⁽²⁾ The functional improvement in terms of gait and range of movement has been reported in many studies.^(3,4) Currently Total hip arthroplasty is most commonly performed joint replacement procedure and the need for total hip arthroplasty (THA) is expected to increase exponentially in future.^(5,6,7)

For a successful Total hip arthroplasty, the prosthesis must be fixed firmly to the bone, either with polymethylmethacrylate (PMMA) cement or by bony ingrowth into a porous coating on the implant, resulting in "biologic" fixation.

In the history, the first recorded primary THR was done by Phillip Wiles from London in 1938.⁽⁸⁾ The operative technique was further studied and evolved in 1950s by McKee and Farrar. By using the biomechanical principles of human hip joint function and by introduction of low friction arthroplasty Sir John Charnley revolutionized the procedure of THR⁽⁹⁾ and hence considered as the father of modern total hip arthroplasty.⁽¹⁰⁾

Harris Hip Score is reliable tool to measure the clinical and functional outcome of THR which assesses pain, functional disabilities, deformities and range of movement pre-and postoperatively.⁽¹¹⁾

This is a consecutive study of 38 patients (50 hips) with osteoarthritis (unilateral or bilateral) assessed clinically and functionally preoperatively and post operatively following Primary total hip replacement using Modified Harris Hip Score.

Materials and Method

Source of data: This study was carried out on 50 hips of 38 patients who have undergone primary total hip replacement during June 2014 to February 2017 in The Department of Orthopaedics, Kempegowda institute of medical science, Bangalore.

Sampling Procedure

Study design: Prospective study.

Sample design: Purposive sampling.

Study place: KIMS hospital, Bangalore

Sample size: 50 hips

Inclusion criteria:

1. Primary osteoarthritis of hip
2. Secondary osteoarthritis of hip due to
 - Avascular necrosis
 - Ankylosing spondylitis
 - Rheumatoid arthritis.

Exclusion criteria:

1. Age below 40 years
2. Active infection of hip joint
3. Failed hip surgeries (AMP, Bipolar, osteotomy, DHS, PFN)
4. Bone tumors involving proximal femur and acetabulum
5. Neuropathic hip joint.

Clinical Assessment: Detailed history of all patients was taken. Clinical and functional assessment of all the patients was done using Modified Harris Hip Score. The hip deformities were examined for any fixed adduction or flexion contracture.

Radiographic Assessment: As per standard guidelines radiological examination was carried out in all patients. Templating was done for the acetabular and femur components. The appropriate acetabular cup size (AP view), and ante version (lateral view) was determined. On the femoral side, using a template, appropriate neck length, offset and stem size of the implant was chosen.

Pre-operative protocol: The patients were admitted 2 days before surgery. Patients were educated about preoperative physiotherapy, (like quadriceps and hamstring exercises) and the postoperative rehabilitation program. Preoperative medical evaluation was done for all the patients.

Patients were advised to take bath with betadine and water from two days prior to surgery. As per standard protocol prophylactic injectable antibiotics were started on all patients from 12 hours prior to surgery and continued till 3 days postoperatively and switched to oral antibiotic till the time of suture removal. All the required standard aseptic precautions were taken with regards to instrumentation and operation theatre.

Operative procedure:

Anesthesia: Spinal Anesthesia.

Approach: Posterolateral Approach(Gibson's).

Position: True lateral with the affected limb uppermost

A 10-15 cm curved incision, just anterior to greater trochanter was taken. The subcutaneous tissue and fascia lata dissected. The Gluteus maximus fibers are split bluntly. Internally rotate the hip to put the short external rotator muscles on a stretch and detach the tendons close to their femoral insertion to expose the capsule. The capsule was incised with a T-shaped incision. The knee was flexed to 90° and the thigh was internally rotated. The head was then delivered

posteriorly out of the acetabulum using bone levers and head extractor.

Implantation of Acetabular Component: Acetabulum is cleared of all soft tissues. Osteophytes projecting from the margins of the acetabulum are removed. Reaming of the floor of acetabulum is done with the help of basket reamers oriented to the acetabulum at approx. 45° of abduction and 15° of ante version. Progressive reaming was done at 2 mm intervals till a healthy bleeding of the subchondral bone is reached and a hemispherical dome was achieved. U A 1– 2 mm smaller size to the final reamer-trial cup is introduced into the acetabulum with help of cup introducer and assessed for its position and cortical bone contact. The inferior rim of trial cuff should be level with the bottom of tear drop and should be oriented at 45 degree to the lateral opening and 15 degree of ante version. The trial cup was removed, the acetabulum is washed with pulsatile lavage with cold normal saline and dry gauze was packed into the acetabulum. Acetabular cup is fixed to reamed acetabulum at 45° to the lateral opening and 15° of ante version with two cancellous screws in posterosuperior quadrant.

Implantation of femoral component: Hip was internally rotated, flexed, and adducted until tibia was vertical and axis of knee joint is horizontal. Femoral neck now points downward 15° to 20°, Femoral canal was assessed at the piriformis fossa with a box osteotome. Canal was initially reamed with a straight reamer and then progressively increasing sizes of rasp are introduced till a tight fit is achieved. Rough idea was gained with the help of preoperative templating. Trial reduction was done with a trial head to check for stability, range of movement and muscular tension. Trial component was then removed. Lateral femoral cortex reamed in the upper part of canal to avoid a Varus positioning. After progressive femoral broaching, selected porous coated femoral stem fitted with a centralizer was introduced into the reamed canal maintaining the necessary ante version. Selected head size was then placed over the neck of the stem and impacted with an impactor. Reduction was achieved and stability of the reduction checked. Wound was then closed in layers over negative suction drain.

Post-operative protocol: A 15 degree of abduction was maintained for initial 12 hours of postoperative period by using triangular pillow. Suction drain was removed at the end of 24 hours postoperatively. Check x-ray was taken on 2nd post-operative day. After the check x-ray patient was made to sit and quadriceps exercises, knee and ankle mobilization exercises were started weight bearing mobilization with walker support was started on 3rd post-operative day. IV antibiotics were given for 3 days and later switched over to oral antibiotics till suture removal. Low molecular weight heparin was given for first five days after surgery. Aspirin with mechanical methods of DVT prophylaxis was given for one month. Sutures were removed on 12th to 14th

postoperative day (as per wound condition) and patient was discharged from the hospital and reviewed after 4 weeks.

Follow Up: The patients were followed up at 6 weeks, 12 weeks, 24 weeks, 1 year, 1.5 year, 2 year.

During each visit, physical examination was done. Clinico-radiological evaluation was done and the clinical and functional outcomes were calculated by Modified Harris Hip Score.

Statistical Methods: This was a hospital based Prospective, observational study. Data collected was tabulated in Microsoft excel and analyzed using SPSS 16.0. Microsoft word was used to generate graphs/chart and tables.

The student t-test for paired comparisons was used to compare means of Pre and post-operative Modified Harris Hip Score and the P value was determined.

Results

Table 1: Age Distribution

Age distribution of the patients who underwent Total Hip Replacement, N=50

Age(in years)	Frequency	Percentage
41 to 45	24	48
46 to 50	8	16
51 to 55	8	16
56 to 60	2	4
61 to 65	8	16
Total	50	100

The maximum number of the patients were from the age group of 41-45 years which accounts for 48% of patients in our study. The youngest patient was 41 years of age and the oldest patient was 65 years. The mean age was 49.2 years

Table 2: Gender Distribution

Gender distribution of the patients who underwent Total Hip Replacement, N=50

Gender	Frequency	Percentage
Male	34	68
Female	16	32
Total	50	100

There was a male predominance in our study accounting for 68% of the patients.

Table 3: Indication for Surgery

Indication for surgery among the patients who underwent Total Hip Replacement, N=50

Indication	Frequency	Percentage
AVN	39	76
Primary Osteoarthritis	8	16
Ankylosing spondylitis	2	4
Rheumatoid arthritis	2	4
Total	50	100

There was a predominance of Avascular necrosis as an indication for surgery in our study, accounting for 76% of the patient.

Table 4: Complications

Complications following Total Hip Replacement, N=50

Complication	Frequency	Percentage
No complication	42	84
Limb length discrepancy	2	4
Foot drop	2	4
Superficial infection	2	4
Dislocation	2	4
Total	25	100

Limb lengthening was managed by giving shoe raise to contralateral limb in both the cases; one patient recovered from foot drop after 8 months of surgery; patients with superficial infection at surgical site were taken to operating room debridement and resuturing was done and wound healed in 2 weeks with i.v. antibiotics; in cases of dislocations, closed reduction was achieved under G.A. in both patients.

Table 5: Modified harris hip score

Status	Mean	Median	Range
Pre op	30.6	30 (21-38)	14-50
Post op	88.9	94 (87-96)	59-98

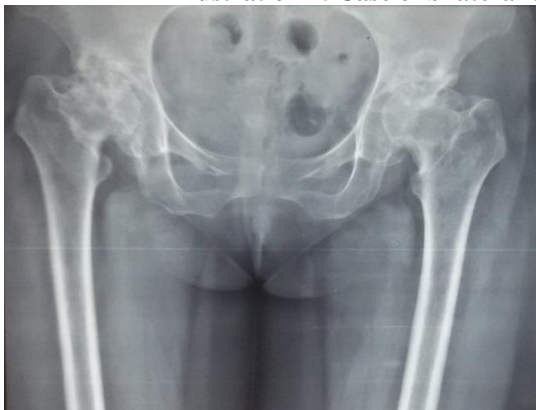The improvement in Modified Harris Hip score was from 30.6 to 88.8 at the end of 2 years.

Table 6: Grading of modified harris hip score

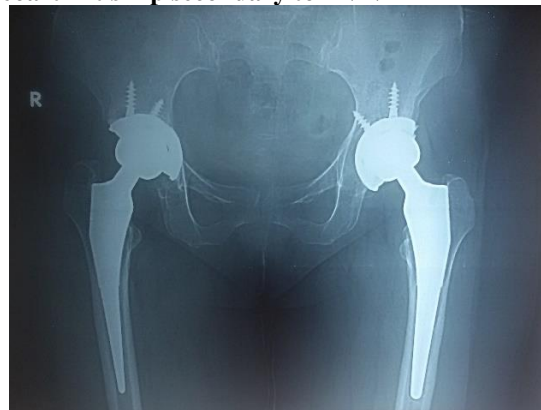
Grading	Frequency	Percentage
Excellent	32	64
Good	10	20
Fair	6	12
Poor	2	4
Total	50	100

We achieved excellent to good outcome in 84% patients.

Illustration 1: Case of bilateral osteoarthritis hip secondary to AVN

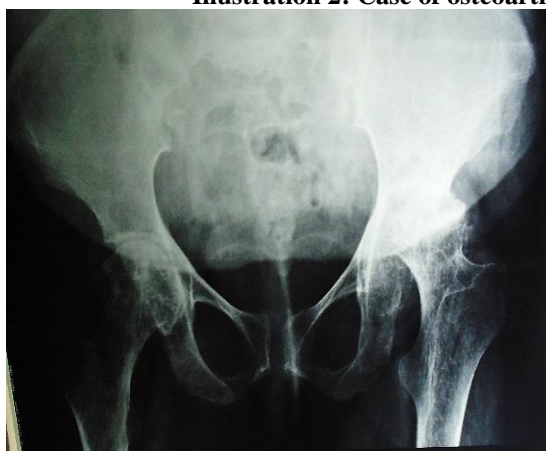

Preoperative x-ray

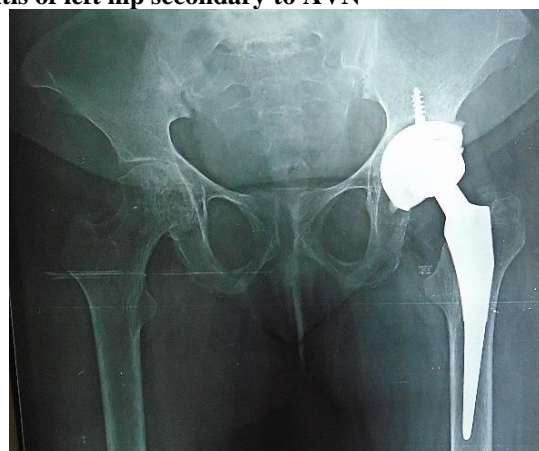


postoperative x-ray – at 2 year followup

Illustration 2: Case of osteoarthritis of left hip secondary to AVN

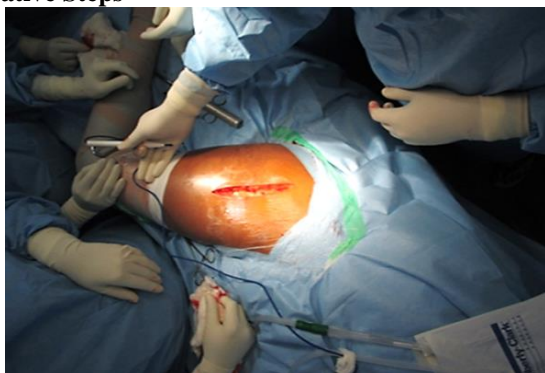

Preoperative X-ray

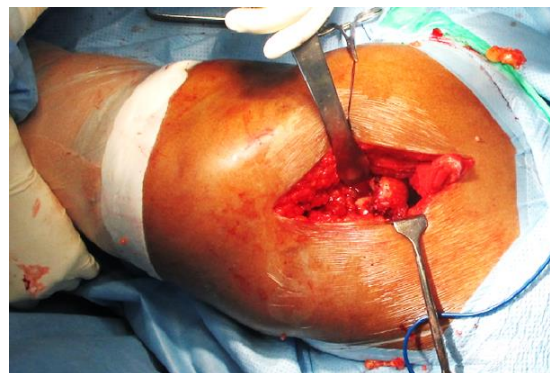


Postoperative X-ray- at 2 year follow up

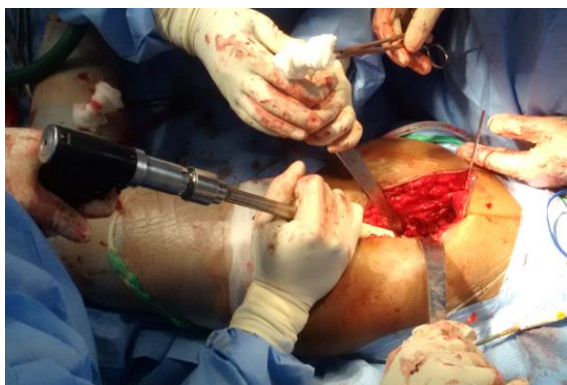Operative Steps



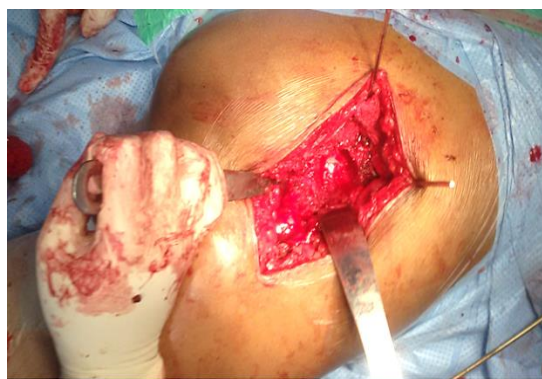Incision



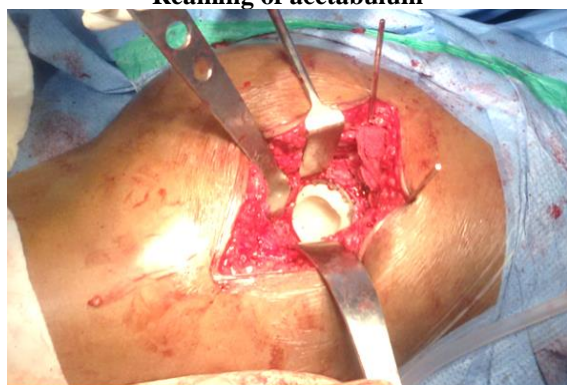Delivery of head



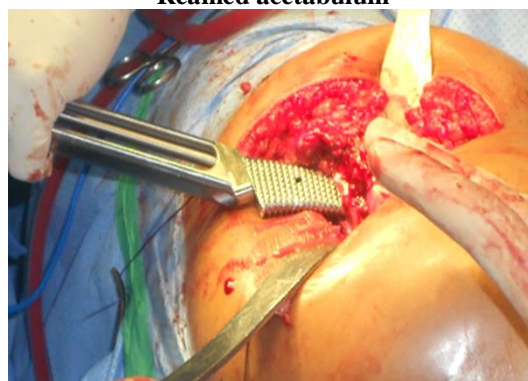Reaming of acetabulum



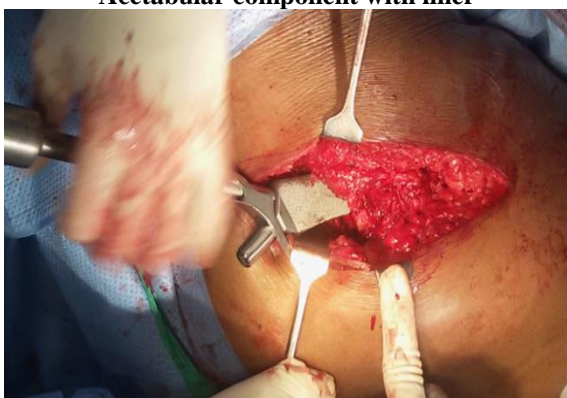Reamed acetabulum



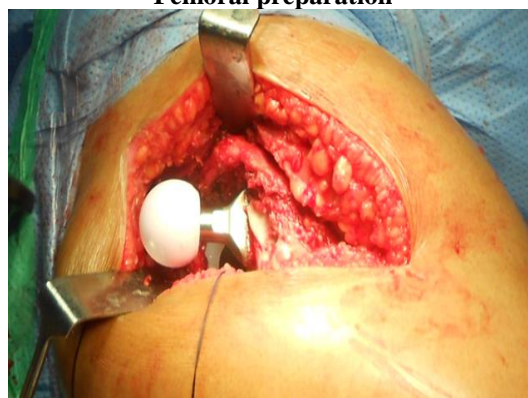Acetabular component with liner



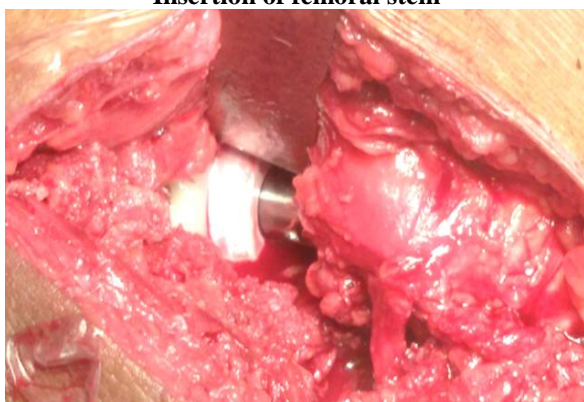
Femoral preparation



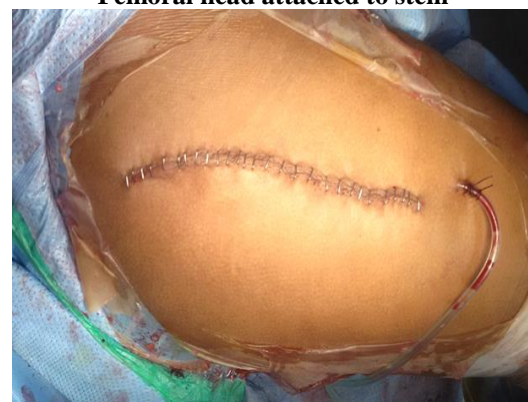Insertion of femoral stem



Femoral head attached to stem



Reduced hip joint



Wound closure

Discussion

We studied 50 hips of 38 patients, (26 unilateral and 12 bilateral) who underwent primary Total hip replacement, the majority of the patients were from the age group of 41-45 years (48%). The mean age was 49.2 year. There was a male predominance (68%) noted; BK Dhaon et al⁽¹²⁾ they treated 47 hips in 34 patients (21 unilateral and 13 bilateral) with average age of 32.6 and male to female ratio of 3:1; RC Siwach et al⁽¹³⁾ studied 100 patients with mean age of 52 of which 52 were male and 48 were female.

In our study most common indication for surgery was avascular necrosis of femoral head i.e. in 38 hips (76%), other indications for surgery were primary osteoarthritis (8 hips), ankylosing spondylitis (2 hips), rheumatoid arthritis (2 hips); Rajendra Nath et al⁽¹⁴⁾ operated 31 hips of which 15 were avascular necrosis of femoral head, 5 were rheumatoid arthritis and 5 were seronegative spondyloarthropathies, RC Siwach⁽¹³⁾ et al studied 26 cases of AVN, 16 cases of primary O.A. and 6 cases of ankylosing spondylitis

In our study the clinical and functional outcome was assessed by using Modified Harris hip score. Mean Modified Harris hip score improved from 30.6 to 88.9.

Comparison of Mean Modified Harris hip score with other studies.

Study	Pre-op HHS	Post-op HHS
Our study	30.6 (14-50)	88.9 (59-98)
RC Siwach et al ⁽¹³⁾	44 (30-50)	83.5 (60-96)
BK Dhaon et al ⁽¹²⁾	36.6 (16-56)	89 (52-95)
Goldberg et al ⁽¹⁵⁾	37 (15-55)	92 (65-100)
Rajendra Nath ⁽¹⁴⁾	29.2 (16-50)	79.9 (49-98)

In our study, preoperatively 75% of patients had marked pain and 25% had moderate pain. Post-operatively maximum number of patient i.e. 85% patients were pain free. Similar result was obtained by RC Siwach et al⁽¹³⁾ (84% complete pain relief); Cupic and Zoran et al⁽¹⁶⁾ (91.3% complete pain relief).

In our study following THR 75% patient had good range of movement, 20% patient had mild restriction.

Similarly, RC Siwach et al⁽¹³⁾ reported 80% had good range of movement 16% had mild restriction of movement. Cupic and Zoran⁽¹⁶⁾ reported 78.7% had good, 18.3% mild restriction in movement.

In our study following THR 70% patients had no limp and 30% patients had mild to moderate limp.

Similarly, RC Siwach et al⁽¹³⁾ reported no limp in 75% patients and mild to moderate limp in 25% patients following THR.

In our study 84% of patients had no post-operative complications. 8 patients (16%) had post-operative complications. 2 superficial infection, 2 foot drop, 2 posterior dislocation, 2 limb length discrepancy

(lengthening of > 1 inch). Goldberg et al⁽¹⁵⁾ reported 3 dislocations, 1 deep infection and 3 deep vein thrombosis. RC Siwach et al⁽¹³⁾ reported 5 dislocations, 4 superficial and 1 deep infection, 1 foot drop and 1 limb length discrepancy (shortening >1 inch).

In our study we achieved excellent to good outcome in 84% patients, fair in 12% patients and poor in 4% patients. BK Dhaon et al⁽¹²⁾ reported excellent to good outcome in 87.2% patients; RC Siwach et al⁽¹³⁾ mentioned excellent to good outcome in 75% patients.

Conclusion

Primary total hip arthroplasty improves the functional ability of patient in terms of gait and range of movement. It provides pain free, stable and mobile hip joint. And this procedure has tremendously improved the quality of life of patients crippled with chronic arthritis.

The Modified Harris Hip Score is an effective scoring system as it incorporates clinical and functional outcome following Total Hip Arthroplasty.

Reference

1. F. Guillemin, A.C. Rat, B. Mazieres, J. Pouchot, B. Fautrel, L. Euller-Ziegler, Fardellone, J. Morvan, C.H. Roux, E. Verrouil, A. Saraux, J. Coste. Prevalence of symptomatic hip and knee osteoarthritis: a two-phase population-based survey
2. Odri GA, Padiolleau GB, Gouin FT. Oversized cups as a major risk factor of postoperative pain after total hip arthroplasty. *J Arthroplasty*. 2014 Apr;29(4):753-6.
3. Hodt-Billington C, Helbostad JL, Vervaat W, et al. Changes in gait symmetry, gait velocity and self-reported function following total hip replacement. *J Rehabil Med*;43-9:787.
4. Vissers MM, Bussmann JB, de Groot IB, et al. Walking and chair rising performed in the daily life situation before and after total hip arthroplasty. *Osteoarthritis Cartilage*;19-9:1102.
5. Nho SJ, Kymes SM, Callaghan JJ, Felson DT. The burden of hip osteoarthritis in the United States: epidemiologic and economic considerations. *J Am Acad Orthop Surg*. 2013;21 Suppl 1:S1-6.
6. Jeffrey N Katz. Total joint replacement in osteoarthritis. *Best Practice & Research Clinical Rheumatology* Vol. 20, No. 1, pp. 145-153, 2006.
7. Stephen Richard Knight, Randeep Aujla, Satya Prasad Biswas. Total Hip Arthroplasty - over 100 years of operative history. *Orthopedic Reviews* 2011; volume 3:e16.
8. Wiles P. The surgery of the osteo-arthritis hip. *Br J Surg* 1958;45:488-497.
9. Reynolds L A, Tansey E M. (eds) Early Development of Total Hip Replacement. Wellcome Witnesses to Twentieth Century Medicine, (2007) vol. 29. London.
10. Turek's orthopaedics principles and their applications 7th edition. Pg no 1069.
11. Harris WH. Traumatic arthritis of the hip after dislocation and acetabular fractures: treatment by mold arthroplasty. An end-result study using a new method of result evaluation. *J Bone Joint Surg Am*. 1969 Jun;51(4):737-55.
12. BK Dhaon, Anuj Jaiswal, Vishal Nigam, Vineet Jain. Non-cemented total hip replacement in various disorders

- of the hip. Year: 2005 Volume: 39 Issue: 4 Page: 225-227.
13. RC Siwach, Virender Singh Kadyan, SS Sangwan, Rajiv Gupta. A retrospective study of total hip arthroplasty Year: 2007 Volume: 41 Issue: 1 Page: 62-66.
 14. Rajendra Nath, Anil Kumar Gupta, Unmesh Chakravarty, Rohit Nath. Primary cemented total hip arthroplasty: 10 years follow-up. Year: 2010 Volume: 44 Issue: 3 Page: 283-288.
 15. Victor M. Goldberg et al Hybrid total hip arthroplasty: a 7- to 11-year followup. Clin Orthop Relat Res. 1996 Dec;(333):147-54.
 16. Zoran Cupic. M.d. Long-term Follow-up of Charnley Arthroplasty of the Hip Clinical Orthopaedics and Related Research June 1979, Number 141.