

## Anterior cervical discectomy and fusion in degenerative disc disease of the cervical spine: a retrospective outcome analysis of 30 patients

Balaji Douraiswami<sup>1,\*</sup>, Suresh Subramani<sup>2</sup>, Vijay Anand Balasubramanian<sup>3</sup>

<sup>1,3</sup>Associate Professor, <sup>2</sup>Assistant Professor, Dept. of Orthopaedics Surgery, SRM Medical College & Research Centre, Tamil Nadu

**\*Corresponding Author:**

Email: balajidouraiswami@gmail.com

### Abstract

**Introduction:** Degenerative Disc Disease of the cervical spine produces significant morbidity in middle aged individuals. Failure of conservative treatment necessitates removal of intervertebral disc and fusion. Autogenous Bone grafting improves the rate of fusion. This study aims to evaluate the functional outcome and fusion in 30 patients after Anterior Cervical Discectomy and Fusion (ACDF).

**Materials and Method:** Thirty patients with cervical radiculopathy who failed conservative treatment and underwent anterior cervical discectomy and fusion using autograft from iliac crest were assessed. The parameters evaluated to assess the functional outcome include: Cervical lordosis, intervertebral disc height, fusion status, Odoms criteria, Japanese Orthopedic Association (JOA) score and Visual Analog Pain scores. Statistical analysis was done with student's t test, pearson correlation coefficient and linear regression analysis.

**Results:** The mean improvement in disc height was 3mm and cervical lordosis was 3 degrees. All patients had significant improvement in VAS score and JOA score. Odom's criteria showed excellent to good results in all patients. There were no donor site complications. The mean period to bony fusion was 7.067 months and fusion was seen in 93.33% of cases.

**Conclusion:** ACDF with bone grafting and plating gives excellent results in cervical degenerative disease. The fusion rates are better with autograft albeit the negligible donor site morbidity.

**Keywords:** Anterior Cervical Discectomy and Fusion; Autograft; Degenerative Disc Disease

### Introduction

The degenerative changes associated with ageing in the cervical spine include disc herniation, osteophyte formation, hypertrophy of osteoarthritic facet joints, and hypertrophy of ligaments. In 10% to 15% of cases, this compresses the cervical spinal cord and roots to present symptomatically as myelopathy or radiculopathy. When symptoms do not respond to conservative treatment, surgical treatment is contemplated. The goals being to decompress the nerves, restore the sagittal alignment of the vertebrae and to stabilize the spine. Anterior Cervical Discectomy and Fusion (ACDF) has its inherent advantages viz., 1) lesser morbidity compared to laminectomy by posterior approach, 2) directly removes disc pathology without disturbing the spinal cord. Anterior Cervical discectomy and fusion has given good clinical results for both radiculopathy and spondylotic myelopathy of the cervical spine. The short-term clinical results show a good outcome in 70% to 90% of cases. Plating gives additional advantages such as initial stability of fixation, early mobilization of patient and reduction in the period of bracing. It prevents bone graft collapse or extrusion, improves bony fusion and maintains sagittal alignment. The purpose of this study is to assess the clinical and radiological outcome of operative treatment of cervical degenerative disease, in particular the pain relief following the surgery and to evaluate the fusion rates using autogenous iliac crest graft.

### Materials and Method

Ours is a retrospective study of 30 patients with degenerative disc disease of the cervical spine treated with anterior cervical discectomy and fusion. The period of study was from 2012 to 2015.

#### Inclusion Criteria

1. Persistent severe radicular pain not responding to conservative management for 6 weeks
2. Cervical degenerative disc disease with progressive paresis

#### Exclusion Criteria

1. Cervical trauma
2. Cervical neoplasia
3. Cervical infection

Patients with symptomatology were carefully evaluated clinically with thorough neurological examination. MRI of the cervical spine was then taken to assess and document the compression of the cervical nerve roots or spinal cord, which most likely explained the clinical symptoms and signs. The patients were worked up for surgery with proper written informed consent for surgery. The study conforms to the Declaration of Helsinki and was approved by the Institutional Ethical Review Board.

**Surgical Procedure:** In all patients, the anterior approach described by Robinson and Smith was used. We used the left sided approach for reasons relating to the recurrent laryngeal nerve anatomy. Self retaining

retractors were placed after confirming the levels of interest using fluoroscopy. In all patients, magnification in the form of loupes were used to visualise the deeper structures. High speed burr was used to remove the anterior osteophytes and the disc material. In all cases the posterior longitudinal ligament was taken down and the final decompression of the nerve roots were done using Kerrison rongeurs. The size of the defect following the disc excision was measured using callipers. Tricortical grafts were harvested from the iliac crest measuring the exact size of the defect and placed at the disc space to fit snugly. Fixation was done using locking plates with 2 screws in each vertebra above and below in converging configuration. Wound was irrigated and closed in layers. Antibiotics were given for 48 hours following the surgical procedure. Patients were mobilized within 24 hours of the surgery. A stiff collar was given for comfort. All patients were followed up at 6 weeks, 3 months and 6 months with clinical examination and radiographs. Pain relief, range of motion of the cervical spine, improvement of neurology, radiologic change of lordosis and fusion were all assessed.

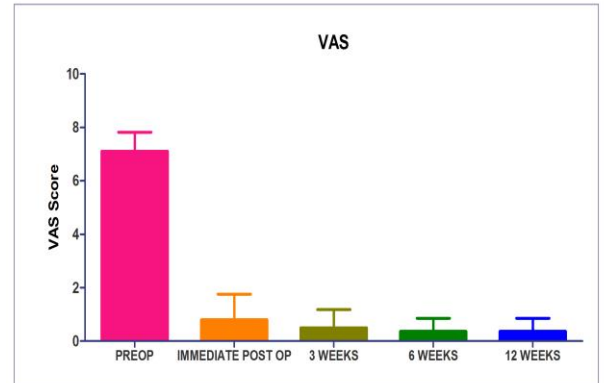
**Statistical Analysis:** The variables were analysed using the linear regression analysis in an exploratory fashion. Standard paired t-test was used to analyse the Visual Analog Scale variables.

There is no source of funding obtained for this study.

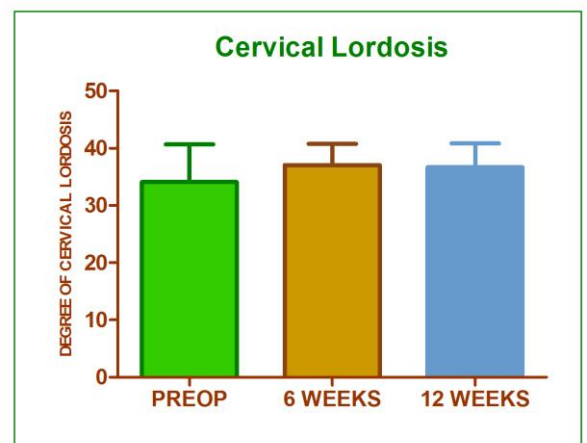
## Results

30 patients of mean age 45.07 years (6 females and 24 males) who underwent single level anterior cervical discectomy and fusion with autograft and plating were included in the study. Out of them 6 (20%) were females and 24(80%) were males. The most common level of surgery was C5/C6 (70%) followed by C4/C5 (20%). The mean followup period of study was 32.5 months (range 24 - 46 months). The mean Visual Analogue Score (VAS) for neck and arm pain decreased considerably from a preoperative value of 7.1 to 1.8 postoperatively with a further drop to 1.3 at final followup (Fig. 1). The preoperative mean lordosis angle of the cervical spine and the mean disc height were 34.10 degrees and 4.4mm respectively, which after surgery, improved to 37.07 degrees and 7.3mm. At final followup, the mean lordosis angle was 36.67 degrees and the disc height 7.1 mm (Fig. 2). The mean preoperative and last followup JOA scores showed a significant improvement from 7.9 to 14.8 points ( $p < 0.001$ ). The functional outcome assessed by Odom's criteria at the time of last followup showed excellent results in 17 (56%) patients and good in 13 (44%) patients (Fig. 3). The mean period to bony fusion was 7.067 months (SD - 3.095). There were 2 cases of non union. None of the patients had new neurological deficit postoperatively. The post operative

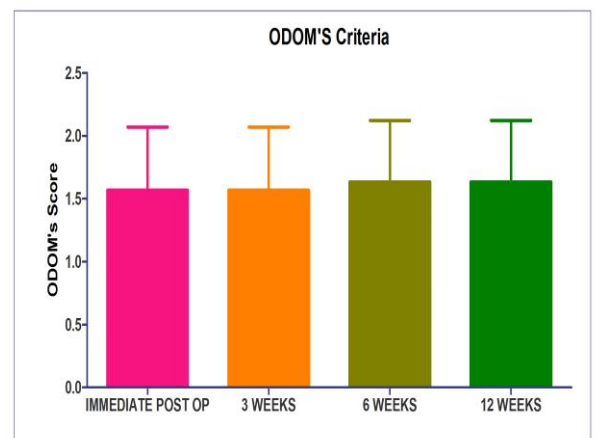
complications seen were dysphagia in one patient and Horner's syndrome in another. They both resolved over time. Donor site morbidity was limited to one patient who had infection at that site which subsided with dressings and appropriate antibiotics.



**Fig. 1: Bar chart comparing the mean preoperative and post operative Visual Analog Scores (VAS)**



**Fig. 2: Bar chart depicting the increase in the cervical lordosis post surgery**



**Fig. 3: Bar chart illustrating the post operative ODOM's criteria scores**

## Discussion

Cervical disc degeneration can lead to a spectrum of problems from axial neck pain to cervical radiculopathy and myelopathy. Most patients respond to conservative treatment. Surgery is indicated in recalcitrant cases. Surgical intervention, however, can lead to rapid relief of symptoms of cervical radiculopathy compared to conservative measures alone.<sup>(1,2)</sup> Anterior Cervical Discectomy and Fusion (ACDF) is suggested for the treatment of single-level degenerative cervical compressive lesions medioventral to the nerve root.<sup>(3)</sup> The first description of Anterior cervical approach was by Lahey and Warren to expose esophageal diverticula.<sup>(4)</sup> Anterior cervical discectomy and fusion (ACDF) is considered a relatively safe procedure with low morbidity and low mortality.<sup>(5)</sup> Complications like dysphagia reported in literature range from 2.5-21.3%, with a mean of 12.3%.<sup>(8,9)</sup> Decompression is often accomplished via an anterior approach whereby essentially the entire disc as well as any bony osteophytes and ligaments that are compressing the spinal cord and/or nerves are removed. While usually successful at decompressing affected neural structures, the decompression often results in collapse of the disc space, instability and recurrent symptomatology. Most anterior cervical decompressions are therefore followed by insertion of a structural interbody spacer such as an autograft, allograft, or a synthetic spacer filled with a bone graft. The ideal graft should have all potentials of osteogenesis, osteoinduction and osteoconduction, and currently the only graft that fulfils all of three properties is autologous bone graft.<sup>(10)</sup>

A meta-analysis by Floyd et al., for one and two-level stand-alone ACDF comparing autograft and allograft showed a higher fusion rate for autograft for both single level and multi-level ACDF cases at 12 months. Allograft ACDFs were found to have delayed time to fusion.<sup>(11)</sup> Although allograft has advantages over autograft in terms of donor site morbidity and surgical time, it is expensive and outcomes of fusion rate, maintenance of disc height and lordosis are worse than autograft, not to mention the risk of infection and graft rejection, higher rates of collapse and nonunion, especially in multilevel fusions, and prolonged period required for graft incorporation.<sup>(12)</sup>

According to Zulkefli et al. the union rate at 6-month follow-up was 95% in patients who received autogenous bone graft, and 62.1% in patients who received a hydroxyapatite cage.<sup>(13)</sup> In a comparative study by Jae Sung Ahn et al., they found the mean period of union was prolonged by approximately 33 weeks in patients who received a cage compared to patients who had undergone fusion with autograft.<sup>(14)</sup> The rate of fusion following single-level ACDF generally ranges from 80% to 95%. The union rate in

our study compares favourably with the literature; 93.33%, also the mean period of bony fusion (7.067 months); but the sample size of our study group is too small to draw a logical comparison. Also the comparison is made with the literature as there wasn't a separate cohort of subjects in whom the alternative like allograft or substitutes were used.

Postoperative loss of lordosis and cervical kyphosis have been associated with ACD and ACDF without plating. Anterior cervical plate fixation for degenerative disc disease maintains sagittal balance more effectively.<sup>(15,16)</sup> In our study, there was no significant loss of lordosis at the final followup, albeit the increase in lordosis by a mean of 3.57degree postoperatively. With an average follow-up period of 18 months, Kwon et al. demonstrated clinical improvement rates of 96.1% and 82.1% for neck and arm pain, based on VAS.<sup>(17)</sup> A statistically significant decrease for VAS, both for neck and arm pain, was achieved for the study population in Park et al.'s series<sup>(18)</sup> at mean follow up of 12 months. In the current study, the VAS of neck and arm pain have improved significantly by 95.1% and 80% compared to the preoperative scores ( $p < 0.05$ ). JOA scores improved from 7.9 to 14.8 points. Overall clinical outcome was excellent or good in all patients. Only one patient (3.33%) had infection in the donor site for bone graft. Pearson's correlation coefficient showed significant correlation between the cervical lordosis angle, VAS scores, and the functional improvement by Odom's criteria.

To conclude, anterior cervical discectomy and fusion with plating and autogenous bone grafting gives excellent clinical results in patients with cervical degenerative disc disease. We feel it is the gold standard procedure to obtain bony fusion even now with the advent of allograft, bone graft substitutes.

## Conflicts of Interest

None of the authors has any conflicts of interest and no grants were obtained for the conductance of this study.

## References

1. L. C. G. Persson, U. Moritz, L. Brandt, and C. A. Carlsson. Cervical radiculopathy: pain, muscle weakness and sensory loss in patients with cervical radiculopathy treated with surgery, physiotherapy or cervical collar: a prospective, controlled study. *European Spine Journal* 1997;6:4:256-266.
2. P. Sampath, M. Bendebeba, J. D. Davis, and T. Ducker. Outcome in patients with cervical radiculopathy prospective, multicenter study with independent clinical review. *Spine* 1999;24:6:591-597.
3. C. M. Bono, G. Ghiselli, T. J. Gilbert et al. An evidence-based clinical guideline for the diagnosis and treatment of cervical radiculopathy from degenerative disorders. *Spine Journal* 2011;11:1:64-72.
4. Cloward RB. The anterior approach for removal of ruptured cervical disks. *J Neurosurg* 1958;15:602-17.

5. Lahey FH, Warren KW. Esophageal diverticula. *Surg Gynecol Obstet* 1954;98:1-28.
6. Papavero L, Heese O, Klotz-Regener V, Buchalla R, Schroder F, Westphal M. The impact of esophagus retraction on early dysphagia after anterior cervical surgery: does a correlation exist? *Spine* 2007;32:1089-1093.
7. Gaudinez RF, English GM, Gebhard JS, Brugman JL, Donaldson DH, Brown CW. Esophageal Perforations after anterior cervical surgery. *J Spinal Disord* 2000;13:77-84.
8. R. Bazaz, M. J. Lee, and J. U. Yoo. Incidence of dysphagia after anterior cervical spine surgery: a prospective study. *Spine* 2002; 27:22:2453-2458.
9. M. J. Lee, R. Bazaz, C. G. Furey, and J. Yoo. Risk factors for dysphagia after anterior cervical spine surgery: a two-year prospective cohort study. *The Spine Journal* 2007;7;2:141-147.
10. Kyung-Jin Song<sup>1</sup>, Byeong-Yeol Choi<sup>2</sup>. Current Concepts of Anterior Cervical Discectomy and Fusion: A Review of Literature. *Asian Spine J* 2014;8(4):531-539.
11. Floyd T, Ohnmeiss D. A meta-analysis of autograft versus allograft in anterior cervical fusion. *Euro Spine J Off Publ Euro Spine Soc Euro Spinal Deform Soc Euro Sect Cerv Spine Res Soc* 2000;9:398-403.
12. Delloye C, Cornu O, Druetz V, Barbier O. Bone allografts: What they can offer and what they cannot. *J Bone Joint Surg Br* 2007;89:574-9.
13. Zulkefli A, Jeyasilan K, Zairul AK, Ramanathan R. Comparison of fusion rate between autogenous tricortical iliac crest bone graft and hydroxyapatite block graft in anterior cervical discectomy and fusion surgery. *Malaysian Orthop J* 2009;3:36-9.
14. Jae Sung Ahn, June Kyu Lee, Joung Hun Kim. Comparative Study of Clinical Outcomes of Anterior Cervical Discectomy and Fusion Using Autobone Graft or Cage with Bone Substitute. *Asian Spine Journal* 2011; 5;3:169-175.
15. Bolesta MJ, Rehtine GR 2nd, Chrin AM. One and two-level anterior cervical discectomy and fusion: the effect of plate fixation. *Spine J*. 2002 May-Jun;2(3):197-203.
16. D. Grob, J. V. Peyer, and J. Dvorak. The use of plate fixation in anterior surgery of the degenerative cervical spine: a comparative prospective clinical study. *European Spine Journal* 2011;10;5:408-413.
17. B. Kwon, D. H. Kim, A. Marvin, and L. G. Jennis. Outcomes following anterior cervical discectomy and fusion: the role of interbody disc height, angulation, and spinous process distance. *Journal of Spinal Disorders & Techniques* 2005;18;4:304-308.
18. J.-I. Park, D.-C. Cho, K.-T. Kim, and J.-K. Sung. Anterior cervical discectomy and fusion using a stand alone polyetheretherketone cage packed with local autobone: assessment of bone fusion and subsidence. *Journal of Korean Neurosurgical Society* 2013; 54;3:189-193.