

Incidence of obstacles and complications during distraction histogenesis

Ujjwal Kejariwal^{1,*}, Partap Singh², Rajesh Kapila³, Jagsir Singh⁴, Himanshu Agrahasi⁵

¹Senior Resident, ²Associate Professor, ³Professor, ⁴Junior Resident, ⁵PG Student, Dept. of Orthopaedics, Govt. Medical College, Amritsar, Punjab

***Corresponding Author:**

Email: ujjwalkejriwal@gmail.com

Introduction

The last two decades have witnessed a significant rise in high velocity trauma and violent incidents like bomb blasts and firearm injuries. This has led to increase in severely comminuted open fractures with infection, severe soft tissue trauma, bone loss and non-union. The incidence of non-union in the presence of an open fracture with extensive soft tissue injury, not surprisingly, reaches as high as 20%.⁽¹⁾

In 1986, a US FDA panel defined non-union as “established when a minimum of 9 months has elapsed since injury and the fracture shows no visible progressive signs of healing for 3 months”.⁽²⁾ Non-union is either due to infection (Infective non-union) or there is a significant bone loss during primary trauma (Gap non-union). Even infected non-union ultimately becomes a gap non-union because a significant amount of dead sequestered bone is removed to create a sterile environment for further management. In such gap non-union lies the role of Distraction Histogenesis.

Different modalities of conventional treatment including extensive debridement and coverage of tissue defects with flaps or skin grafts, antibiotic bead packing of the defects, papineau open cancellous grafting, tibio-fibular synostosis, free tissue transfer and bone transplants address the problems of infection and non-union primarily. None are satisfactory and the morbidity is high during treatment. Secondary procedures are often required for correction of bone defects and deformity. This eventually results in multiple surgeries and scarring of the tissues with joint stiffness and oedema, which interfere with an optimal limb function.⁽³⁾

Bone gap and active infection are the crucial factors relating to treatment and prognosis. The recommended strategy for treatment involves two steps: eradication of infection by local radical debridement of dead tissue; followed by reconstruction. Distraction histogenesis done by the application of Ilizarov ring fixator (IRF) or Limb reconstruction system (LRS) is an eminent method for reconstruction in such cases. Benefits like less disruption of the soft tissues, osseous blood supply, and periosteum makes IRF or LRS ideal for soft tissue and fracture management. The advent of IRF by Professor Gavril Abramovich Ilizarov in 1951 revolutionized the treatment of long bone fractures with infected or gap non-union. This system uses fine wires inserted percutaneously which are attached to metal

frame and tensioned to provide a strong construct.⁽⁴⁾ They combine the principles of distraction histogenesis with providing stability to the bone fragments, thus achieving union, eradicating infections, correcting deformities and re-establishing limb length, at the same time maintaining functionality. The concept of LRS was given by Wagner. This unilateral rail fixator system consists pins inserted percutaneously attached to an assembly of clamps which can slide on a rigid rail and can be connected by compression and distraction units. It allows uniplanar distraction.⁽⁵⁾

Distraction histogenesis was popularized by Ilizarov in his biological law of the tissue genesis and growth which states that “slow, steady traction of tissues causes them to become metabolically activated, resulting in an increase in the proliferative and biosynthetic function”. He explained “Tension Stress Effect” which states that a living tissue (capable of regenerating) when put under steady traction, can be lengthened to any extent in the line of tension vector by virtue of increased metabolism and vascularity. This mechanism is most impressive in bones, which is termed distraction osteogenesis, followed in order by muscles, ligaments, tendons and neurovascular structures.⁽⁶⁾

These distraction techniques are a breakthrough in the field of orthopaedic trauma. But just like the two faces of a coin, even such innovations are not immune to complications. There are various complications occurring during distraction histogenesis hindering the bone formation and causing other problems. These can occur in intraoperative, immediate postoperative or late postoperative period. Most of the complications can be prevented by diligent preoperative, intraoperative and postoperative care, and those that occur otherwise, can be treated successfully if diagnosed early and treated accordingly. Hence we need to ponder upon the incidence of these problems during distraction histogenesis.

Grossly the problems can be divided into:

1. Pin related complications
 - a. Neurovascular injury
 - b. Pin tract infection
 - c. Pin site bleeding
 - d. Transient Pain at wire site
 - e. Skin tension caused by wires
 - f. Loosening of wires
 - g. Breaking of wires

2. Soft tissue and bone related complications
 - a. Joint stiffness / Contractures
 - b. Joint luxation
 - c. Axial deviation
 - d. Delayed consolidation
 - e. Premature consolidation
 - f. Refracture after removal of apparatus
3. Miscellaneous
 - a. Reactivation of infection
 - b. Premature removal of apparatus
 - c. Other problems like pain, loss of appetite, weight, depression etc.

Difficulties that occur during limb lengthening were further classified by Dror Paley into 3 sub-classes: Problems, Obstacles and True complications.⁽⁷⁾ This study was undertaken to evaluate the incidence of obstacles and complications arising during Distraction histogenesis and to manage them as and when required.

Materials and Method

This was a prospective study conducted from July 2014 to October 2016. This study included 25 cases of either sex admitted in orthopaedics department after taking informed and written consent from them.

Inclusion criteria:

1. Patients having established non-union with a bone gap.
2. Involvement of one of the long bones of lower limb.
3. Patients aged 14 years or more.

Exclusion criteria:

1. Patients with bone gap due to tumor resection and congenital causes.

2. Patients below 14 years of age.

Detailed clinical examination was done and findings were recorded preoperatively. Under suitable anesthesia, removal of infected implant (if any) was performed. In case of compound fracture, regular debridement and dressings were performed. Skin grafting on healthy granulation tissue performed to close the wound. Infected non-union of long bones were classified according to Jain and Sinha's Classification⁸ as follows:

Type A: Quiescent (non-draining) infection, with or without implant in situ.

A1: Bone gap less than 4 cm.

A2: Bone gap more than 4 cm.

Type B: Active (draining) infection.

B1: Bone gap less than 4 cm.

B2: Bone gap more than 4 cm.

Patients were then fixed with IRF or LRS and corticotomy done. Distraction was started after a latency period at proper rate and rhythm. Patients were discharged and monthly follow-up was done. After docking of bone ends, distraction was stopped and consolidation of regenerate observed with serial monthly radiographs. Fixator was removed after complete union of the fracture site and consolidation of the regenerate site. Various difficulties arising during the treatment were managed accordingly at the earliest. All the complications were recorded and classified according to Paley's classification into Problems, Obstacles and True complications. The results were graded as per modified ASAMI classification which is based on radiological and clinical findings:

	Radiological Criteria	Clinical Criteria
Excellent	Bone Union No infection Deformity <7° Limb length discrepancy <2.5 cm	Ability to perform previous activities of daily living (ADL), No pain or mild pain, no limp, no soft tissue sympathetic dystrophy, knee or ankle joint contracture <5°, Loss of ankle/knee motion <15°
Good	Bone union Failure to meet one of the other criteria	Almost all ADL with minimal difficulty. No pain or mild pain. Failure to meet one of the other criteria.
Fair	Bone union Failure to meet two of the other criteria	Most ADL with minimal difficulty. No pain or mild pain. Failure to meet two of the other criteria
Poor	Non union or refracture Failure to meet three of other criteria	Significantly limited ADL Significant pain requiring narcotics. Failure to meet three of the other criteria.

Results

Out of 25 patients, 12 (48%) were treated using Ilizarov ring fixator while other 13 (52%) were fixed with Limb reconstruction system. Most of the patients (68%) were males in their active life period of 16-45 years, as persons of this age group are involved more in outdoor activities. Involvement of tibia (76%) was more common with distal one-third being involved in 13 out of 25 cases. Right sided bone was operated upon in 68 % of the cases.

Infected non-union was divided as per Jain and Sinha's Classification as shown in Table 1. Most common non-union was type B2 seen in 14 cases.

Bone gap measured on preoperative x-rays was as shown in Table 2. Maximum bone gap was 13 cm in a patient having non-union of femur.

Out of 25 cases, a total of 13 obstacles were seen as shown in Table 3, which occurred in 11 (44%) cases while 14 cases (56%) had no obstacles. The incidence of obstacles was found to be 0.52.

Out of 25 cases, a total of 16 true complications were seen in 13 (52%) cases as shown in Table 4, while 12 (48%) cases had no true complications. The incidence of true complications was 0.64.

A total of 29 obstacles and complications were noted, giving 1.16 per patient as complication rate. Complications were seen in 68% of cases while 8 cases (32%) had no obstacles or true complications.

Various procedures were done during the treatment period to tackle the complications as shown in Table 5.

Results were graded as per modified ASAMI criteria. Bony criteria showed 17 excellent, 5 good, 2 fair and 1 poor result. Functional criteria showed 14 excellent, 9 good, 1 fair and 1 poor result.

Discussion

The technique of Distraction Histogenesis has a wide range of application in the present day orthopaedics. It also has its own associated complications. Most of the work done in the past showed the results of treatment of non-union or compared various fixation techniques used for distraction histogenesis. Most of these studies have not focused primarily on the complications. The present study aimed at evaluation of obstacles and true complications arising during treatment of non-union using distraction histogenesis and to specify the management, as and when required.

The problem of bone defect is compounded by infection, soft tissue damage, scarring, joint contractures and deformities. Treatment in such cases is directed towards osteosynthesis along with sound union, eradication of infection, correction of deformities, correction of limb length, good cosmesis and functional rehabilitation. Distraction histogenesis using Ilizarov ring fixator or Limb reconstruction system addresses these in a safe and effective manner. The hyper vascularity created by corticotomy leads to burn out of infection, also helps in soft tissue and bone repair.

Union was achieved in all but one patient, in who below knee amputation was done. Union rate was 96% in our study. Pin related complications, bone related complications and soft tissue complications as encountered in our study are shown in Fig. 1, Fig. 2, Fig. 3, Fig. 4 and Fig. 5 respectively.

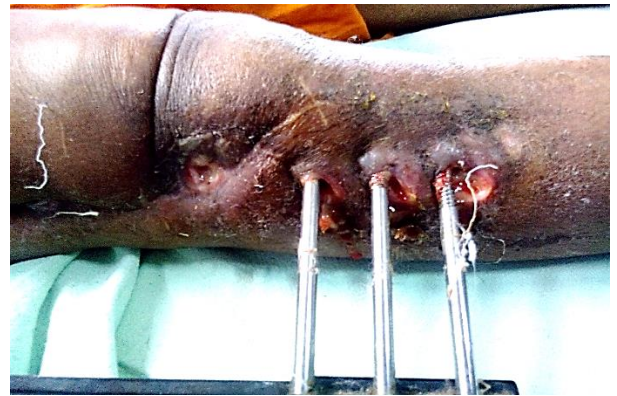

Fig. 1



Fig. 2

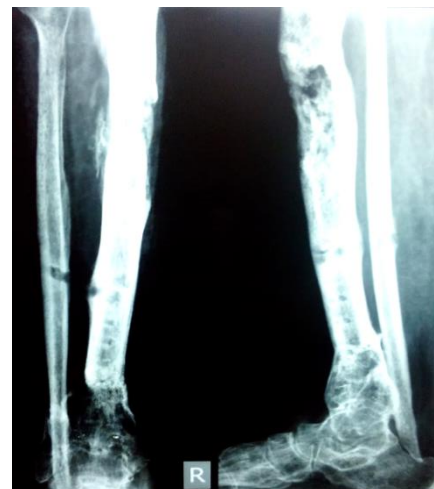


Fig. 3

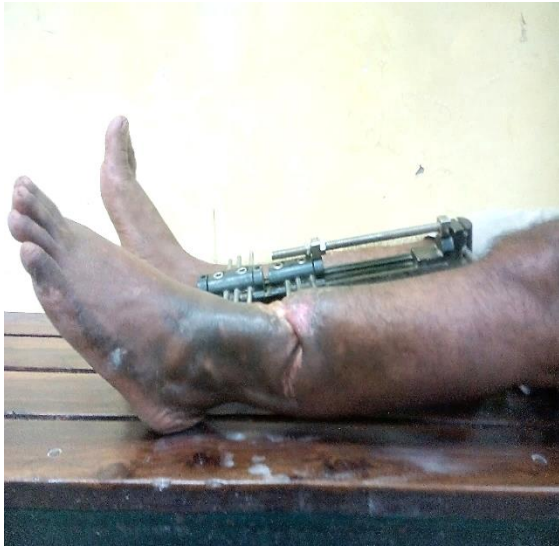

Fig. 4

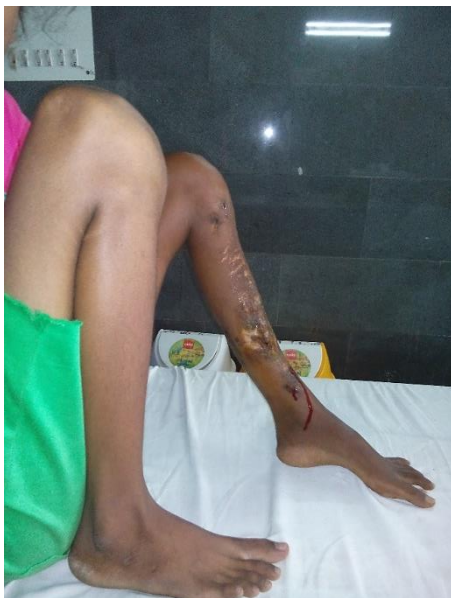

Fig. 5

Difficulties that arise during limb lengthening procedures were classified according to Paley's Classification into problems, obstacles and true complications.

Problems include potential expected difficulties of limb lengthening that occur during the distraction or fixation period, which is fully resolved by the end of the treatment period by non-operative means. These difficulties don't require any intervention and they resolve on their own. Most common problem of distraction histogenesis that occurred in all the patients in our study was Pain at pin site during distraction and Pin tract infection. They were treated by analgesics, sedatives and proper aseptic dressing and meticulous care of skin wire interface along with antibiotics. Timely checking and tensioning of wire and preloading of pins can help in decreasing the infection. Bleeding

from the pin site, premature consolidation, delayed consolidation of regenerate, extensive granulation tissue formation occurred at wound site and pin site were other problems encountered.

Obstacles comprise of potential expected difficulties of limb lengthening that occur during the distraction or fixation period, which is fully resolved by the end of treatment period by operative means. These difficulties resolve within the treatment period and patient is free of obstacles by the end. Dror Paley,⁽⁹⁾ Sreeram PRS⁽¹⁰⁾ and Paley and Maar⁽¹¹⁾ found a total of 11, 10 and 16 obstacles in their studies respectively. Swelling with impingement on the rings of Ilizarov was treated by readjustment of the ring and wires along with medications and keeping the limb elevated after crepe bandage application. Pin loosening and breakage inspite of periodic checking for tension in wires were tightened using tensioner or changed with new pins at different site. Poor regenerate formation was managed by bone grafting of regenerate site to enhance the process of osteogenesis. Infection in the regenerate was treated by debridement of the infection and antibiotics. Construct failure in LRS was treated by readjustment of the pin-clamp unit and fixation to the transport segment and distraction at proper rate. Equinus was managed with delta frame extension added to the IRF of tibia during the distraction phase. Incomplete primary corticotomy due to operative error, was redone at the same site. Pin cut out was seen for which pins were removed and construct reassembled with distal pins at a newer site away from previous. Another obstacle noted was soft tissue invagination with skin tenting at docking site. Freshening of the bone ends at docking site when the bone ends approach each other, after removal of soft tissue interposing, upto the point of exposing the fresh cortical end was done and then compression given intraoperatively to promote union. Any malalignment was corrected simultaneously. Premature consolidation of proximal corticotomy site was tackled by Bifocal corticotomy, while delayed consolidation of regenerate was treated by bone marrow aspirate injection and bone grafting at the regenerate site for consolidation.

Out of 25 cases included in our study, obstacles were seen in 44% (n=11) of cases. A total of 13 obstacles were noted. The incidence of obstacles as noted in our study was found to be 0.52 (52%) per patient. Various studies in literature show varied rates of obstacles. Paley D⁽⁹⁾ had incidence of 0.24 obstacles per patient treated with IRF while the incidence rate of obstacles among 24 patients treated by IRF for grade III open tibia fracture with bone loss was reported to be 38.5% by Senet al.⁽¹²⁾

True Complication comprises of all the intraoperative injuries as well as all the potential expected difficulties that occurred during limb lengthening, that were not resolved before the end of treatment, even by operative means. They persist after the completion of treatment period. In our study 12

(48%) cases had no true complications whereas remaining 13 (52%) patients reported a total of 16 true complications. Paley D⁽⁹⁾ reported a total of 20 true complications out of which 9 true complications were major complications. Sreeram PRS⁽¹⁰⁾ reported 11 true complications in his study while Sen et al⁽¹²⁾ reported true complications in 13.4% of cases. Most common true complication was decreased range of motion at hip and knee joint for which manipulation and physiotherapy was done but range of motion was limited even after that. Patient accepted the difficulty provided weight bearing and ambulation. Axial deviation was also the most common true complication, managed by readjustment of construct in the plane of deformity. Freshening of docking site was also done to achieve proper docking and prevent over distraction. Joint stiffness or contractures was also one of the common true complications in our study for which soft tissue release and physiotherapy was done. In one of the cases, a point to ponder upon was that residual limb length discrepancy of 2 cm, present at the end of the treatment, was compensated by equinus deformity in the same limb segment. So both these complication persisting at the end of treatment was left as it is and no measures were taken for their correction. If both these were not present in same limb segment, equinus would need tendoachilles lengthening and physiotherapy while residual limb length discrepancy would be managed by giving shoe raise. Below knee amputation was done in one patient having intolerable pain and persisting infection with non-union. Patient non-compliance was the major indication for amputation. Persistent discharging sinus at infected non-union site was managed by sinus tract curettage and intravenous antibiotics. One of the cases in our study suffered intraoperative vascular injury where during the debridement procedure at distal femur, popliteal artery was cut inadvertently. Vascular repair was done by vascular surgeon emergently but vascularity of toes decreased causing blackening of great toe within 3 days. No nerve injury was seen in our study as wire and pin insertion was done after considering the safe planes in the limb under treatment. Refracture at the docking site few days after removal of the IRF occurred in which IRF was applied again and 4 cycles of compression-distraction done to achieve union. Distal migration of fibula due to transfixation of proximal fibular segment along with the transport segment of tibia was seen but didn't need any correction as it was not associated with any knee or ankle joint instability or common peroneal nerve injury. Bending of the regenerate of 10 degree was also seen. Other complications like reflex sympathetic dystrophy, late bowing, haematoma, chronic osteomyelitis, and deep vein thrombosis are also to be noted in cases treated with distraction histogenesis. We didn't come across these complications in our study but they are worth

mentioning as they were reported in various studies in the literature.

Out of 25 cases included in our study, true complications were seen in 52% (n=13) of cases. A total of 16 true complications were noted. The incidence of true complications as noted in our study was found to be 0.64 (64%) per patient. Various studies in literature show varied rates of true complications. Paley D⁽⁹⁾ had incidence of 0.43 true complications per patient treated with IRF while the incidence rate of true complications among 24 patients treated by ilizarov ring fixator for grade III open tibia fracture with bone loss was reported to be 13.4% by Sen et al.⁽¹²⁾

A total of 29 obstacles and true complications occurred in the 25 cases treated by distraction histogenesis in this study. Thus the combined incidence rate was 1.16 complications per patient. Complications were seen in a total of 68% (n=17) of cases while 8 cases (32%) didn't show any obstacle or true complications. On review of literature, various studies of bone transport had a mean of 1.8 complications per patient which is very close to the rate obtained from our study.^(11,13,14-21) Sen et al also reported a rate of 1.2 complications per patient.⁽²²⁾ Moreover in the systemic review and meta-analysis done by Yin et al reported 1.36 complications per patient.⁽²³⁾

In our study, during the period from the application of fixator to its removal, various surgical procedures were done to tackle the complications arising during limb lengthening procedure. A total of 67 procedures were done in 25 patients, an average of 2.68 procedures were performed per patient.

Maximum number of cases (56%) required freshening of docking site. After completion of distraction, when two bone ends approach each other, soft tissue gets interposed between the bone ends. At this docking site, soft tissue removal to the point of exposing the fresh cortical end, restoration of the medullary canal and then compression at the site was done to obtain union. This is one of the procedure on which limited study is available in literature. So the mention of this procedure is of paramount importance.

The results of our study show that the benefits of distraction histogenesis outweigh the associated complications. This technique can be limb saving in the setting of high energy trauma with bone loss and extensive soft tissue damage and in cases with badly infected wound along with deep bony infections resistant to antibiotics. This technique plays a crucial role in damage control orthopaedics as well as infective etiologies. The complications arising during this technique needs special attention for management as the soft tissue and vascularity is already compromised in the patients. Utmost importance should be given to prevent the complications rather than treating them. Proper technique after learning theoretically and practically along with experience is the key to reducing the incidence of obstacles and complications. Non-

compliance of the patient due to long duration of treatment if a major deterrent which needs to be addressed before beginning the treatment in such cases through proper counselling and knowledge of the patient.

Conclusion

From this prospective study of 25 cases of gap non-union treated by distraction histogenesis, we can conclude that treatment of bone gap by distraction histogenesis using ilizarov ring fixator or limb reconstruction system is an excellent method for limb salvage. But even such a procedure is not immune to complications. Benefits outweigh the risk of complications, hence this technique continues to be an important part of an orthopaedician's armamentarium and the use is on a rising trend. It thus becomes important to highlight the complications and to evaluate the incidence. Further these complications need to be managed efficiently and preventive measures followed in future cases. This study was an effort to widen the horizon of our knowledge of distraction histogenesis procedure with specific focus on associated complications.

References

1. Sen MK, Miclau T. Autologous iliac crest bone grafting: should it still be the gold standard for treating nonunions? *Injury*. 2007;38(Suppl 1):S75-S80.
2. Canale ST, Beaty JH. Non union. In: Campbell's Operative Orthopaedics. 12th ed. Philadelphia: Elsevier Mosby;2013:2981-95.
3. Ilizarov GA. The tension-stress effect on the genesis and growth of tissues. In: Transosseous osteosynthesis: Theoretical and clinical aspects of the regeneration and growth of tissue: The historical background of Transosseous Osteosynthesis; Springer- Verlag, New York. 1989;1.2:6-7.
4. Mohammad S, Abid H, Phillipa B, Bose D. Clinical Outcome of the Ilizarov method after an Infected tibial Non Union. *Archives of Trauma Research*. 2013;2(2):71-5.
5. Aaron AD, Eilert RE. Results of the Wagner and Ilizarov methods of limb-lengthening. *The Journal of Bone and Joint Surgery America*. 1996 ;78(1):20-9.
6. Ilizarov GA. Clinical application of the tension-stress effect for limb lengthening. *Clin Orthop Relat Res* 1990;250:8-26.
7. Paley D. Problems, Obstacles, and Complications of Limb Lengthening by the Ilizarov Technique. *Clin Orthop Relat Res* 1990;250:81-104.
8. Jain AK, Sinha S. Infected non-union of the long bones. *Clin Orthop Relat Res* 2005;431:57-65.
9. Paley D. Ilizarov treatment of tibial non-union with bone loss. *Clin Orthop Relat Res* 1989;241:146-65.
10. Sreeram PRS. A study on functional outcome of ilizarov fixation in the management of infected non-union of long bones. *Indian Journal of Orthopaedics Surgery* 2016;2(2):187-93.
11. Paley D, Maar DC. Ilizarov bone transport technique for tibial defects. *J Orthop Trauma* 2000;14(2):76-85.
12. Sen C, Kocaoglu M, Eralp L et al. Bifocal Compression-Distractor in the Acute Treatment of Grade III Open Tibia Fractures with bone and soft-tissue loss: A report of 24 Cases. *Journal of Orthopaedic Trauma* 2004;18(3):150-7.
13. Cattaneo R, Catagni M, Johnson EE. The treatment of infected nonunions and segmented defects of the tibia by the methods of Ilizarov. *Clin Orthop Relat Res*. 1992;280:143-52.
14. Green SA, Jackson MJ, Wall DM, Marinow H, Ishkanian J. Management of segmental defects by the Ilizarov intercalary bone transport method. *ClinOrthop* 1992;280:136-42.
15. Cierny G 3rd, Zorn KE. Segmental tibial defects: comparing conventional and Ilizarov methodologies. *Clin Orthop* 1994;301:118-23.
16. Marsh JL, Prokuski L, Biermann JS. Chronic infected tibial non-unions with bone loss: conventional techniques versus bone transport. *Clin Orthop* 1994;301:139-46.
17. Saleh M, Rees A. Bifocal surgery for deformity and bone loss after lower limb fractures: comparison of bone-transport and compression-distractor methods. *J Bone Joint Surg [Br]* 1995;77-B:429-34.
18. Dendrinos GK, Kontos S, Lyritis E. Use of the Ilizarov technique for treatment of non-union of the tibia associated with infection. *J Bone Joint Surg [Am]* 1995;77-A:835-46.
19. Polyzois D, Papachristou G, Katsiopoulos K, Plessas S. Treatment of tibial and femoral bone loss by distraction osteogenesis: experience in 28 infected and 14 clean cases. *Acta Orthop Scand* 1997;68(Suppl 275):84-8.
20. Atesalp AS, Basbozkurt M, Erler E. Treatment of tibial bone defects with the Ilizarov circular external fixator in high-velocity gunshot wounds. *Int Orthop* 1998;22:343-7.
21. Song HR, Chao SH, Koo KH. Tibial bone defect treated by internal bone transport using the Ilizarov method. *Int Orthop* 1998;22:293-7.
22. Sen C, Eralp L, Gunes T. An alternative method for the treatment of non-union of the tibia with bone loss. *J Bone Joint Surg [Br]* 2006;88-B:783-9.
23. Yin P, Ji Q, Li T. A Systematic Review and Meta-Analysis of Ilizarov Methods in the Treatment of Infected Non-union of Tibia and Femur. *PLoS ONE*. 2015;10(11):e0141973.