

Long term outcome and ideal screw placement in Bristow procedure for anterior glenohumeral instability

Mohammed Ashraf¹, Blessin S. Cherian^{2,*}, Kumar Chandan³

¹Professor & HOD, ^{2,3}Senior Resident, Dept. of Orthopaedics, Govt. T.D. Medical College, Alleppey, Kerala

***Corresponding Author:**

Email: blessincherian@yahoo.com

Abstract

Introduction: The glenohumeral joint being the most mobile joint is highly susceptible to dislocations. Majority of recurrences occur within 2 years of first traumatic dislocation. Surgical stabilisation is indicated when recurrent instability causes discomfort. Numerous procedures have been described for surgical stabilisation of the shoulder joint. Some of these like the Bankart's procedure are anatomic and others like the Bristow procedure are non anatomic. We decided to evaluate the long term outcome of the Bristow procedure and the ideal position for screw placement in this procedure.

Materials and Method: We evaluated 56 patients who underwent the procedure between 2000 and 2006. They were assessed using the ROWE score which includes stability, range of motion, daily function and pain. Radiographic evaluation was also done to know the status of the graft and confirm screw position.

Result: 80% of our patients had good to excellent results at the end of a mean follow up of 10.4 years. The average loss of external rotation was 10 degrees and loss of internal rotation was 5 degrees. The patients with screw at four o' clock position had a better outcome compared with three o' clock and five o' clock positions.

Conclusion: The Bristow procedure continues to be an excellent option for recurrent anterior glenohumeral instability. The status of graft union did not correlate functionally.

Keywords: Bristow procedure, Glenohumeral instability, Coracoid graft, Screw placement.

Introduction

The wide range of motion and relatively loose anterior inferior recess of the glenohumeral joint makes it highly susceptible to anterior dislocation or subluxation.⁽¹⁾ 50 percent of all dislocations involve the shoulder joint, especially in younger individuals.⁽²⁾ Dislocations may be due to traumatic or non traumatic causes. When traumatic it results from a direct force on the joint or an excessive vectoral force causing the humeral head to dislocate.⁽²⁾ Numerous operative procedures have been proposed for the same, however all the procedures aim to reinforce the anterior and inferior aspect of the glenohumeral joint.⁽³⁾ In 1954, Latarjet described transfer of the coracoid process through the subscapularis tendon and anchoring it to the scapular neck using a screw.⁽⁴⁾ In 1958, Helfet described a similar procedure wherein the coracoid process along with the conjoint tendon was passed through a vertical split in the subscapularis tendon and it was anchored to the scapular neck using sutures. He had named the procedure to honour his mentor W. Rowley Bristow.⁽⁵⁾ Multiple modifications have been made to the original description^(6,7,8) but the end result is a coracoid bone block in the anteroinferior glenoid and augmentation of the dynamic subscapularis sling. The aim of our study was to evaluate the functional outcome of the Bristow procedure and to define the ideal position of the screw placement for the same.

Materials and Method

The Bristow procedure had been into use since 1995 in our institution. The data of all patients who underwent

Bristow procedure between 2000 and 2006 were retrospectively reviewed. This included 56 patients of which five were females. The procedure was performed for patients with traumatic, unidirectional anterior shoulder instability. Patient evaluation comprised of a questionnaire, clinical evaluation and radiographs. Questionnaire included details regarding the age of first dislocation, number of recurrences, presence of pain and the mode of first dislocation.

The operative procedure involved a standard deltopectoral approach in order to expose the coracoid process. All the surrounding soft tissues were cleared and the coracoid process was predrilled using a 3.2mm drill bit. Osteotomy was done at 1.5cm from the tip and care was taken to avoid damage to the insertion of pectoralis minor. The subscapularis muscle was then split in the direction of its fibres midway between the upper and lower half. The capsule was exposed and incised in the same direction of the subscapularis muscle. The joint was explored for any loose bodies or bony lesions in the humeral head. The graft was placed at a point just below the equator of the glenoid within 1cm of the articular margin, the point of graft placement was well curetted in order to promote bony union. In the original description of the Bristow- Latarjet procedure, the graft was placed in "lying" position and fixed with one or preferably two screws to avoid rotation of the graft. However we prefer to place the graft in a "standing" position and fixation was done using a single screw with washer, the issues related to rotation were managed by a steady grasp in the last phase of screw tightening. The drill was made in the antero posterior

direction by directing it perpendicular to the scapular wing and not to the operating table. The subscapularis tendon was sutured by holding the shoulder in internal rotation. Post operatively the shoulder was immobilised in a position of adduction and internal rotation using a special shoulder immobiliser for 3 weeks. After 3 weeks gentle passive mobilisation was started and patient was encouraged active movements after a period of 6 weeks.

Post operatively the shoulder range of motion in all planes were evaluated and stability assessed using apprehension test for anterior stability and sulcus sign for inferior stability. The overall stability and function of the shoulder was assessed using the Rowe score.^(9,10) The parameters include stability, range of motion, daily function and pain. Any score below 50 was graded as poor, 51-74 as fair, 75-89 as good and 90-100 as excellent. Radiographs were evaluated by two surgeons with special attention to position of screw, union of graft and any degenerative changes of the joint.

Result

The mean follow up was 10.4 years (4-15 years). We lost six patients in follow up, hence the results confine to 50 patients. The mean age of the patients at the time of surgery was 24 years (18 – 42). 43 (86%) patients underwent surgery on their dominant side and the remaining seven (14%) on the non dominant side, we did not have any bilateral cases. 47 patients (95%) gives history of trauma mostly in the form of road traffic accidents and sports injuries. Three patients (5%) did not

have any history of trauma. The mean number of dislocations were 10 (3-24) and the average time interval between the initial injury and surgery was 24 months (6-40). Intra operatively 20 patients (40%) had a Bankart's lesion and two patients (4%) had loose bodies. Post operatively one patient developed a hematoma which subsided without the need for any exploration. One patient developed a transient rotator cuff tendinitis in the initial phase of rehabilitation. Two of our patients underwent subsequent dislocation. One patient sustained a road traffic accident at the end of four months. Radiographs revealed a displaced graft. On exploration the screw was found to be bent and hence the graft was secured with staples after screw removal. The other patient was a manual labourer and sustained the dislocation 12 months post surgery when he tried to balance a slipping overhead weight. On exploration the graft showed solid union hence only an additional Putti Platt procedure was done. Both these patients did not face any problems subsequently. Six patients (12%) demonstrated a positive apprehension test however they did not have any problems in carrying out day to day activities. Five patients (10%) complained of persistent shoulder pain and had to undergo implant removal at an average of 30 (10 – 50) months post surgery. However in all these patients as there was bony union, no additional procedure was required. One of these patients continued to complain of mild soreness with overhead activities. There was an average loss of 10 degrees of external rotation (0-45) and an average loss of five degrees (0-40) of internal rotation in our patients.

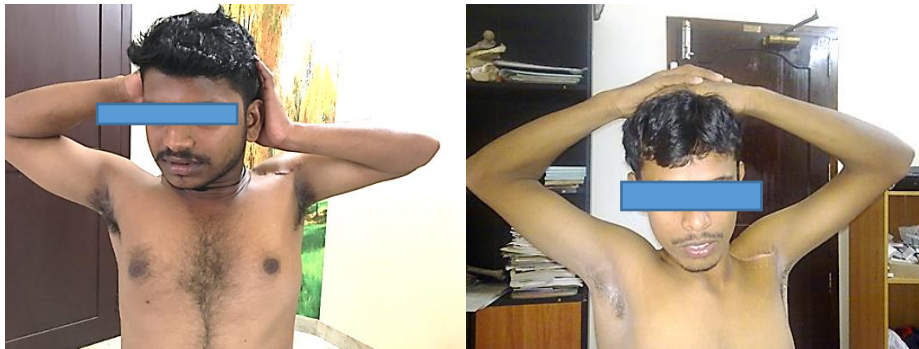

Fig. 1, 2: Post operative abduction and external rotation

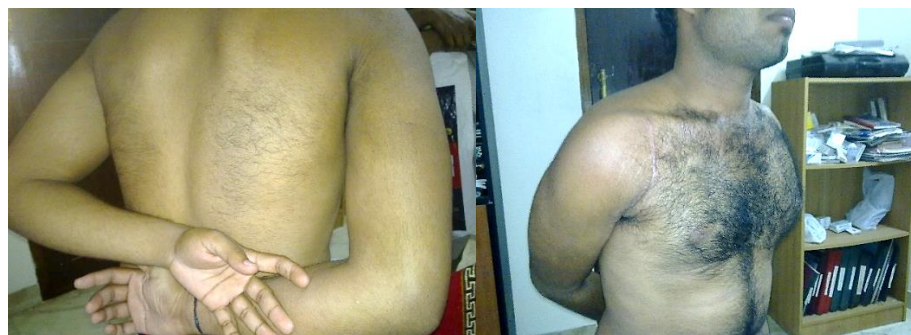

Fig. 3, 4: Post operative internal rotation

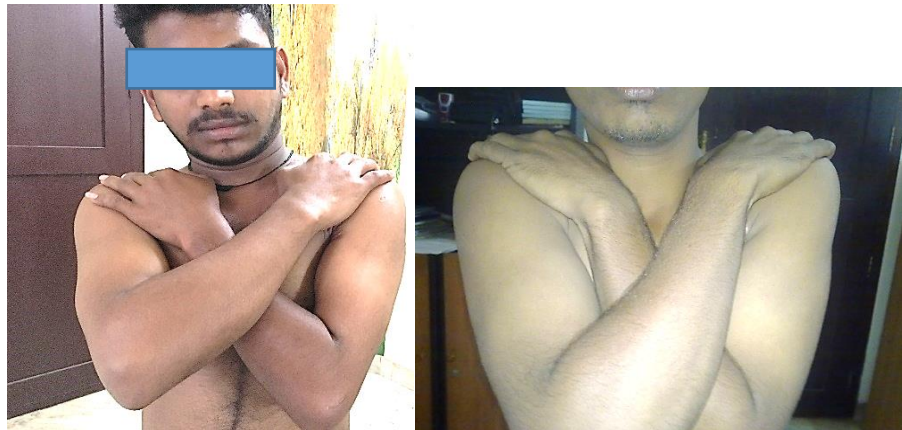

Fig. 5, 6: Post operative adduction

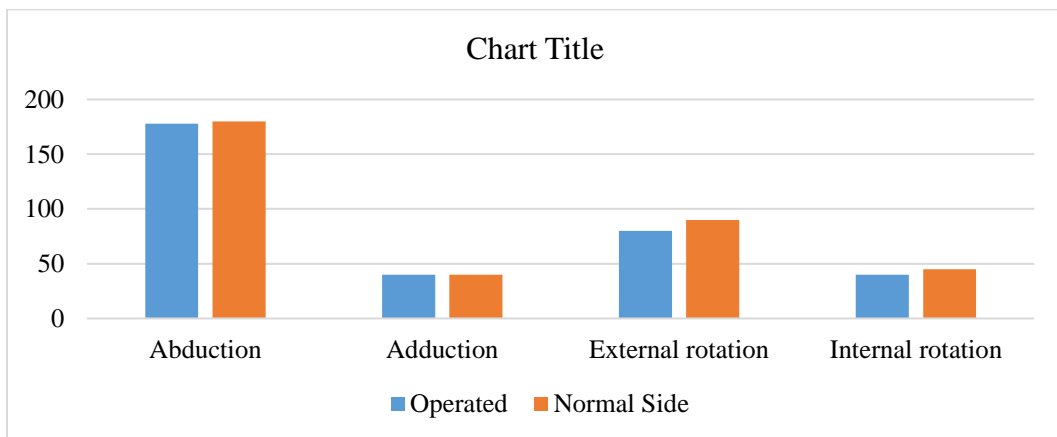


Fig. 7: Average range of motion following Bristow Procedure

Radiographically 44 patients (88%) attained a bony union and five patients (10%) showed fibrous union and one patient (2%) had screw loosening however he did not have any functional deficit. 40 (80%) of our screws were placed in the four o' clock position and five screws (10%) each in the three o' clock and five o' clock position. Post operative ROWE scoring revealed 30 patients (60%) having excellent, 10 patients (20%) with good, nine patients (18%) having fair and one (2%) patients with poor results. Amongst the six patients with positive apprehension, four (67%) patients had the bone block placed at five o' clock position. Amongst the patients with good results four patients had the bone block at four o' clock, three at three o' clock and three at five o' clock position (33% each).

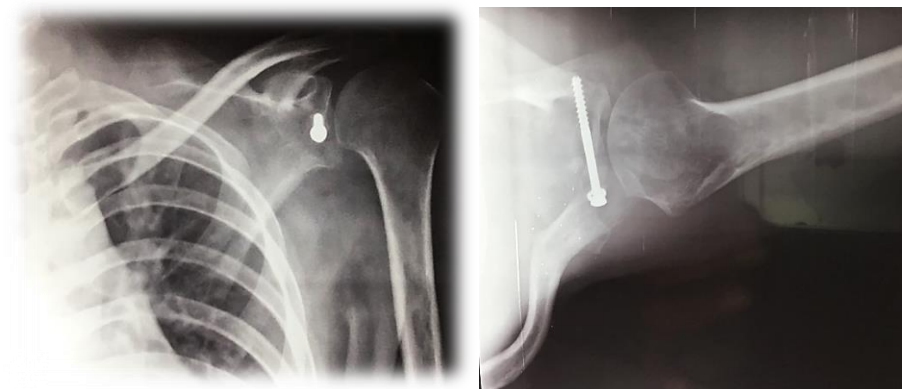


Fig. 8: AP view showing anteroinferior Figure 9- Axillary view showing united graft with position of graft with screw implant in-situ

Discussion

Open surgeries have been classically described for anterior glenohumeral instability. The longest follow up reported so far is 26 years by Schroder et al⁽³⁾ (49 patients) in a group of Naval academy officers. This study reported good to excellent results in nearly 70% of subjects. Banas et al⁽¹¹⁾ (71 patients) reported 85% good to excellent results. We also had similar results with 80% (40 patients) having good to excellent results. Of the 212 consecutive modified Bristow procedures by Torg et al⁽¹²⁾ eight (3.8%) dislocations and 10 (4.7%) subluxations at a mean follow-up of 3.5 years was reported, but when adjusted for the number of respondents (131 of 207), the actual percentages were 6.1% for recurrent dislocations and 7.6% for subluxation. Our results are also similar with 4% (two patients) recurrent dislocations, however both our patients sustained a post traumatic dislocation. Our results are also consistent with those of Hovelius et al⁽¹³⁾ and Ferlic et al⁽¹⁴⁾ who observed that the dislocations occur early in the post operative period usually in the first year following surgery. In a series of 118 patients by Hovelius et al⁽¹⁵⁾ following Bristow- Latarjet procedure there was an average loss of 12.4 degrees of external rotation at a mean follow up of 15.2 years. Our study revealed an average loss of 10 degrees of external rotation. Most authors have reported an average loss of 9 to 12 degrees of external rotation.^(11,13,16,17,18,19) Complications have been described due to technical error of placement of screw and or coracoid, in the form of loss of motion,^(20,21,22) arthritis,^(20,21,22,23) screw breakage,^(12,14,20) screw migration and non union of coracoid tip.^(20,21,22) Following a Bristow procedure 4.7% to 14% screw complications have been reported.^(12,14) In our study 10% of our patients complained of persistent pain which was relieved after screw removal. Several complications can be avoided with the use of biodegradable implants.⁽²⁴⁾ Hovelius et al⁽²¹⁾ described the proper placement of the coracoid tip, below the anterior equator of the scapular neck and less than 1 cm medial to the glenoid rim. In 80% of our patients the screw was placed in the four o' clock position and they had a better outcome as compared to those with screws at three o' clock or five o' clock position. Arthroscopic techniques are the current trend in the management of shoulder instability, however a meta analysis in 2005 comparing the outcome of open and arthroscopic techniques found a more favourable result with open technique in terms of recurrence and return to activity.⁽²⁵⁾

Conclusion

The Bristow procedure continues to be an excellent open procedure for recurrent anterior gleno humeral instability provided the surgeon is familiar with the technique. Although it is a non anatomic repair it provided good to excellent results in 80% of our patients. The ideal position for screw placement is a four o' clock

position (below the anterior equator and less than 5mm medial to the articular surface of the glenoid). Bony union, fibrous or non union does not correlate with the functional outcome of the patient.

References

1. Vilson Ruci, Artid Duni, Alfred Cake, Dorina Ruci, Julian Ruci. Bristow-Latarjet Technique: Still a Very Successful Surgery for Anterior Glenohumeral Instability - A Forty Year One Clinic Experience. *OA Maced J Med Sci.* 2015 Jun 15;3(2):310-314.
2. G Matthes, V Horvath, J Seifert, H Ptok, D Stengel, U Schmucker, A Ekkernkamp, P Hinz. Oldie but goldie: Bristow-Latarjet procedure for anterior shoulder instability. *Journal of Orthopaedic Surgery* 2007;15(1):4-8
3. David T. Schroder, Matthew T. Provencher, Timothy S. Mologne, Michael P. Muldoon and CAPT Jay S. Cox. The Modified Bristow Procedure for Anterior Shoulder Instability:26-Year Outcomes in Naval Academy Midshipmen. *The American Journal of Sports Medicine*, Vol. 34, No. 5,2006.p 778-786.
4. Hovelius L, Akermark C, Albrektsson B, et al The Bristow-Latarjet procedure for recurrent dislocation of the shoulder A 2-5 year follow-up study on the results of 112 cases *Acta Orthop Scand* 54 284-290, 1983.
5. Helfet A. Coracoid transplantation for recurring dislocation of the shoulder. *J Bone Joint Surg Br.* 1958;40:198-202.
6. Bonnin J. Transplantation of the coracoid tip: a definitive operation for recurrent anterior dislocation of the shoulder. *Proc R Soc Med.* 1973;66:755-758.
7. May V. A modified Bristow operation for anterior recurrent dislocation of the shoulder. *J Bone Joint Surg Am.* 1970;52:1010-1016.
8. Mead N, Sweeney H. Bristow procedure [letter]. *Spectator Letter.* July 9, 1964.
9. Rowe CR. Instabilities of the glenohumeral joint. *Bull Hosp Joint Dis* 1978;39:180-6.
10. Rowe CR, Zarins B. Recurrent transient subluxation of the shoulder. *J Bone Joint Surg Am* 1981;63:863-72.
11. Banas M, Dalldorf P, Sebastianelli W, DeHaven K. Long-term followup of the modified Bristow procedure. *Am J Sports Med.* 1993;21: 666-671.
12. Torg J, Balduini F, Bonci C, et al. A modified Bristow-Helfet-May procedure for recurrent dislocation of the shoulder. *J Bone Joint Surg Am.* 1987;69:904-913.
13. Hovelius L, Sandstrom B, Rosmark D, Saebø M, Sundgren K, Malmqvist B. Long-term results with the Bankart and Bristow-Latarjet procedures: recurrent shoulder instability and arthropathy. *J Shoulder Elbow Surg.* 2001;10:445-452.
14. Ferlic D, DiGiovine N. A long-term retrospective study of the modified Bristow procedure. *Am J Sports Med.* 1988;16:469-474.
15. Hovelius L, Sandstrom B, Sundgren K, Saebø M. One hundred eighteen Bristow-Latarjet repairs for recurrent anterior dislocation of the shoulder prospectively followed for fifteen years, study I: clinical results. *J Shoulder Elbow Surg.* 2004;13:509-516.
16. Barry T, Lombardo S, Kerlan R, et al. The coracoid transfer for recurrent anterior instability of the shoulder in adolescents. *J Bone Joint Surg Am.* 1985;67:383-387.
17. Braly W, Tullos H. A modification of the Bristow procedure for recurrent anterior shoulder dislocation and subluxation. *Am J Sports Med.* 1985;13:81-86.

18. Lombardo S, Kerlan R, Jobe F, Carter V, Blazina M, Shields C. The modified Bristow procedure for recurrent dislocation of the shoulder. *J Bone Joint Surg Am.* 1976;58:256-261.
19. Rowe C, Patel D, Southmayd W. The Bankart procedure: a long-term end result study. *J Bone Joint Surg Am.* 1978;60:1-16.
20. Allain J, Goutallier D, Glorion C. Long-term results of the Latarjet procedure for the treatment of anterior instability of the shoulder. *J Bone Joint Surg Am.* 1998;52:841-852.
21. Hovelius L, Korner L, Lundberg G, et al. The coracoid transfer for recurrent dislocation of the shoulder: technical aspects of the Bristow repair. *J Bone Joint Surg Am.* 1983;65:926-934.
22. Young D, Rockwood C. Complications of a failed Bristow procedure and their management. *J Bone Joint Surg Am.* 1991;73:969-981.
23. Rowe C, Zarins B, Cuillo J. Recurrent anterior dislocation of the shoulder after surgical repair. *J Bone Joint Surg Am.* 1984;66: 159-168.
24. Bostman OM Absorbable implants for the fixation of fractures *J Bone Joint Surg* 73A 148-153, 1991.
25. Mohtadi NG, Bitar IJ, Sasyniuk TM, Hollinshead RM, Harper WP. Arthroscopic versus open repair for traumatic anterior shoulder instability: a meta-analysis. *Arthroscopy* 2005;21:652-8.