

The comparison of triceps reflecting anconeus pedicle and olecranon osteotomy approaches in the treatment of intercondylar fractures of the humerus

Sulay Sachdev^{1,*}, Keyur Shah², Meet Mehta³, Dinesh Limbachiya⁴

^{1,3,4}Resident, ²Assistant Professor, Dept. of Orthopaedics, BJ Medical College, Ahmedabad, Gujarat

***Corresponding Author:**

Email: sullusachdev@gmail.com

Abstract

Introduction: Intercondylar fractures owing to complex anatomy of elbow joint and neurovascular structures in surrounding makes it difficult to treat. Operative techniques like open reduction and internal fixation helps in achieving desired anatomy and improves patient compliance. This study is aimed at comparing outcome of patient treated with triceps reflecting anconeus pedicle (TRAP) approach and olecranon osteotomy.

Objective: Comparison among exposure modalities of Open reduction internal fixation by triceps reflecting anconeus pedicle approach and olecranon osteotomy.

Materials and Method: This is a retrospective study of 50 patients with supracondylar fracture humerus treated by open reduction and internal fixation in Civil Hospital, Ahmedabad from April 2016 to March 2017. TRAP approach was used in 28 patients (16 males, 12 females) and olecranon osteotomy was used in 22 patients (12 males, 10 females). DASH (Disabilities of Arm, Shoulder and Hand) and MEPS (Mayo Elbow Performance Score) were used as tools for assessment.

Result: Range of movement of elbow is 85-135 in TRAP group whereas in olecranon osteotomy group it is 65- 110 (p=). This difference is significant (p= 0.038)

In terms of mean MEPS and DASH score difference is not significant.

Complication rate was 32.14% in TRAP group whereas it was 55% in olecranon osteotomy group.

Conclusion: Thus ORIF with exposure techniques involving triceps reflecting anconeus pedicle is better approach in terms of lower complication rate and higher range of movements.

Keywords: Intercondylar humerus, Open reduction and internal fixation, Olecranon osteotomy, TRAP

Introduction

Fractures of distal end humerus accounts for 2% of all fractures in adults. These fractures are one of the most difficult fractures to treat in owing to its complex anatomy and passing by neurovascular bundles. Articular surface reconstruction and internal fixation with minimal loss of nearby tissue is required for maximum functioning of elbow joint. In order to achieve so as much as possible exposure of articular surface is required to bring anatomical correction and stable internal fixation. Intra-articular fractures of distal humerus (AO type C) accounts for 1% of all fractures in adults. For better visualization of articular surface olecranon osteotomy, triceps reflecting (Bryan-Murray), triceps splitting (Campbell) and triceps- reflecting anconeus pedicle approaches are being used.

- Olecranon osteotomy provides best exposure. But, nonunion, delayed union, avascular necrosis, implant impingement are associated drawbacks with it.
- TRAP approach avoids osteotomy and related complications. This approach provides limited exposure thus takes longer duration in surgery and causes weakness of triceps muscle.
- The superior technique between the two is a questionable. This study is aimed at comparing TRAP approach with olecranon osteotomy in regards to functional outcome of intra-articular distal end humerus fractures.

Materials and Method

This is a retrospective study of 50 patients with supracondylar fracture humerus treated by open reduction and internal fixation in Civil Hospital, Ahmedabad from April 2016 to March 2017. TRAP approach was used in 28 patients (16 males, 12 females; mean age 41 years, range 21-65 years) and olecranon osteotomy was used in 22 patients (12 males, 10 females; mean age 35 years, range 18- 70 years).

Table 1: Distribution of patients according to exposure modality used

Parameters	TRAP(n=28)	Olecranon osteotomy(n=22)
Sex Ratio (M/F)	16/12	12/10
Mean age (year)	41	35
AO/ASIF Classification		
C I	05	04
C II	11	08
C III	12	10

Inclusion criteria:

1. age < 70 years
2. Type CI, CII, CIII fracture according to AO classification

Exclusion criteria:

1. Age >70 years
2. Type A and Type B
3. Patient with medical co-morbidities
4. Open fracture
5. Pathological fracture
6. Fractures in patient with head injury and polytrauma
7. Fractures with neurovascular injury

All patients were evaluated with mayo elbow performance score (MEPS) and the disabilities of arm, shoulder and hand (DASH) questionnaire score.

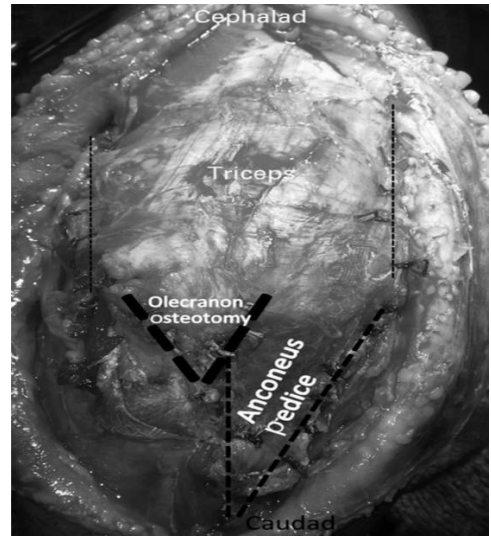


Fig. 1: Initial exposure after incision common to TRAP and olecranon osteotomy

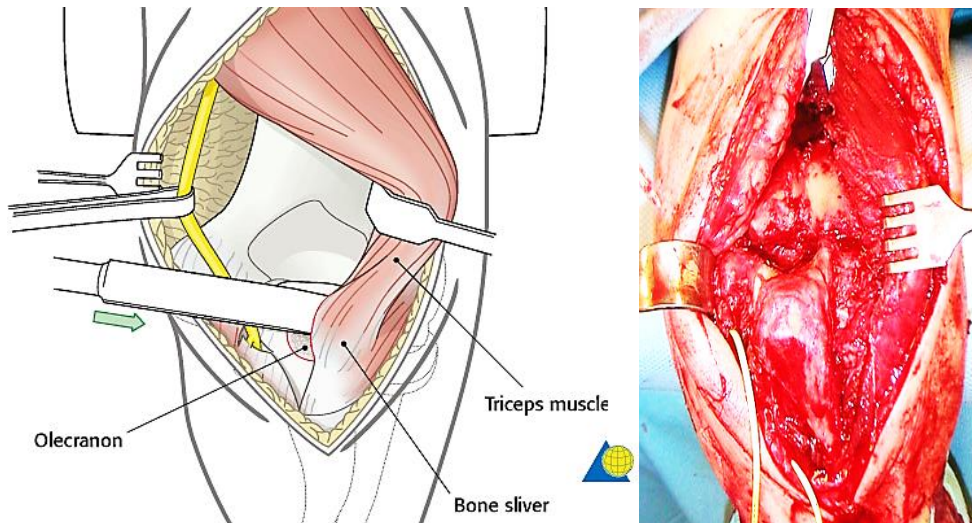


Fig. 2: Intra-operative image showing exposure of intra-articular surface in TRAP procedure

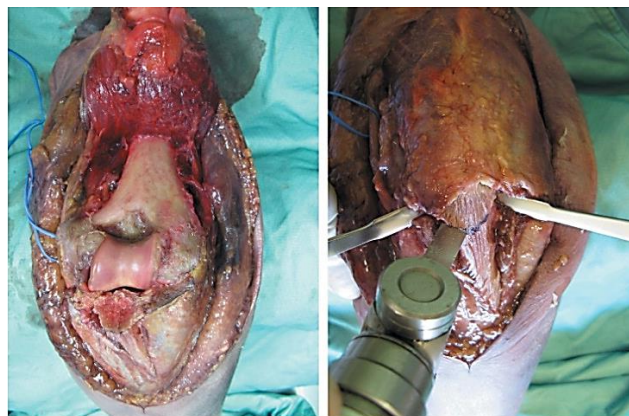


Fig. 3: Intra-operative image showing exposure of intra-articular surface in olecranon osteotomy approach

Muller's AO classification

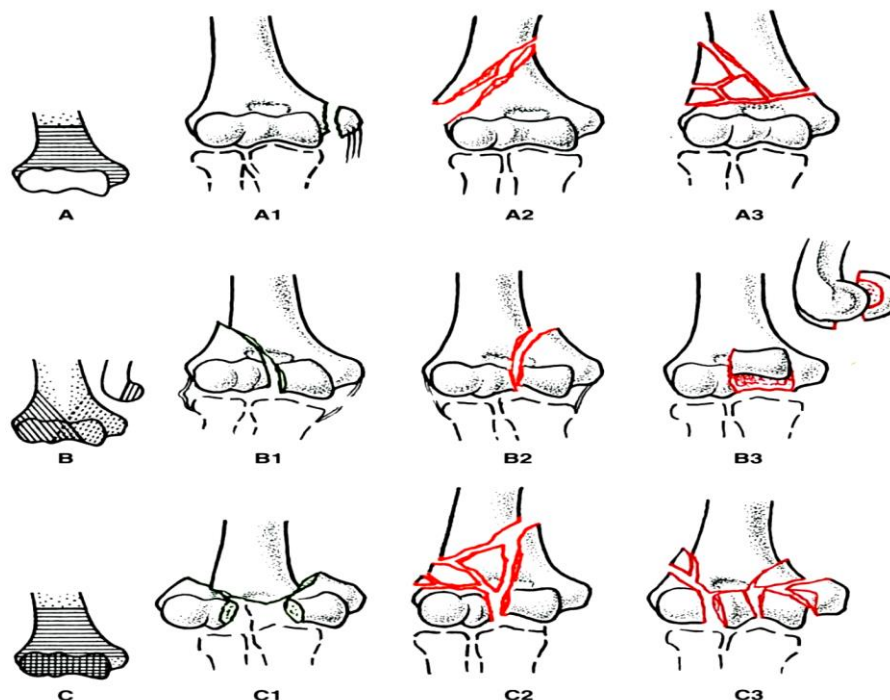


Fig. 4: AO classification of distal end humerus fracture

Both groups were operated maintaining same pre-operative precautions and intra-operative sterile measures with respective surgical approach under cover of antibiotics and analgesics which are same in both groups. In post-operative phase AE slab was given in both groups. Active assisted elbow movements was started on post op day 2.

But, active extension was prohibited in TRAP group to avoid stress on extensor mechanism repair. All patients were called for follow up on 1, 6 and 12 months. On each follow up patients were assessed clinically by means of goniometric measurement of range of motion around elbow joint, Mayo elbow performance score (MEPS), and Disability of Arm, Shoulder and Hand (DASH) questionnaire and radiologically by means of antero-posterior and lateral radiographs of elbow joint.

Patients were divided according to MEPS in 4 grades: >90, excellent; 75-89, good; 60-74, fair; <60, poor.

Results

Difference of age, sex, time to operation, peri operative analgesic and antibiotic cover are not statistically significant in between both groups. Range of movement of elbow was 85-135 in TRAP group and whereas that of olecranon osteotomy group was 65-110. This difference is statistically significant ($p=0.038$).

Table 2: Results obtained in patients operated by TRAP and Olecranon osteotomy approach

Parameters	TRAP(n=28)	Olecranon osteotomy(n=22)
Mean Range of elbow motion(range)	110 (85-135)	87 (65-110)
Mean DASH score	15.6(0-40)	20.1(4-57)
Mean MEPS score	89.9(55-100)	83.5(55-100)
Excellent, n(%)	14(50)	06(27.2)
Good, n(%)	06(21.4)	06(27.2)
Fair, n(%)	02(7.1)	02(9)
Poor, n(%)		

Complications

- Complication rate was 28.5% patients while it was 54.5% in patients treated with olecranon osteotomy.
- In TRAP group, 3 patients (10.7%) developed ulnar nerve paresthesia. 2 patients(7.1%) suffered triceps weakness. 1 patient(3.5%) developed varus deformity without significantly hampering elbow movement. 2 patients(7.1%) developed incision site infection within 4weeks of discharge.
- In olecranon osteotomy group, 5 patients(22.7%) presented with complain of implant impingement. 3 patients(13.6%) came with delayed union of osteotomy site. 1 patient(4.5%) suffered non-union of fracture site. 2 patient (9%) developed ulnar nerve

paresthesia. 1 patient(4.5%) developed triceps muscle weakness.

Table 3: Comparison of complications in patients operated by TRAP and Olecranon osteotomy

Parameters	TRAP(n=28)	Olecranon osteotomy(n=22)
Ulnar nerve paresthesia	3	2
Triceps muscle weakness	2	1
Varus deformity	1	-
Incision site infection	2	-
Implant impingement	-	5
Delayed union	-	3
Non-union	-	1
Total	08	12

Discussion

The management of supracondylar fracture of humerus has progressed from absolute conservative management to open reduction and internal fixation and more recently towards total elbow arthroplasty. Improvement in instrumentation, techniques and increased expectation and need for good results by patients due to modern lifestyle, open reduction and internal fixation is gaining more popularity among surgeon's worldwide.

Olecranon osteotomy was found to be inferior in terms of range of elbow motion. An analysis of DASH and MEPS scores revealed better results in TRAP group patients.

The treatment of intra-articular humerus is mainly aimed at achievement of as much as possible anatomical fixation and functional mobility of joint in order to allow early full rehabilitation. Intra-operative exposure is the main requisite for intra-articular restoration articular

surface. Many approaches are considered for exposure, such as olecranon osteotomy, triceps splitting, and TRAP approach.

Olecranon osteotomy though provide better exposure than TRAP, nonunion, delayed union, requirement of implant to repair olecranon osteotomy leading to implant impingement and its removal are among common disadvantages. Rarely, damage to nerve supply of anconeus that participates in in dynamic stabilization of elbow joint may lead to elbow instability.

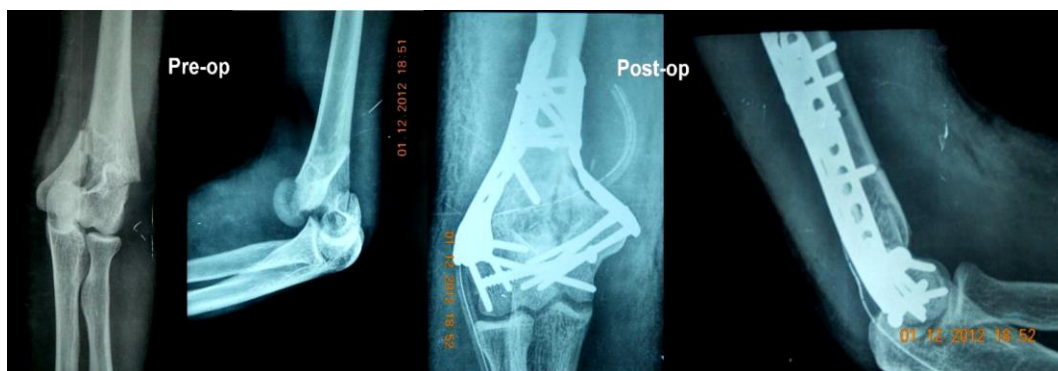In the study by Ozer et al, ROM in type C1 and CII (n=9, 82%) whose average was 116(range 95-140), and type CIII (n=2, 18%) fractures had an average range of motion of 85. In the study conducted by Pankaj et al, the average range of motion was 118(range 80-140). Range of motion in TRAP was found to be 110(range 85-135) which was far better than in olecranon osteotomy which was 87(range 65-110).

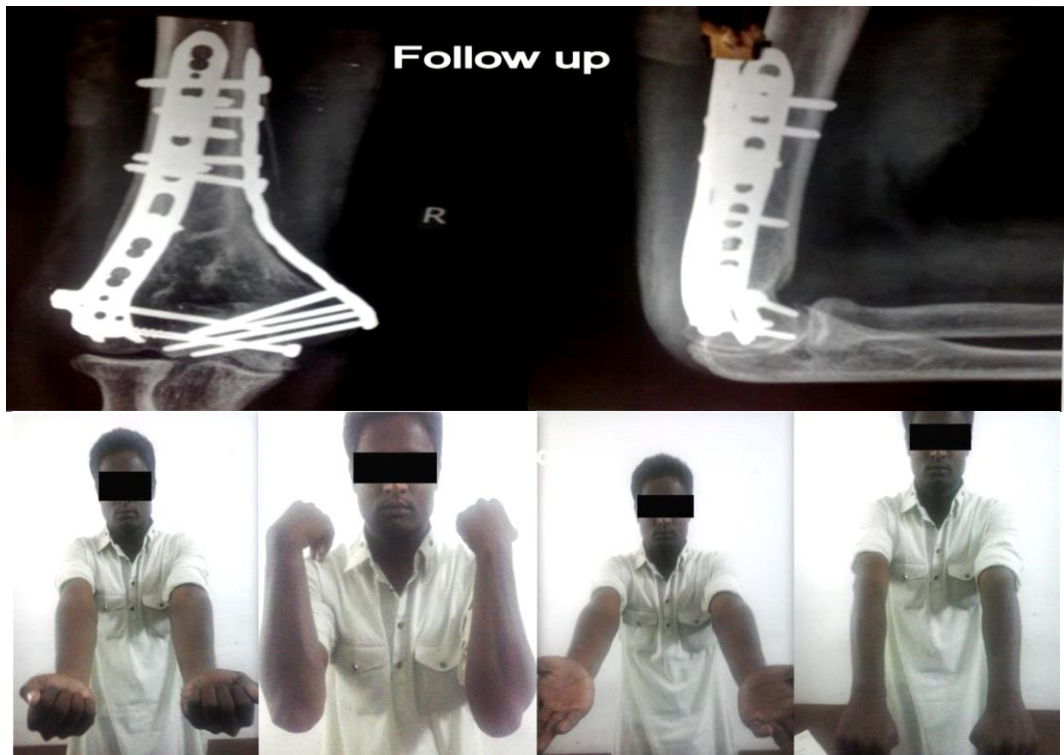
Implant impingement is a major complication after olecranon osteotomy which often leads to revision surgery. Incidence of implant removal is between 13-30%. Out of 94 patients in whom olecranon osteotomy has been done by Tak et al. all the patients who had unsatisfactory results were related to olecranon osteotomy (p=0.000, OR 103.2). In the our study, 22.7% of the patients in whom olecranon osteotomy repair was done needed implant removal. In contrast, no patient had a second surgery in the TRAP group.

Conclusion

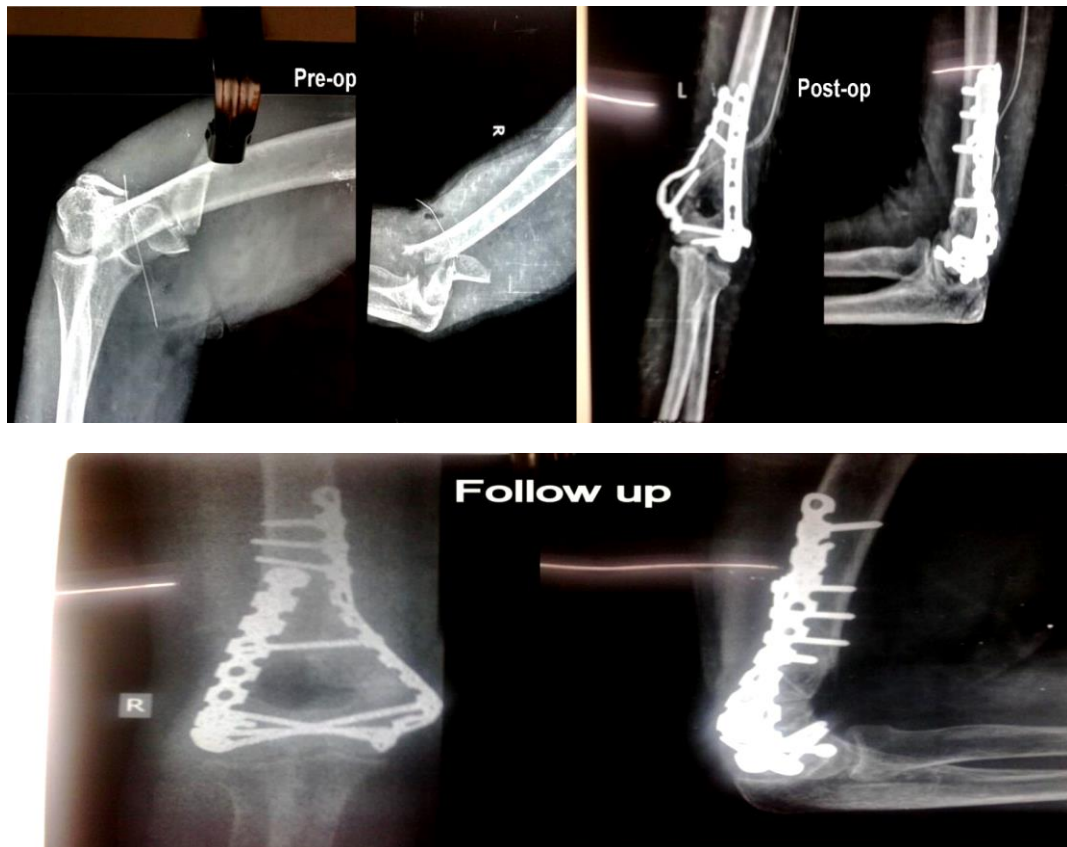
Elbow motion and post operative rehabilitation is much better in TRAP technique as compared to olecranon osteotomy. The conclusion from this study suggested that TRAP approach is good alternative approach in treatment of intra-articular distal end humerus/ supracondylar humerus fractures that reduces reoperations and complications rates.

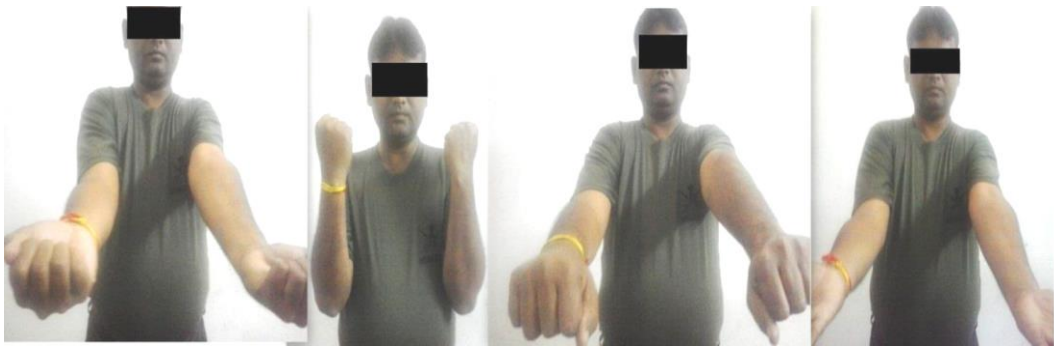Cases



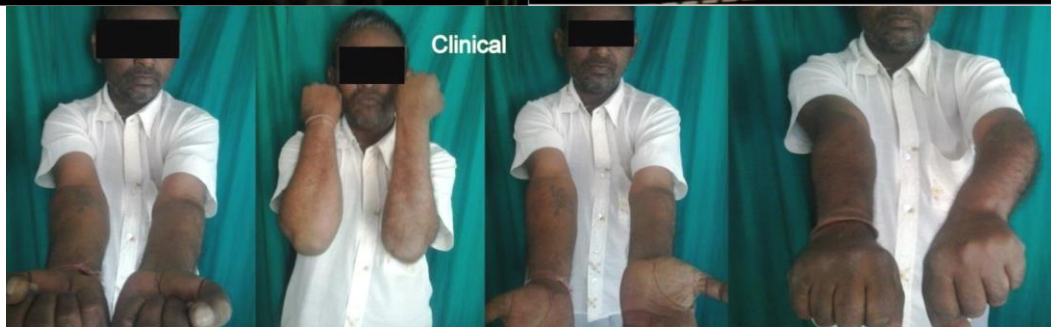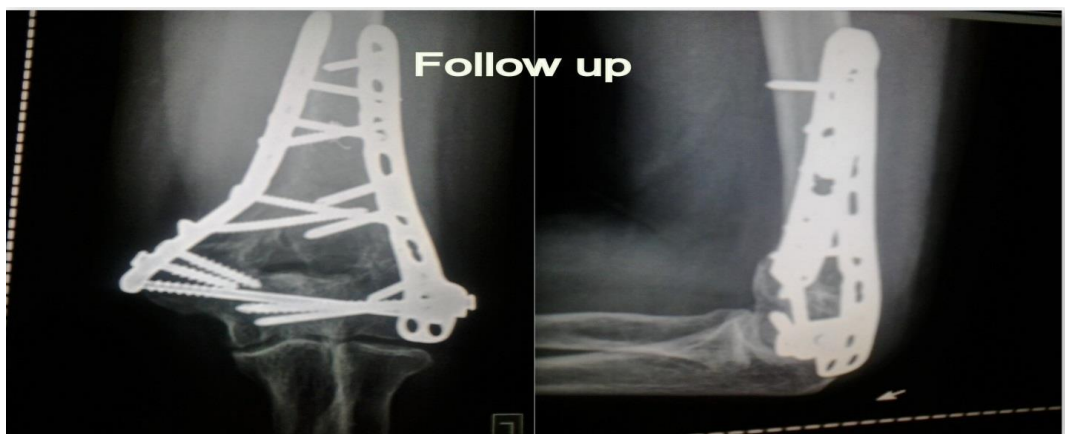

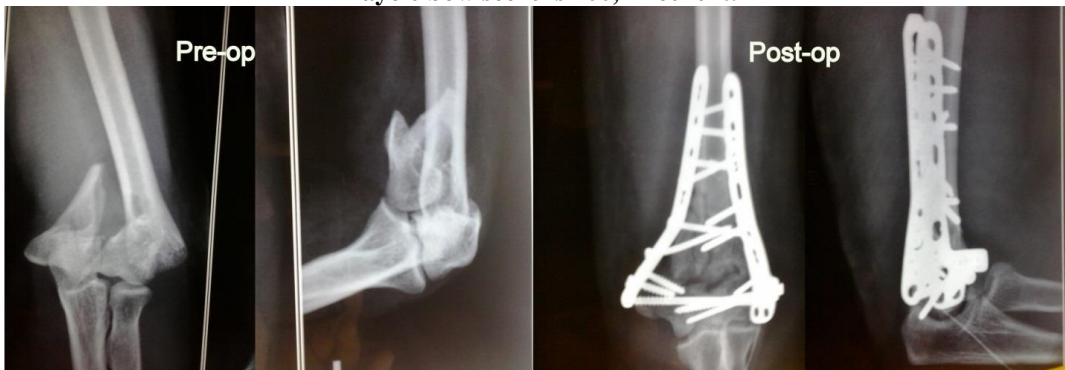
Case 1: 35 year old male patient having history of RTA.
Type C1 fracture treated with double plating by TRAP approach.
Mayo elbow score is 100, Excellent.





**Case 2: 42 year old male patient having history of fall down
Type C2 fracture treated with double plating by TRAP approach.
Mayo elbow score is 100, Excellent.**



**Case 3: 42 year old male patient having history of fall down
Type C2 fracture treated with double plating by TRAP approach.
Mayo elbow score is 95, Excellent.**

References

1. Gupta R, Khanchandani P. Intercondylar fractures of distal humerus in adults: a critical analysis of 55 cases. *Ijury* 2002;33:511-5.
2. Ozer H, Solak S, Turanlı S, Baltacı G, Colakkoglu T, Bolukbasi T, Intercondylar fracture of distal humerus treated with triceps-reflecting anconeus pedicle approach. *Arch orthop trauma* 2005;125:469-74.
3. Tak SR, Dar GN, Halwai MA, Kangoo KA, Mir BA. Outcome of olecranon osteotomy in the trans-olecranon approach of intra-articular fracture of the distal humerus. *Ulas Travma Acil Cerrahi Derg* 2009;15:565-70.
4. Pankaj A, Mallinath G, Malhotra R, Bhan S. Surgical management of intercondylar fractures of the humerus using triceps reflecting anconeus pedicle(TRAP) approach. *Indian J orthop*2007;41:219-27.