

Functional and radiological outcome of unstable intertrochanteric fractures treated by proximal femoral nail and dynamic hip screw

Kiran Kumar K.K.¹, Asif Hussain KS^{2,*}, Chandrasekhar P³, PVSSM Jagannadham⁴

¹Assistant Professor, ²Associate Professor, ³Professor & HOD, ⁴Junior Resident, Dept. of Orthopaedics, NIMS, Hyderabad

***Corresponding Author:**

Email: asifks@yahoo.com

Abstract

Introduction: Unstable intertrochanteric fractures are difficult to manage and the choice of implant is critical for fracture fixation. Operative management allows early rehabilitation and offers to the patient the best chances for functional recovery in trochanteric fractures. The purpose of this study is to compare the functional and radiological outcome of unstable intertrochanteric fractures treated with DHS and PFN.

Materials and Method: 50 unstable Inter-trochanteric hip fractures that were surgically treated between November 2015 and June 2016 at our institution were included in study. 25 patients were treated with DHS fixation and 25 patients were treated with PFN fixation. All surgeries were done on traction table and are followed up at regular intervals of 6 weeks, 10 weeks, 4months, 6 months and annually thereafter.

Results: The functional results are assessed with Harris Hip Score and we observed good or excellent results in 64% of DHS group and good or excellent results in 80% of PFN group. We observed no statistically significant difference between two groups in view of late & early complications and time to union. The mean follow up period was 13 months (range, 9 -16 months)

Conclusions: We observed significantly better functional outcome in PFN group for unstable inter-trochanteric fractures. In unstable fractures we observed total duration of surgery, blood loss and image intensifier exposure time to be significantly lower in PFN group. We concluded that PFN may be the better fixation device for most unstable inter-trochanteric fractures.

Keywords: Inter-trochanteric fractures, DHS, PFN

Introduction

Intertrochanteric fractures are one of the common fractures, usually seen in the elderly people especially with osteoporotic bones. They are usually due to simple fall¹ and are low energy injuries.

In elderly people Inter-trochanteric fractures constitute for approximately half of the hip fractures; out of them, more than 50% fractures are of unstable variety.^(2,3)

Hip fractures have a bimodal distribution of age. Approximately 97% occur in patients over 50 years of age (the incidence increases with age), and only 3% in patients under age of 50. In the latter group, they occur most commonly between 20 and 40 years of age, usually in men, and are due to high-energy trauma associated with sports and industrial and motor-vehicle accidents. Most of the hip fractures are sub trochanteric or basi cervical in the younger population. The unstable pattern occurs more commonly with increased age and with low bone mineral density.⁽⁴⁾

By 2025, the incidence of hip fractures is estimated to be doubled worldwide.⁽⁵⁾ Fractures sustained in the elderly are serious injuries, often occurring in the terminal years of life and they have a major impact on society, our health care system and cost of care.⁽⁷⁾ In fractures sustained in the younger age group, there appears to have socioeconomic problems, long lasting elimination from working process or even loss of job. Increased life expectancy which causes increase in the aged population and high energy trauma which victimizes more number of young adults are the leading

causes for increase in overall incidence of trochanteric fractures.⁽³⁾

Fractures of the hip in patients between 40 and 50 years of age usually occur in alcoholics or patients with multiple medical diseases, whose fractures are related to osteoporosis.^(5,6)

Watson-Jones⁽⁸⁾ states that “fractures through the intertrochanteric line of the upper end of the femur, and per trochanteric fractures, unite readily no matter what treatment is used because the broad fractured surfaces are richly supplied with blood and there is seldom wide displacement. But at the same time, unless suitable precautions are taken, the fracture may unite in a position of coxavara with shortening of the limb and limitation of hip movements. Moreover as this fracture occurs in the elderly patients the risks from prolonged immobility and recumbency arise. Thus treatment should be so planned as to encourage union without deformity, and at the same time allow early mobilization.

Safe and efficient restoration of mobility, minimizing the risk of medical complications, technical failure and to restore the patient to preoperative status is the goal of treatment of intertrochanteric fractures.⁽⁹⁾

In the early 1950's operative treatment for hip fractures was introduced with the expectation to improve functional outcome and to reduce complications associated with immobilization and prolonged bed rest.^(10,11) Since then a variety of different implants were used, they are either extramedullary or intramedullary.

DHS fixation has been shown to produce good results. However complications are frequently seen with unstable variety of intertrochanteric fractures.⁽¹²⁾

According to MAGIT and colleagues (2004)⁽¹³⁾ with Dynamic hip screw fixation the union rates were more than 95%. It is the standard of treatment for trochanteric femur fractures. The problem with these implants are high screw cut out from the femoral head and excess collapse at fracture site causing shortening of the limb and also reducing the lever arm of hip abductors, they also have increased incidence of intraoperative blood loss and needs extensive soft tissue dissection. They also stated that less invasive treatment of these fractures with intramedullary nail offered several potential advantages over dynamic hip screw like smaller incision, limited devascularisation, shorter operative time, less blood loss and also less wound complications.

The proximal femoral nail (PFN) has theoretical advantage over other devices in the treatment of trochanteric fractures as it is an intramedullary implant.⁽¹⁴⁾

The nails are load-sharing implants, whereas extra medullary devices are load-bearing. Proximal femoral nailing creates a shorter lever arm, which translates to a lower bending moment and a decreased rate of mechanical failure. The disadvantages are due to greater risk of jamming in the sliding mechanism and also stress risers at the tip of nail and distal locking bolts.⁽¹⁵⁾

Intramedullary implants had increased risk of intraoperative and postoperative femur fractures when compared with sliding hip screws.⁽¹⁶⁾

The increased fracture incidence is due to stress concentration at the tip of nail, stress risers at the distal locking bolt, and due to reaming of proximal femur to accommodate the wider proximal diameter of the nail.⁽¹⁷⁾

Data published so far confirm that PFN is a reliable implant, producing results similar to those obtained with the DHS for unstable trochanteric fractures. Various authors have however reported screw cut-out of the femoral head and a higher rate of intra-operative difficulties with the PFN.⁽¹⁸⁾

Complications were frequently noted in unstable intertrochanteric fractures treated with Dynamic hip screw; proximal femur nailing fixation is biomechanically stable construct. It reduces the moment arm between hip joint and implant,^(19,20) The aim of this study is comparison of the functional outcome and radiological outcome in patients who sustained unstable intertrochanteric fractures and were treated with DHS or PFN. (Load bearing vs Load sharing).

Materials and Method

We have included about 50 unstable Inter-trochanteric hip fractures that were treated surgically at our institution during period November 2015 and June 2016.

Half of them were treated with DHS fixation, and half were treated with PFN fixation:

Group 1 (25 patients): Fractures treated with DHS

Group 2 (25 patients): fractures treated with PFN

Study group	Sex(M/F)	Fracture type A2	Fracture type A3
DHS	12/13	17/25	8/25
PFN	20/5	17/25	8/25

According to AO/OTA classification⁽²¹⁾

A1 fractures are simple, two-part fractures,

A2 fractures have multiple fragments

A3 fractures includes reverse oblique and transverse fracture patterns

Inclusion Criteria

- Age: >18 yrs.
- Sex: Both sexes
- All types of unstable intertrochanteric fractures treated with proximal femoral nail or Dynamic hip screw
- No specific duration of illness.

Exclusion Criteria

Bilateral fractures (spontaneous)

Pathological fractures other than osteoporosis

Stable fractures (patients with intact posteromedial cortex)

Patients unfit for surgery

Ongoing chemotherapy or radiotherapy for malignancy

The following parameters were recorded for each patient:

- Sex,
- Age at the time of fracture,
- Fracture type (AO/OTA classification),
- Total operative time (the time that closed reduction was started to the time that the wound sutured),
- Blood loss
- Time to union (radiographical confirmation 3 cortices in two views), and
- Image intensifier exposure
- Complications (early and late).

All surgeries were performed on the traction table, after closed reduction which was confirmed with fluoroscopy in two different views.

Type of the operation was decided based on surgeon's preference and availability of the implant. The same trauma team evaluated each patient before surgery. In cases with comminution, PFN entry was through the fracture site. In the case of DHS, the guide wire was directly passed into the neck, and head of femur and lag screw was inserted, and the shaft was later fixed to head and neck with barrel plate. When the

lateral wall was found to be broken, surgeon preferred PFN as the implant of choice.

The average time duration from injury to surgery was 10.5 days (range: 1–24 days). The delay in surgery was due to the time lag between injury and hospitalization and between hospitalization and surgery. Delay in surgery was attributed to the poor general condition of the patient towards fitness for anesthesia and surgery and also associated injuries. It was ensured that every individual was in the best possible medical condition at the time of surgery.

Analysis of the clinical outcome for each group was done, intra operative, early (within a month after hip fracture fixation), and late complications (after the first month) were recorded. All were followed up at regular intervals of 6 weeks, 10 weeks, 4months, 6 months and yearly after that. Harris hip score was used for evaluating functional results [Table 1].

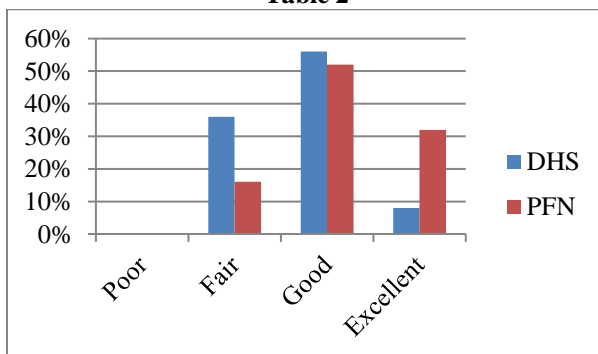
Table 1

Parameters studied	Grading of Harris	Hip score
Pain	<70	Poor
Limp		
Distance walked	71-79	Fair
Support		
Sitting	80-89	Good
Public transport		
Stairs	90-100	Excellent
Put on shoes		
Absence of deformity		
Range of motion		

Results

In our study, excellent results were observed in 2(8%)of patients in group 1 and 8(32%) in group 2. Good results were observed in 14(56%) in group 1, and 13(52%) in group 2. Fair results were 9(36%) in group 1 and 4(16%) in group 2[Table 2].

Table 2



Early complications that we noted were deep vein thrombosis, and superficial wound infection both were seen in DHS group. Intraoperatively there was a

mismatch between zig and distal locking bolt in about 7(28%) patients of the PFN group, and it was applied free hand. The incidence of wound infection was found to be lower with intramedullary implants. 8% in DHS vs 0% in PFN.

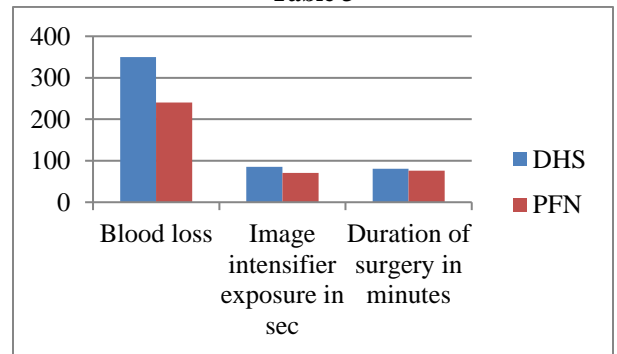
Non-union of trochanteric fracture is a rare entity, no case was found in our series of patients.

The mean blood loss was lower in the IM Nail group (240ml) when compared to the DHS group (350 ml), and it was not found to be statistically insignificant (P=0.14).

The screening time with the help of image intensifier was less in the cases that were operated by proximal femoral nail (PFN) as compared to cases that were operated by Dynamic hip screw (DHS) (71 sec vs 85 sec) it was statistically significant p value 0.04.

The average surgical time duration was less in the PFN group (81min vs 76 min) [Table 3] and it was found to be statistically significant p value of 0.01.

Table 3



We did not encounter any secondary femoral fracture in patients managed by proximal femoral nails though this is one of common complication reported other studies. The implant related complications were much lesser in the patients treated with Dynamic Hip Screw (DHS). The rate of union was similar in two groups. (PFN & DHS).

Discussion

Most of our patients were 50 years and above and in them domestic fall (fall at home), and trivial trauma was the main reason behind fracture, There was a male preponderance in our patients. The ratio of males to female was 2:1.

We had two cases of pathological fractures that were operated with PFN, one case had multiple myeloma, and other case had metastasis from carcinoma of the breast. Surgery in both the cases was palliative to alleviate pain as both the cases were in advanced stages of malignancy. Both the patients died few months after surgery and were not included in the study as the functional outcome could not be assessed. So to compare the functional outcome between two groups, pathological fractures were excluded.

In our study fractures on the left side was slightly higher than right. The majority of patients in present study series were operated within 10 days following admission to hospital (40/50). But in some patients (10/50) operative procedure was delayed due to medical problems (Hypertension and Diabetes) of patients. Average time lapse for surgery: 10.5 days. Amongst patients who had a delay in operative intervention eight patients came to hospital following 10 days of trauma. In patients with domestic fall 3 patients had distal radius fracture which were treated conservatively, 1 patient had proximal humerus fracture treated surgically with plating. 1 patient had olecranon fracture treated operatively with Tension band wiring. Majority (32%) of the patients were diabetic and hypertensive (16%) in our study. 2 cases operated by DHS had superficial wound infection at the suture site. This may be attributed to long duration of surgery because of difficult reduction & more soft tissue exposure, which is more in cases operated by DHS. In both the cases infection was treated by removal of skin sutures and antibiotics were continued. The wound healed by secondary intention. No incidence of anterior thigh pain was noted in our study. One case of Deep Vein Thrombosis was detected in the postoperative period in DHS group, which was treated with Anti-coagulants. While in those cases operated by Dynamic Hip Screw (DHS) we encountered 4 cases (16%) having difficulty in reduction. This was due to excessive comminution and displacement. There is no incidence of screw cut out or breakage of the implant noted in the follow-up period in our study. Varus angulation was noted in 2 operated cases in DHS group, due to the pull of the muscle the distal shaft fragment tends to migrate upwards thus resulting in Varus deformity. The other reason that patients had coxa vara deformity was due to inadequate reduction and failure to maintain neck shaft angle preoperatively. However Varus angulation was less than 10° and there was no incidence of screw cut out.

Conclusion

Trochanteric fractures constitute one of the commonest fractures encountered in elderly. Operative management allows early rehabilitation and offers the patient the best chances for functional recovery and is the treatment of choice for virtually all trochanteric fractures. Operative treatment with PFN requires shorter operation time, less image intensifier exposure. Hence from our study, PFN may be the better fixation device for most unstable intertrochanteric fractures.

References

1. Parker MJ, Pryor GA. Gamma versus DHS nailing for extracapsular femoral fractures: Meta-analysis of ten randomised trials. *Int Orthop*. 1996;20(3):163-168.
2. Robert BW, James Heckman D, Charles Court Brown M. Rockwood and Green's Fractures in Adults, 2(6),18271844.
3. David Lavelle G. Fractures and dislocations of the hip chapter-52 in Campbell's Operative Orthopaedics, eleventh edition. Vol-3, 3237-3308.
4. Koval KJ, Aharonoff GB, Rokito AS, Lyon T, Zuckerman JD. Pa-tients with femoral neck and intertrochanteric fractures: Are they the same? *Clin Orthop*.1996; 330:166-172.
5. Gullberg B, Johnell O, Kanis JA. World-wide projections for hip fracture. *Osteoporos Int* 1997;7(5):407-413.
6. Robinson CM, Court-Brown CM, McQueen MM, Christie J. Hip Fractures in Adults Younger than 50 Years of Age. *Clin Orthop Relat Res*. 1995 Mar;(312):238-46.
7. Frandsen PA, Kruse T. Hip Fractures in the County of Funen, Denmark. Implications of Demographic Aging and Changes in Incidence Rates. *Acta Orthop Scand* 1983;54:681.
8. Al-Yassari G, Langstaff RJ, Jones JW, Al-Lami M. The AO/ASIF. proximal femoral nail (PFN) for the treatment of unstable trochanteric femoral fracture. *Injury* 2002; 33 -395-399.
9. Sudhir S Babhulkar, Management of trochanteric fracture; *Indian journal of orthopaedics*, October 2006, Volume 40: number 4: p.210-218.
10. Schumpelick W, Jantzen PM: A new principle in the operative treatment of trochanteric fracture of the hip. *J Bone Joint Surg* 1988, 70-A:1297-303.
11. Pugh WL: A self adjusting nail plate for fractures about the hip joint. *J Bone Joint Surg* 1955, 37-A:1085-93.
12. Davis TR, Sher JL, Horsman A, Simpson M, Porter BB, Checketts RG: Intertrochanteric femoral fractures: mechanical failures after internal fixation. *J Bone Joint Surg Br* 1990, 72B:26-31.
13. Magit DP, Medvecky M, Baumgaertner MR, Intramedullary Nailing for the management of Intertrochanteric and Subtrochanteric Geriatric Fractures. *Tech orthop*.2004;19:153-62.
14. Saudan M, Lübbecke A, Sadowski C, et al: Peritrochanteric fractures: is there an advantage to an intramedullary nail? A randomized, prospective study of 206 patients comparing the dynamic hip screw and proximal femoral nail. *J Orthop Trauma* 2002; 16: 386 – 393.
15. Saudan M, Lübbecke A, Sadowski C, et al: Peritrochanteric fractures: is there an advantage to an intramedullary nail? A randomized, prospective study of 206 patients comparing the dynamic hip screw and proximal femoral nail. *J Orthop Trauma* 2002; 16: 386 – 393.
16. Adams CI, Robinson CM, Court-Brown CM, McQueen MM: Prospective randomized controlled trial of an intramedullary nail versus dynamic screw and plate for intertrochanteric fractures of the femur. *J Orthop Trauma* 2001, 15:394-400.
17. Bess RJ, Jolly SA: Comparison of compression hip screw and gamma nail for treatment of peritrochanteric fractures. *J South Orthop Assoc* 1997, 6:173-179.
18. Pajarinen J, Lindahl J, Michelsson O, et al: Peritrochanteric femoral fractures treated with a dynamic hip screw or a proximal femoral nail. A randomised study comparing post-operative rehabilitation. *J Bone Joint Surg Br* 2005;87:76–81.
19. 19.David A, Von Der Heyde D, Pommer A. Therapeutic possibilities in trochanteric fractures". *Orthopaede* 2000; 29(4):294-301.
20. Kish B, Sapir O, Carmel A, Regev A, Masrawa S. Full weight bearing after unstable per and subtrochanteric fracture using proximal femur nail. *J Bone Joint Surg (Br)* 2001; 83-B, III, 289.
21. Kenneth KJ, Joseph ZD. Hip fractures-A practical guide to management page, 191-252.