

## Role of MRI in detecting cruciate ligaments tears, confirmed subsequently with arthroscopy

Pawan Shaw<sup>1,\*</sup>, M. Rajasekhar<sup>2</sup>, Nilesh Gupta<sup>3</sup>

<sup>1</sup>DNB Resident, <sup>2</sup>Senior Consultant, Dept. of Orthopaedics, Ramkrishna Care Hospital, Raipur, <sup>3</sup>Consultant, Dept. of Radiology

**\*Corresponding Author:**

Email: pawanshaw24@gmail.com

### Abstract

**Introduction:** Due to its anatomical structure, its exposure to external forces and the functional demands placed on it, Knee Joint is one of the most commonly injured joints.

**Objective:** To observe the sensitivity and specificity of MRI in detecting cruciate ligaments tears, and confirmed with arthroscopy.

**Materials and Method:** It was conducted at Ramkrishna Care Hospital, Raipur. 67 patients with complaints of knee pain with history of knee injury between the age group of 15-60 years were selected for study.

**Results:** 61 had ACL tear on MRI out of which 58 showed similar results on arthroscopy. The sensitivity, specificity and accuracy for MRI for ACL came out to be 100%, 66.67% and 95.52% respectively. Similarly out of 2 patients diagnosed with PCL tear on MRI examination only 1 had positive result arthroscopically giving sensitivity of 50%, specificity of 90% and accuracy of 98.5%.

**Conclusion:** Magnetic Resonance Imaging has highly accurate for pre-operative diagnosis of ligamentous injuries of knee joint and can be used as a screening tool before arthroscopic examination.

**Keywords:** Knee Joint, MRI, Arthroscopy, Cruciate ligaments, Sensitivity

### Introduction

Largest and complex joint of the body is Knee joint which consist of two condylar joint between the corresponding condyles of femur and tibia and a sellar joint between patella and femur.<sup>(1)</sup>

Joint stability is highly dependent on its supporting ligamentous structures, therefore injuries of ligaments is extremely common, which vary from simple ligamentous strain to complex injuries involving ligamentous disruption and associated fractures.<sup>(2)</sup>

Stabilisers of the knee is cruciate ligaments which work as both forward and backward motion of tibia on femur and provide an axis around which rotatory movement are assisted.<sup>(3)</sup>

Due to road traffic accidents or sports related knee joint injuries constitute a large proportion of musculoskeletal trauma encountered in emergency, so a detailed clinical examination with numerous stability test provide 70% accuracy in diagnosing pathology of joint.<sup>(4,5,6)</sup> However in acute stage, due to pain, clinical tests may not be appropriate, so MRI is preferred choice of investigation.

MRI is non-invasive and is less sensitive for the anterior cruciate ligaments injuries. In case of medial collateral ligament injury, mild degrees of injury correlate well; imaging is less accurate in grading more severe injuries.<sup>(7)</sup> With the comparison with other diagnostic methods, MRI has the advantage of demonstrating the cartilages, bones, soft tissues and ligaments directly in detail in different planes.<sup>(8)</sup>

Arthroscopy is considered as gold standard among the investigative modalities<sup>(9,10)</sup> for diagnosis of traumatic intra-articular knee lesions, however it is an

invasive procedure requiring hospitalisation and anaesthesia.<sup>(11,12)</sup>

The purpose of this study is to observe the role of MRI in detecting cruciate ligaments tears, confirmed subsequently with arthroscopy.

### Materials and Method

This prospective, observational study was conducted at Ramkrishna Care Hospital, Raipur, Chhattisgarh. Consent was taken from all study population. We studied 67 patients with complaints of knee pain or instability/ locking/ giving away sensation with history of knee injury between the age group of 15-60 years over a period of 24 months (November 2014 to October 2016).

The study participants underwent MR Imaging of the knee followed by arthroscopy of knee when they present with history of suspected internal derangement of knee joint.

All the patients underwent Arthroscopy and the arthroscopic findings were recorded. There was an average of 4-6 weeks of duration between time of injury and MRI taken. Surgeon was unaware of MRI findings in all the cases prior to arthroscopy. Subsequently the findings of MRI and Arthroscopy were compared and analyzed.

SPSS Version 19.0 for analysis of data and Microsoft Word and Excel was used. Sensitivity, Specificity, Positive predictive value and negative predictive value was used for comparison between MRI and Arthroscopy.

**Results**

All patients (67) were between the age 15yr - 60yr with mean age of 29.25 years. Among the 67 patients 56(83.58%) were male and 11(16.42%) were female.

On basis of MRI and Arthroscopic findings out of the 67 patients, 61 (91.04%) patients showed ACL tear on MRI however on arthroscopy only 58 (86.57%) patient showed ACL tear. Out of 2(2.99%) patients with PCL tear only 1(1.49%) showed positive result on MRI.

**Table 1: Structure injured in MRI and arthroscopy**

MRI Arthroscopy		
ACL	61	58
PCL	1	2

Among 61 patients showing positive findings in MRI 58 showed ACL tear in arthroscopy while 3 were false positive. 6 patients who showed intact ACL in MRI had same result arthroscopically.

**Table 2: Correlation between MRI and arthroscopic findings for ACL tear**

ACL	Arthroscopy		
	+ve	-ve	Total
MRI +ve	58	3	61
- ve	0	6	6
Total	58	9	67

MRI showed 100% sensitivity and negative predictive value for ACL tear while specificity was 66.67% and accuracy of 95.52% with positive predictive value of 95.08%.

**Table 3: Correlation between MRI and arthroscopic findings for ACL tear**

ACL Tear	Value (%)
Sensitivity	100
Specificity	66.67
Positive Predictive Value	95.08
Negative Predictive Value	100
Accuracy	95.52

Out of 2 patients showing positive findings in Arthroscopy only 1 showed positive findings in MRI. 66 patients who showed intact PCL in MRI had 65 patients with true negative result while only 1 was false negative.

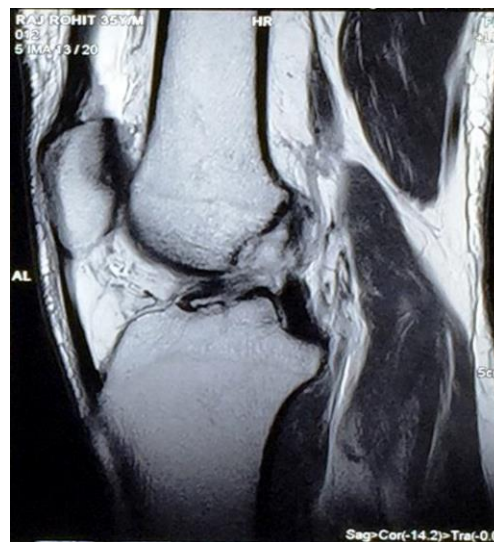
**Table 4: Correlation of MRI and arthroscopic findings for PCL tear**

PCL	Arthroscopy		
+ve		-ve	Total
MRI +ve	1	0	1
-ve	1	65	66
Total	2	65	67

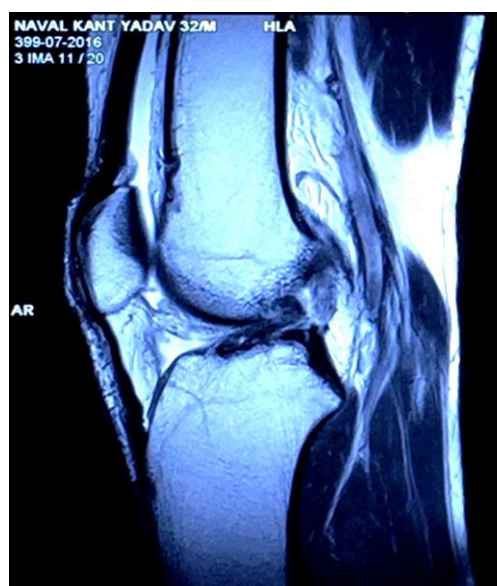
MRI showed 100% positive predictive value for PCL tear while negative predictive value was 98.48%, along with sensitivity of 50% with specificity of 100% and accuracy of 98.51%.

**Table 5: Correlation between MRI and arthroscopic findings for PCL tear**

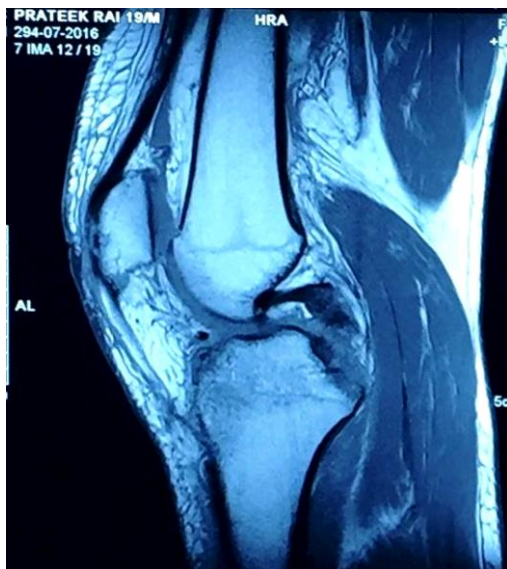PCL Tear	(%)
Sensitivity	50
Specificity	100
Positive Predictive Value	100
Negative Predictive Value	98.48
Accuracy	98.51



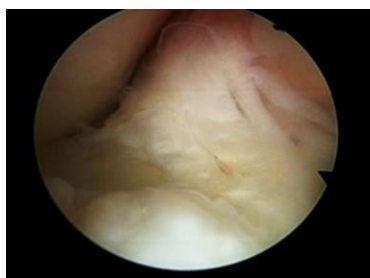**Fig. 1: MRI in sagittal section showing mid substance tear of ACL. Note the increase in signal (hyperintense) within the course of ACL**



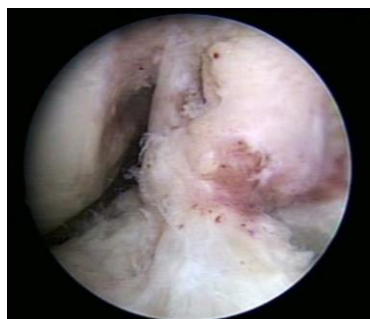**Fig. 2: MRI in sagittal section showing tear of ACL from femoral attachment. Note the increase in signal (hyperintense) at femoral end**



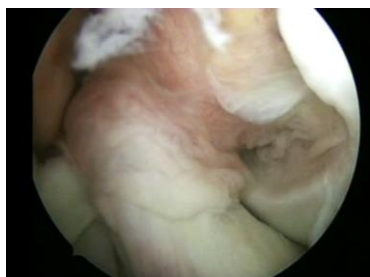
**Fig. 3:** Sagittal section of MRI showing avulsion of PCL from tibial attachment. Note the discontinuity of the hypointense curving band at the tibial end



**Fig. 4:** Complete Mid-substance tear of ACL with ACL remnant stump on tibial attachment



**Fig. 5:** Mid substance tear of ACL



**Fig. 6:** Complete ACL tear from femoral attachment

## Discussion

In case of ACL tears diagnostic accuracy of MRI examination came out to be 95.52% with sensitivity of 100% and specificity of 66.67%. There were 3 false positive interpretation of ACL tear on MRI compared with arthroscopy. These might be explained by the presence of partial tears which may be missed on arthroscopies. Similar study conducted by Singh J P et. al<sup>(13)</sup> showed accuracy of 98.84% with sensitivity of 98.72% and specificity of 98.94%. A study done by Riel et. al<sup>(14)</sup> found similar results with accuracy of 97% and sensitivity and specificity of 98% both. Gupta MK et al<sup>(15)</sup> conducted identical studies on 40 patients with knee injuries with comparable objectives found accuracy of MRI for ACL tear to be 90% with sensitivity of 91.3% and specificity of 88.2%. A study by Subhash R Puri<sup>(16)</sup> on co-relation between MRI and arthroscopic findings in knee injuries, found accuracy of MRI examination for ACL tear to be 96% with sensitivity of 81% and specificity of 96%. Similarly Ali Akbar Jah et. al<sup>(17)</sup> observed MRI accuracy for ACL tear to be 88.5 % and sensitivity and specificity of 78.3% and 95.7% respectively. S Gupta<sup>(18)</sup> found MRI accuracy to be 90% with sensitivity of 88.89% and specificity of 98.48%. Our MRI diagnostic accuracy and sensitivity in ACL tear is similar to that reported by above mentioned studies while specificity has been slightly inferior which might be because of the degenerative changes that tend to increase the signal intensity.

Diagnostic accuracy of MRI for PCL tear to be 98.51% with sensitivity of 50% and specificity of 100%. Oei et al<sup>(19)</sup> conducted a meta-analysis by combining 29 studies from 1991 - 2000 found sensitivity of 91% with specificity of 99%. Riel et. al<sup>(14)</sup> conducted similar results with accuracy, sensitivity and specificity all to be 100%. Gupta MK<sup>(15)</sup> found accuracy of 95% with sensitivity of 98.2% and specificity of 96.1% for MRI examination of PCL tear. S Gupta et al<sup>(18)</sup> found MRI accuracy of 100% for PCL tear, the sensitivity and specificity observed by S Gupta et al<sup>(18)</sup> for PCL injury was also 100%. Our result as mentioned above has comparable accuracy and specificity for PCL tear while sensitivity was found to be low which may be due to less number of positive cases.

## Conclusion

It was concluded that MRI has high accuracy in diagnosing cruciate ligament injuries. This makes it most appropriate screening tool for therapeutic arthroscopy. The sensitivity for Anterior Cruciate Ligament tear is higher as compared to PCL.

## References

1. Williams, Peter L, Roger W. Arthrology; In Williams and Peter L editors, Gray's Anatomy, 36th edition. Edinburgh: Churchill Livingstone; 1986. P. 482.

2. Li DK, Adams ME, McConkey JP. Magnetic resonance imaging of the ligaments and menisci of the knee. *Radiol Clin North Am.* 1986;24(2):209-27.
3. Robert HM, Frederick MA, Knee Injuries. In: Canale TS, Beatty JH, editors. *Campbell's Operative Orthopaedics*, 11th edition Volume 3. Philadelphia: Mosby Elsevier; 2008; p 2410.
4. Terry GC, Tagert BE, Young MJ. Reliability of clinical assessment in predicting the cause of internal derangements of knee. *Arthroscopy.* 1995;11(5):568-76.
5. Abdon P, Arnbjornsson AH, Egund N, Lindstrand A, Odenbring S, Pettersson H. Lateral meniscal lesions in patients with clinically suspected medial lesions, *Acta Orthop Scand.* 1989;60(4):453-6.
6. Munk B, Madsen F, Lundrof E, Staunstrup H, Schmidt SA, Bolvig L et al. Clinical magnetic resonance imaging and arthroscopic findings in knees: a comparative prospective study of meniscus, anterior cruciate ligament and cartilage lesions. *Arthroscopy.* 1998;14(2):171-5.
7. Witte HD. Magnetic Resonance Imaging in Orthopaedics. In: Canale TS, Beatty J, editors. *Campbell's Operative Orthopaedics*. 11th edition Volume 1. Philadelphia: Mosby Elsevier; 2008. p. 137-40.
8. Robert HM, Frederick MA, Knee Injuries. In: Canale TS, Beatty J, editors. *Campbell's Operative Orthopaedics*, 11th edition Volume 3. Philadelphia: Mosby Elsevier; 2008. p. 2416-7.
9. Crawford R, Walley G, Bridgman S, Maffulli N. Magnetic resonance imaging versus arthroscopy in the diagnosis of knee pathology, concentrating on meniscal lesions and ACL tears: a systemic review. *Br Med Bull* 2007;84:5-23.
10. Kim SJ, Shin SJ, Koo TY. Arch type pathologic suprapatellar plica. *Arthroscopy.* 2001;17(5):536-8.
11. Piziali RL, Seering WP, Nagel DA, Schurman DJ. The function of the primary ligaments of the knee in anterior-posterior and medial-lateral motions. *J Biomech* 1980;13(9):777-84.
12. Terry GC, Target BE, Young MJ. Reliability of the clinical assessment in predicting the cause of internal derangements of the knee. *Arthroscopy.* 1995;11(5):568-76.
13. Singh JP, Garg L, Shrimali R, Setia V, Gupta V. MR Imaging of knee with arthroscopic correlation in twisting injuries. *Indian J Radiol Imaging.* 2004;14(1):33-40.
14. Riel KA, Reinisch M, Kersting SB, Hof N, Merl T. 0.2-Tesla magnetic resonance imaging of internal lesions of the knee joint: a prospective arthroscopically controlled clinical study. *Knee Surg Sports Traumatol Arthrosc.* 1999;7(1):37-41.
15. Gupta MK, Rauniyar MK, Karn NK, Sah PL, Dhungel K, Ahmad K, MRI evaluation of Knee injury with arthroscopic correlation. *J Nepal Health Res Council.* 2014;12(26):63-7.
16. Puri SR, Biswas SK, Salgia A, Sanghi S, Aggarwal T, Patel P. Study of correlation between clinical, magnetic resonance imaging, and arthroscopic findings in meniscal and anterior cruciate ligament injuries. *Med J DY Patil Univ* 2013;6(3):263-6.
17. Esmaili Jah AA, Keyhani S, Zarei R, Moghaddam AK. Accuracy of MRI in comparison with clinical and arthroscopic findings in ligamentous and meniscal injuries of the knee. *Acta Orthop Belg.* 2005;71(2):189-96.
18. S Gupta, R Sharma, A Sachar, Y Saini, N Saini. Comparison of Clinical Examination, MRI and Arthroscopy In Knee Injuries. *The Internet J Orthop Surg.* 2012;19(3):1-6.
19. Oei EH, Nikken JJ, Verstijnen AC, Ginai AZ, Myriam HMG. MR Imaging of the menisci and cruciate ligaments: a systematic review. *Radiology.* 2003;226(3):837-48.