

Uncommon dwelling for a common swelling – Myositis ossificans of the foot

Shyamasunder Bhat N.¹, Nishanth Ampar^{2,*}, Sourab Shetty³

¹Professor, ²Assistant Professor, ³Senior Resident, Dept. of Orthopaedics, Kasturba Medical College, Manipal University, Manipal

***Corresponding Author:**

Email: ortho.dr.nishanth@gmail.com

Abstract

The benign swellings in the foot and ankle are very rare in occurrence when compared to the other regions of the body and they may mimic malignant tumours, thereby being a diagnostic and therapeutic challenge. Myositis ossificans is one such lesion which commonly occurs around large joints, can occur very rarely in the foot and mimic a malignant lesion both clinically and on histopathological studies in the early stages of the disease.

A 30-year-old male presented with bony swelling on the medial aspect of the heel which was insidious in onset with gradual progression. There was no antecedent history of trauma. A calcified mass on the medial aspect of the calcaneum was seen on radiographs. Computed tomography images showed mineralisation indenting on the medial aspect of the calcaneum. Magnetic resonance images reported calcified mass in the quadratus plantae muscle encasing the Tibialis posterior, Posterior tibial artery and nerve, Flexor hallucis longus and Flexor digitorum longus. Excision biopsy confirmed the diagnosis. Hence an unusual site of presentation of a commonly presented mass is reported here.

Keywords: Myositis ossificans of foot, Benign swelling of foot, pseudo-malignant swelling

Introduction

Myositis ossificans is a benign muscular lesion that is frequently reported in the orthopaedic literature but is extremely of rare occurrence in the foot.⁽¹⁾ It can easily mimic or mislead clinician as malignant or pseudo malignant lesions of the foot.

Traumatic myositis ossificans circumscripta accounts for about 60% of the cases. It is a non-neoplastic heterotopic bone formation associated with a history of single major episode of trauma, or repetitive episodes of micro-trauma.⁽¹⁾ However very rarely they can present without any history of trauma, where they will be associated with aetiologies such as chronic infections, severe burns, poliomyelitis and neuromuscular disorders and are known as paraosteoarthritis.⁽¹⁾

Lesions are classified as extra-osseous (within muscle and without direct connection to bone), periosteal (discrete bone attached to the underlying bone), and paraosteal (most often found within muscle against the shaft of a long bone).⁽²⁾

Case Report

A 30-year-old male presented with bony swelling on the medial aspect of the left foot which was insidious in onset. Few weeks prior to presentation to us he had started developing pain and numbness on the medial aspect of the foot. Physical examination revealed a bony swelling of size 5x2x2 cm in size. The mass was not attached to the skin and seemed embedded in the intrinsic musculature. The patient did not have any history of antecedent trauma to the affected area.

The radiographs showed large calcified mass which was denser in the centre than the periphery (Fig.

1). Computed tomography images showed a mineralised mass indenting into the medial aspect of the left calcaneum (Fig. 2). Magnetic resonance images showed a calcified mass in the quadratus plantae muscle encasing the Tibialis posterior, Posterior tibial artery and nerve, Flexor hallucis longus and Flexor digitorum longus. The mass was seen to be scalloping on the medial aspect of calcaneum (Fig. 3). On biochemical evaluation, our patient had normal levels of serum PTH, calcium and phosphorus with no evidence of any underlying metabolic disorder.

Since it was well formed and capsulated, an excision biopsy was planned. Intra-operatively a hard-bony mass was found to be attached to the calcaneal periosteum on the medial side encasing tibialis posterior, posterior tibial artery and nerve and flexor hallucis longus tendon (Fig. 4). These structures had to be sectioned to excise the swelling as a single mass. The posterior tibial nerve and flexor hallucis longus tendon were repaired. The posterior tibial artery was ligated.

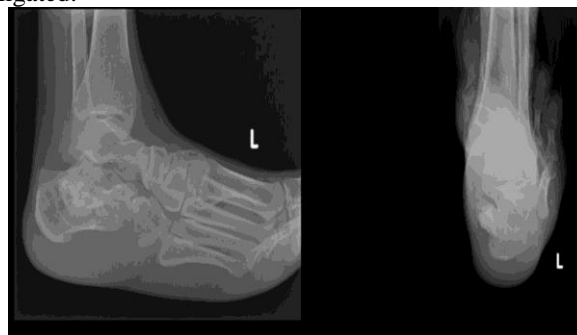

Fig. 1: X-ray images showing focal calcific lesion noted on the medial aspect of the left calcaneum with scalloping of the calcaneum

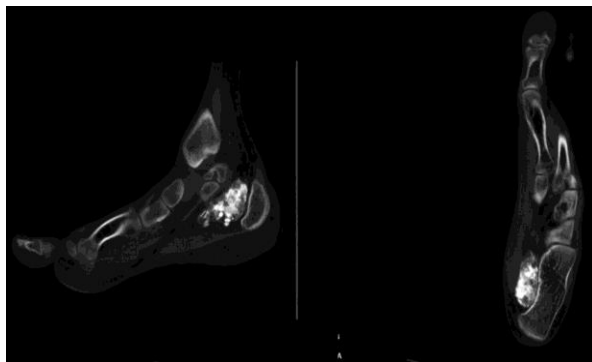


Fig. 2: Computerised tomography images showing a large ovoid calcified mass noted in the soft tissue of medial aspect of left calcaneum with scalloping of the medial margin

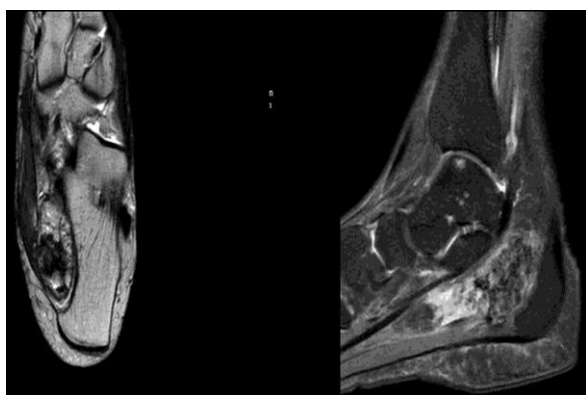


Fig. 3: Magnetic resonance images showing calcified mass noted in the Quadratus plantae muscle. No focal lesions or joint effusion noted

Post operatively the patient had numbness on the medial aspect of the foot which improved during the subsequent follow-up.

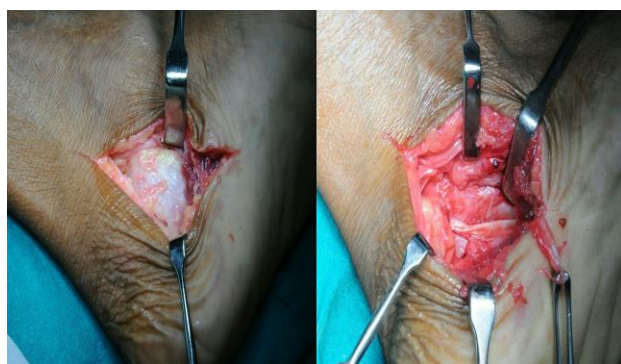


Fig. 4: Incision on the medial aspect showing the mass encapsulating the posterior tibial artery and nerve, tibialis posterior, flexor hallucis longus and quadratus plantae muscle

Macroscopically, the mass was greyish white, ovoid measuring 5x3x3 centimetres in its largest diameters. Upon sectioning, it was made of osseous tissue (Fig. 5). Microscopically sections showed benign

lesion with a zonal phenomenon of maturation showing central hypercellular area composed of fibroblasts and myofibroblasts surrounded by osteoid and reactive fibrous areas. Focally, osteoid showed mineralisation and peripheral shell of organised bony trabeculae with fibrofatty tissue and new bone formation (Fig. 6).

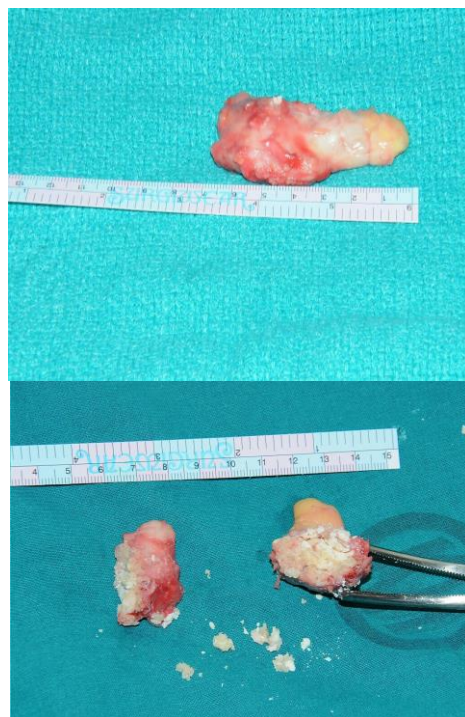

Fig. 5: Excised mass measuring 5x3x3 cm. Sectioned mass showing osseous tissue

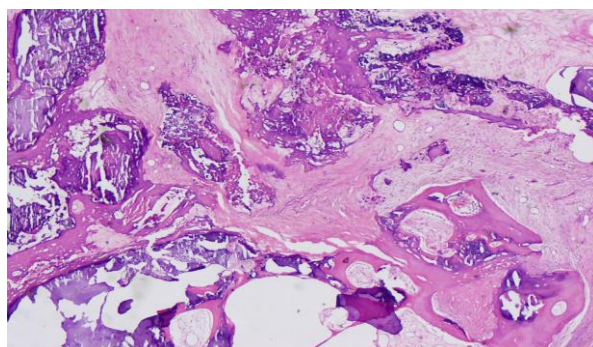


Fig. 6: Microscopic section of the specimen showed central hyper cellular area surrounded by osteoid and reactive fibrous tissue. The osteoid showed mineralisation and peripheral shell of organised bony trabeculae with fibro fatty tissue and new bone formation

Discussion

The Foot is a rare and unusual site for myositis ossificans.⁽¹⁾ Myositis ossificans can easily mimic an aggressive benign lesion or a malignant lesion due to its presentation and progression of symptoms. Depending on the stage of the disease process, there are clinical,

radiographic, and histological similarities to neoplasms such as osteosarcoma. In acute cases, due to the aggressive onset and rapid progression of growth and symptoms, these lesions tend to mimic a malignant tumour.⁽³⁾

The features on a plain radiograph make myositis ossificans difficult to distinguish from a malignancy as initial radiographic changes are seen in approximately 2 to 3 weeks as increased soft tissue density. Flocculent densities of calcification and ossification occur in 6 to 8 weeks and then encyst and mature in 5 to 6 months. The most common differential diagnoses include extra-skeletal sarcoma, parosteal or surface osteosarcoma, and fibrosarcoma because the radiographic features may be like any of these conditions at some point in time during its progression.⁽⁴⁾ The clear band of separation between neoplastic and normal bone is very suggestive of a benign lesion but may be difficult to see on plain radiographs. Also, aggressive malignant osseous tumours commonly tend to ossify at the centre rather than at the periphery.⁽³⁾

CT scans and magnetic resonance imaging helps in increasing the accuracy of the diagnosis of these lesions.⁽⁵⁾

Biopsies from the lesion during early stages, when the lesion has not completely matured, can give a picture of malignancy.⁽⁶⁾ Fine needle aspiration cytology has no role to play in the diagnosis as it could further add on to the dilemma in diagnosis if only the core of the mass is sampled which shows increased mitotic activity.⁽⁷⁾

Another condition to be kept in mind is tumour calcinosis which is a rare form of extrasosseous calcification occurring mainly in the peri-articular soft tissue regions of major joints as painless, firm, and mobile masses. It commonly involves the hip, shoulders, and elbows. Hands, feet, scalp, and eyelids are rarely involved.⁽⁸⁾ Tumour calcinosis can be ruled out by careful examination, radiological investigations and laboratory findings.⁽⁹⁾

Conclusion

Myositis ossificans tends to regress in size and becomes asymptomatic in due course of time despite its aggressive growth in the early stages. Despite its abnormal location such as in the foot and its features mimicking malignancy such as progressive swelling, pain, and pressure effect on the neighbouring bone, tendon and nerves, as was in our patient, the importance of watchful inactivity in the early stages should not be neglected. Surgical excision is usually sufficient for definitive management.

References

1. Kaminsky SL, Corcoran D, Chubb WF *et al.* Myositis ossificans: pedal manifestations. *J Foot Surg* 1992;31(2):173.
2. Gilmer WS, Anderson LD. Reactions of soft somatic tissue which may progress to bone formation.

3. Circumscribed (traumatic) myositis ossificans. *South Med J* 1959;52:1432.
3. Schutte HE, Van der Heul RO. Pseudomalignant, nonneoplastic osseous soft-tissue tumours of the hand and foot. *Radiology* 1990;176:149.
4. Nuovo MA, Norman A, Chumas J *Et al.* Myositis ossificans with atypical clinical, radiologic, or pathologic findings: A review of 23 cases. *Skeletal Radiol* 1992;21:87.
5. Cicchinelli LD, Juan MGS, Testa JA. Benign osseous tumour of soft tissue. In: McGlamry's Comprehensive Textbook of Foot and Ankle Surgery. Lippincott Williams and Wilkins 4th edition 1997;19:114-19.
6. Barea FL, Peralto JLR, Lopez JG *et al.* Case Report 694. *Skeletal Radiol* 1991;20:539.
7. Rooser B, Herrlin K, Rydholm A *et al.* Pseudomalignant myositis ossificans clinical, radiologic and cytologic diagnosis in 5 cases. *Acta Orthop Scand* 1989;60(4):457.
8. Mohamed S, Jong-Hun J, Weon-Yoo K. Tumoral calcinosis of the foot with unusual presentation in an 11-year-old boy: a case report and review of the literature. *J Postgrad Med* 2007;53:247-49.
9. Fathi I, Sakr M. Review of tumoral calcinosis: a rare clinico-pathological entity. *World J Clin Cases* 2014;2:409-14.