

Functional outcomes of the stable elastic intramedullary nailing for the fractures of femur in children

Sabary Vaasan L¹, Raju Karuppal^{2,*}, Sandhya Somasundaran³

¹Senior Resident, ²Additional Professor, ³Assitant Professor, ^{1,2}Dept. of Orthopaedics, ³Dept. of Ophthalmology
Govt. Medical College, Kozhikode, Kerala

***Corresponding Author:**

Email: drrajuortho@rediffmail.com

Abstract

Introduction: In current scenario, various operative procedures such as submuscular plating, spica casting, external fixation, intramedullary nailing etc available for children having femoral shaft fractures. We aimed to use titanium elastic nails for treating diaphyseal femoral fractures in children, considering the limited evidence of this technique. Our study focused on the efficacy, safety, average length of hospital stay and complications of this method.

Materials & Methods: We recruited 20 patients aged 3-13 years with fracture shaft of femur and were treated with stable elastic intramedullary nailing with titanium elastic nails at Government Medical College, Kozhikode from February 2014 to January 2015. Follow ups were carried out at 6, 12 and 24 weeks and there after every 2 months till the fracture union was confirmed.

Result: Out of 20 patents, 17 fractures were closely reduced & fixed and in 3 cases, open reduction was done. All the fractures united between 7-12 weeks, with average time of union being 8.3 weeks. All patients had good range of movements except 3 patients who had nail protrusion. The average duration of hospital stay was 7.3 days. Regarding the complications of this technique, limb length discrepancy was the most common complication.

Conclusion: It was observed that Elastic Stable Intramedullary Nailing (ESIN) technique is an ideal method for treatment of pediatric femoral shaft fractures. It gives elastic mobility promoting rapid union at fracture site and stability which is ideal for early mobilization. It also has lower complication rate, permits early return to school when compared with other methods of treatment.

Keywords: Diaphyseal Femoral Fractures; Pediatric Femoral Shaft Fractures; Elastic Stable Intramedullary Nailing.

Introduction

Over the past 20 years, there has been a dramatic and sustained trend towards the operative stabilization of femoral shaft fractures in school-aged children using external fixator, sub muscular standard compression plates, intramedullary locking nailing and elastic stable intramedullary nails (ESIN).⁽¹⁾ Although titanium elastic nails have been used in Europe for two decades and stainless-steel ender nails have been used worldwide for even longer, there is surge in use of titanium elastic nails in recent times despite the scarcity of studies.

Considering the limited evidence for supporting treatment with titanium elastic nails, we intended a prospective study on evaluating this method of treating diaphyseal femoral fractures in children with ESIN. Our study focused on the efficacy, safety, average length of hospital stay and complications of this method.

Materials & Methods

In this prospective analytical study, a total of 20 patients aged 3-13 years with fracture shaft of femur were included. All patients were treated with elastic stable intramedullary nailing (ESIN) technique with Titanium elastic Nails at Government Medical College, Kozhikode from February 2014 to January 2015. Their

data were collected prospectively and the study was approved by the ethical committee.

Children and adolescents aged between 3 to 13 years were included in this study. We excluded patients with neuromuscular disease (cerebral palsy or myelomeningocele), metabolic disorder, pathological fracture, head injury and polytrauma.

Pre-operative and post-operative evaluation

Pre-operative: As soon as patient brought to our accident and emergency room, patient's airway, breathing and circulation were assessed. Then a complete survey was carried out to rule out other injuries. Plain X-ray of femur, both AP and lateral views including both hip and knee joints were taken. Limb was rested in a Thomas splint. Relevant pre-operative investigations were taken. Through pre-anesthetic checkup was done by the anesthetist before surgery for all patients. Injection Tetanus toxoid (if appropriate booster dose not given) and one dose of parenteral antibiotic (Inj. Cefuroxime IV after test dose) were given. The detailed consent for surgery had been taken in all cases. All were underwent fixation with ESIN technique with titanium elastic nails under image intensifier on the same day itself (Fig. 1).

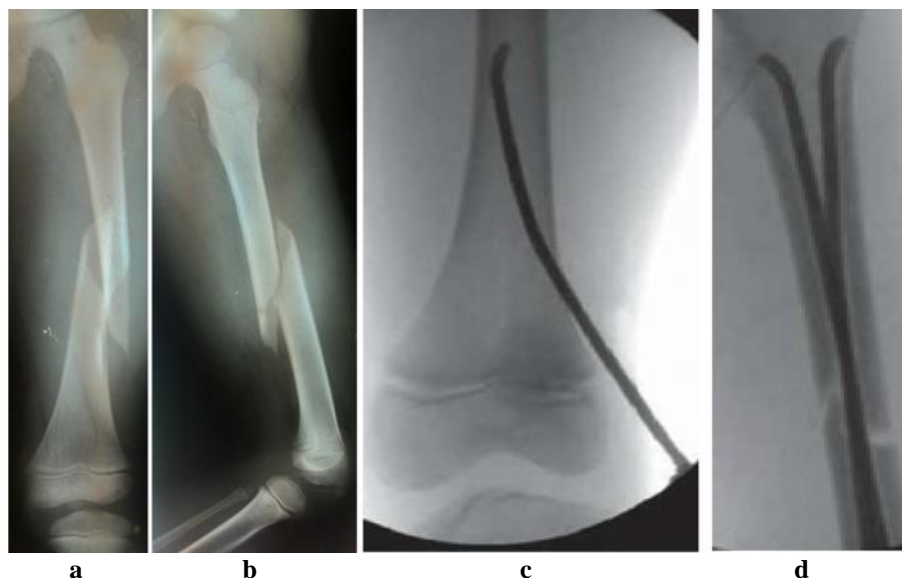


Fig. 1: a & b. X-ray of spiral Fracture shaft of femur AP and Lateral view; c. Advance the nail through the drilled entry hole; d. Both nails are advanced after the reduction that nail.

Postoperatively: Operated limb was immobilized if needed. Patients were started on static quadriceps exercises as soon as the pain subsided. After 2 days, the range of motion exercises were started, partial weight bearing was started after visible callus seen. With radiological evidence of union usually after 6-9 weeks, full weight bearing was started. Follow up were carried out at 6, 12 and 24 weeks and thereafter on every 2 months for 12 months. Follow up antero-posterior and lateral radiographs were reviewed at each postoperative visit (Fig. 2). These radiographs were analysed for

callus formation, implant position, coronal and sagittal plane mal-alignment and shortening across fracture site. Clinically patients' range of motion of knee and hip joints, limb length discrepancy, degree of pain or swelling, condition of the wound and the skin were documented (Fig. 3).

The results were evaluated according to the TENS scoring system used by FLYNN et al⁽²⁾ as shown in Table 1.

Statistical analysis was performed by a Bio statistician using the SPSS Statistics version II.

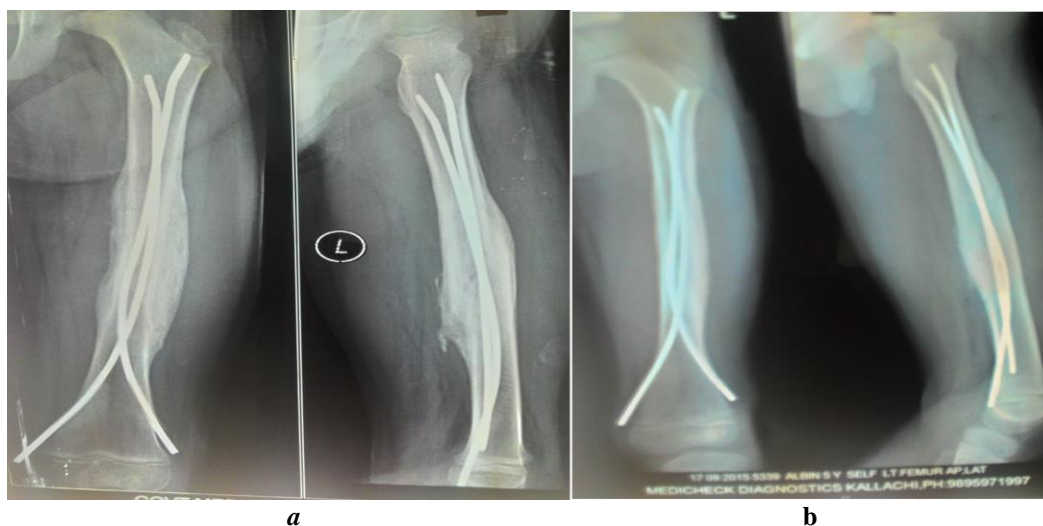

Fig. 2: a & b: Follow-up X-rays at 6 weeks and 3 months

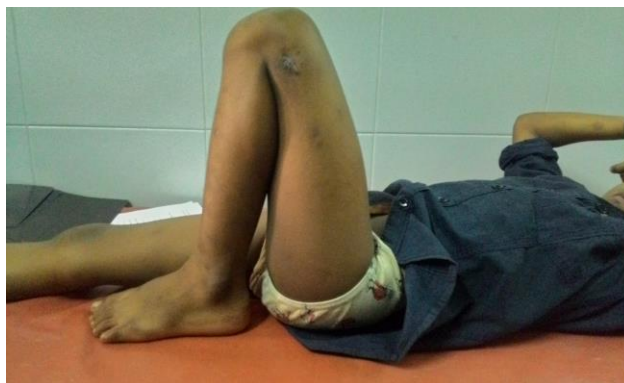

Fig. 3: United case show full knee flexion

Results

A total of 20 children who underwent elastic stable intramedullary nailing for femoral diaphyseal fractures were evaluated in this study. Mean age of the patients was 7.9 years, ranging from 3 to 13 years. Sixteen (80%) were boys, and four (20%) were girls and most of them were victims of road traffic accidents. All patients were treated with Elastic Stable Intramedullary Nailing. Thirteen children (65%) had middle-third femoral shaft fractures and seven (35%) had upper-third and middle-third junction fractures. The demographic details, including the age and anatomical site of fracture are shown in Table 1.

Table 1: Demographic characteristics of the study group

	Total	Boys	Girls
No. of patients	20	16	4
5 – 10 years	60 %	10	2
11-13 years	40 %	6	2
Anatomical Site of fracture			
Middle-third femoral shaft	10	10	2
Upper-third and middle third junction of third femoral shaft	7	4	1
Middle-third and lower third junction of femoral shaft junction	3	2	1

Eighteen (90%) cases were closed fractures and 2 (10%) cases were type 2 open fracture. Seventeen cases could be closely reduced and fixed. In the remaining three cases, wound debridement followed by open reduction and fixation with titanium elastic nails. All children could be able to do the active hip and knee range of motion exercise on 2nd postoperative day, partial weight bearing around 3-4 weeks. The mean follow-up was 18 months (ranged 6 - 24 Months). All fractures were united between 7-12 weeks, with average time of union being 8.3 weeks. All patients had good range of movements of hip and knee joints except 3 patients with terminal limitation of knee movement possibly due to the nail protrusion they had. They

regained full range of motion followed a course of physiotherapy. Six patients (30%) had limb shortening of 1-2 cm and nine patients (45%) had less than 1cm which was not clinically significant (P<0.026) and five patients (25%) had 2-2.4cm which was gradually corrected to 1 cm on 1 year follow-up .Surgical site superficial skin infection was seen in one case which was subsided with a course of oral antibiotics. One patient had anteroposterior angulation of >10⁰ and three had <10⁰. Varus/valgus angulation and rotational malalignment was never observed in our study group. The complication details are shown in Table 2.

Table 2: The complication details of the cohort

Complications		No. of cases	Percentage
LLD	<1cm	9	45%
	1-2cm	5	25%
	>2cm	Nil	Nil
Infection		1	5%
Delayed / non union		Nil	Nil
Nail protrusion		3	15%
Pain		1	5%
Knee flexion at 12 wks	0 ⁰ -160 ⁰	18	90%
	<10 ⁰ -110 ⁰	2	10%
	<30 ⁰ -90 ⁰	Nil	Nil
Radiogram angulation	<5 ⁰	16	80%
	5 ⁰ -10 ⁰	3	15%
	>10 ⁰	1	5%

TENS scoring system by FLYNN et al shows excellent results in 12 patients (60%), good results in 6 patients (30%) and poor results in only 2 patients (10%) (Table 3).

Table 3: TENS score by FLYNN et al of the study group

Criteria	Excellent	Good	Poor
Limb length discrepancy	9 (45%)	6 (30%)	5(25%)
Angulation	16	3	1
Pain	10	8	
Complication	15	4	1

Discussion

It has been commonly accepted that surgical intervention is indicated in pediatric femoral shaft fracture in age group of 4-16 years associated with open fracture, polytrauma, concomitant head injuries and neurovascular injuries.⁽³⁾ However literature review suggests that surgery can also be considered for isolated femoral fractures in children.

Due to various benefits such as earlier return to function, less joint stiffness, less wound complication, less mal-union or non-union, reduction in duration of hospitalization and cost effectiveness makes the flexible intramedullary nailing as one of the best methods of choice in children.⁽⁴⁾

In children, intervention using elastic nails is technically easier than the use of rigid nails. In our study, we restricted our analysis to find the efficacy of this technique by finding average duration of hospital stay and time taken for radiological union. We also concentrated on finding out the common complications and their incidence. We evaluated results of our study group and compared them with those obtained by various other studies utilizing similar fixation technique.

In our study, majority of the patients (No. 14 [70%]) were in the age group of 6-10 years.⁽⁵⁾ The youngest patient was 5 years and the oldest one was 12 years. Mean of the age group was 7.9 years. This finding was similar to other studies where the mean age in their group was 9.6 years and 8.6 years respectively.⁽⁶⁻⁸⁾ In our study, there were 11 (55%) cases of transverse fracture, 3 (15%) cases of oblique fracture 6 (30%) cases of spiral fractures. In our study, middle third of the femur was the common site of injury. Similar findings were obtained in other published studies.^(8,9)

Most of the femoral shaft fractures in children are closed injuries.⁽¹⁰⁾ In our study, 18 (90%) cases were closed fractures and 2 (10%) cases were type 2 open fracture. These data showed that open femoral fractures are rarely seen in infants and younger children compared to adults.

This is because of immature bone's inherent flexibility and reduced tensile strength which makes the bone tend to bend before it breaks. Moreover the edges of fracture fragments are not so sharp, so penetration of the soft tissue occurs less frequently.

Though evidences⁽⁷⁾ reported that no other immobilization treatments like plaster or orthosis were required, we used long leg slab in one of our patients to maintain the reduction because the site of fracture was more proximal with long spiral pattern. We also used skin traction in two children to maintain the reduction in long spiral fractures anticipating the postoperative displacement.

The average duration of hospital stay in the present study was 7.3 days. Studies by different authors shown the mean hospital stay was 12 days,⁽¹¹⁾ 7.8 days⁽⁷⁾ and

9.43 days⁽⁸⁾. The reduced hospital stay in our study could be because of proper selection of patients, stable fixation and absence of serious complications. Average duration of confinement to home (return to school) was 62 days while it was 51 days⁽¹²⁾ and 48 days⁽⁴⁾ in the various studies conducted in past.

In the present study, average time taken for union was 8.3 weeks. In the published various studies, average healing time was 7.73 weeks,⁽⁸⁾ 8 weeks⁽¹²⁾ and 8 weeks⁽¹³⁾ respectively. In our study, closed reduction of the fracture was done in 85% of the cases, leading to preservation of fracture hematoma and no soft tissue dissection around the fracture site. Early physiotherapy was also started for most of the patients. These may be the reasons for rapid union of the fractures compared to compression plate fixation.

Regarding the complications of this technique, limb length discrepancy was the most common complication. In the present study, average limb length discrepancy was 0.5 cm. No patient in our study had significant limb length discrepancy (i.e., > ± 2 cm). Comparing to limb length discrepancy in other studies using similar technique and conservative methods, limb length discrepancy in our study was within the acceptable limits. This minimal limb length discrepancy had not produced any functional disability during the follow-up functional assessment.

In our study, nail impingement at the insertion site was seen in 3 (15%) patients due to increased length of the nail outside the bone at the insertion site. The first patient needed a second intervention surgery in order to have the tip of the nail trimmed since she had severe pain and knee stiffness. Previous studies^(7,8) also reported same incidence of this complication. This complication could be avoided in our subsequent cases by the appropriate trimming of the nail outside the bone which is recommended as 2-2.5cm.

All patients had full range of hip motion in the present study, while 6 (30%) patients had terminal 10⁰ restriction of knee movements (flexion) which was corrected by immediate physiotherapy. Two (10%) children had restriction (less than 10⁰ - 110⁰ arc) in knee flexion at 4 months, but normal range of knee flexion was achieved at 8 months by the continuation of physiotherapy. One study⁽¹³⁾ demonstrated a significant loss of motion at the knee in 14 (53.84%) patients.

Superficial infection was seen only in one case of our series and which was subsided with a course of oral antibiotics. Infection is more common in the other modes of surgical treatment compared to flexible intramedullary nailing because pin tract infection is a major disadvantage of external fixation application and excessive exposure leads to increased risk of infection in plating method.

Some degree of angular deformity is frequent after femoral shaft fractures in children, but this usually remodels during growth. In our study, there was no varus/valgus mal-alignment. There were antero-

posterior angulations in 4 patients, of which 3 (15%) had 5-10° and one had 12°. None of the patients in our study had significant rotational deformity which was clinically assessed by out-toeing or in-toeing of the foot. The minimal antero-posterior angulations of our four cases did not produced any disability and it was reduced during the follow-up visits.

One study⁽¹⁴⁾ reported universally good results in 141 fractures without a single complication whereas another study⁽⁴⁾ had only one poor result in 58 fractures. Several other authors have reported variable rates of complications.

Evidence⁽¹²⁾ reported an overall complication rate of 49% (21/43) but only 2 cases had major postoperative complications while the others had only minor complications. We also had overall 6 patients with mild complications (30%) and 2 patients had major complications (10%). The advantages we found through the present study include ability of closed reduction in majority of cases with minimum complications and reduced hospital stay. Since the implant is a load sharing device, which would help the fracture to heal by secondary callus formation which is stronger and risk of refracture or implant breakage is hence minimized.⁽¹⁵⁾

Conclusion

Based on our experience and results, we conclude that Elastic Stable Intramedullary Nailing technique is an ideal method for treatment of pediatric femoral shaft fractures. It gives elastic mobility promoting rapid union at fracture site and stability which is ideal for early mobilization. It gives lower complication rate and permits early return to school when compared with other methods of treatment as per the current evidences.

Funding: This research not received any specific grant from funding agencies in the public or commercial sectors.

Acknowledgements

We thank all our patients who co operated to carry out this project.

Conflict of interest: Nil

References

1. Lee SS, Mahar AT, Newton PO. Ender nail fixation of pediatric femur fractures. A biomechanical analysis. *J Pediatr Orthop* 2001;21: 442-445.
2. Kasser JR, Beaty JH. Femoral shaft fractures. In: Beaty JH. And Kasser JR eds. *Rockwood and Wilkin's fractures in children*. 5th edition, Philadelphia, Lippincott, Williams and Wilkins, 2001:941-980.
3. Flynn JM, Luedtke L, Ganley TJ, Pill SG. Titanium elastic nails for pediatric femur fractures: lessons from the learning curve. *Am J Orthop (Belle Mead NJ)* 2002;31(2):71-74.
4. Flynn JM, Hresko T, Reynolds RA et al. Titanium elastic nails for pediatric femur fractures: a multicenter study of early results with analysis of complications. *J Pediatr Orthop* 2001;21(1):4-8.
5. Green JK, Werner FW, Dhawan et al. A biomechanical study on flexible intramedullary nails used to treat pediatric femoral fractures. *J Orthop Res* 2005;23(6):1315-1320.
6. Gregory P, DiCicco J, Karpik K et al. Ipsilateral fractures of the femur and tibia: treatment with retrograde femoral nailing and unreamed tibial nailing. *J Orthop Trauma* 1996;10(5):309-316.
7. Ligier JN, Metaizeau JP, Prevot J, Lascombes P. Elastic stable intramedullary nailing of femur fracture in children. *J Bone & Joint Surg (Br)* 1988;70(B):74-7.
8. Luhmann SJ, Schootman M, Schoenecker PL, Dobbs MB, Gordon JE. Complications of titanium elastic nails for pediatric femoral shaft fractures. *J Pediatr Orthop* 2003;23(4):443-7.
9. Rios AU, Arango DFS, Molina COV, Posad AJT. Femoral shaft fractures treated with stainless steel flexible nails in children aged between 5 and 12 years at the HUSVP: a two-year follow-up. *J Child Orthop*. 2009;3(2):129-135.
10. Nascimento FP, Santili C, Akkari M, Waisberg G, Braga SR, Fucs PMMB. Short hospitalization period with elastic stable intramedullary nails in the treatment of femoral shaft fractures in school children. *J Child Orthop*. 2010 Feb;4(1):53-60.
11. Heinrich SD, Dr Varic DM, Karr K, Macevan GD. The operative stabilization of pediatric diaphyseal femur fractures with flexible intramedullary nails: A prospective analysis. *J pediatrOrthop* 1994;14:501-507.
12. Cramer KE, Tornetta P, Spero CR, Alter S, Miraliakbar H, Teefey J. Ender rod fixation of femoral shaft fracture in children. *ClinOrthop and Rel Research* 2000;376:119-123.
13. Kalenderer O, Eranilmaz G. Biological internal fixation of comminuted femur shaft fractures by bridge plating in children. *J Pediatr Orthop* 2003;23:184-189.
14. LeventLeleb et al. The results of ESIN technique in children with femoral shaft fractures. *J Pediatr Orthop* 2003;41:38-41.
15. Vrsansky P, Bourdelat D, Al Faour A. Flexible intramedullary pinning technique in the treatment of pediatric fractures. *J Pediatr Orthop* 2000;20:23-7.