

## ACL avulsion managed with pullout suture technique- A prospective study

Kishor Kumar. M<sup>1</sup>, Shivakumar Kerakkanavar<sup>2\*</sup>

<sup>1,2</sup>Assistant Professor, Dept. of Orthopaedics, <sup>1</sup>Muthukumaran Medical College, Chennai, <sup>2</sup>Rajarajeshwari Medical College and Hospital, Bangalore

**\*Corresponding Author:**

Email: skumardoc@gmail.com

### Abstracts

**Introduction:** Anterior cruciate ligament (ACL) most commonly avulsed from tibial attachment. Affected mostly in young patients, mechanism of injury includes road traffic accidents, falls, and sports injuries. Various methods of fixation are used in operative treatment of these fractures varying from retrograde wires, screws, ante grade screws, sutures, suture anchors, and a recently described suture bridge and K wire and tension band wiring technique. In this study, we are assessing arthroscopic pull out suture technique in ACL tibial avulsion.

**Materials & Methods:** This is prospective study done in two institutions by two surgeons between March 2015 to March 2017. Total number of 18 patients (12 males and 6 females) who went arthroscopic ACL tibial avulsion fixation were selected for the study. Fractures were classified according to the Meyers and McKeever fracture classification system. First diagnostic knee arthroscopy done then fracture crater exposed, washed, reduced and fixed temporarily with K- wire passed through superomedial portal. Knot taken on ACL with fiber wire no 2 and pulled through two portals, made medial and lateral to ACL footprint. Pulled fiber wires secured through suture disk on medial tibial surface. Postoperatively, the knee was maintained with long knee brace in full extension for 2 weeks. Touch weight bearing walk was allowed on day 1. Initial phase include closed kinetic chain exercise and sports activities advised after 6 months.

**Results:** Total 18 (12 male and 6 female) patients were enrolled in the study, age ranging from 18 to 45 years (Mean 30.3 years). 7 patients with right knee and 11 patients with left knee involved. Out of 18 patients, 9 patients were of type 3, 6 patients were of type 2 and remaining 3 patients were of type 4. Average time of surgery from date of trauma was 6 days. Patients assessed at 2, 6, 12 and 24 weeks. At the end of 12 months, we lost 2 cases follow up, anterior drawer test was positive in 6 cases, one patients had instability with Lachman test positive as he had nonunion, for which ACL reconstruction done with autologous semitendinosus graft. International Knee Documentation Committee (IKDC) score done in 16 patients at 12 months follow up.

**Conclusion:** We recommend arthroscopic suture fixation of tibial avulsion of ACL in adults with advantage of rigid fixation, good postoperative functional outcome. However our study sample and follow up duration is less, further study is required.

**Keywords:** ACL, Avulsion, pullout suture.

### Introduction

Increased urbanization has caused more number of vehicles and road traffic accidents, most of the victims being young adults and teenage group. Anterior cruciate ligament avulsion common in young adults and teenage group, other mechanism of injuries include sports injuries fall. Anterior cruciate ligament (ACL) avulsed mostly from tibial attachment. According to Meyers and McKeever's classification<sup>(1)</sup> these injuries can be classified in to 3 types.

Type 1: minimal or no displacement and is usually treated conservatively;

Type 2: partially displaced, where posterior hinge attached to tibia and only anterior fragment avulsed and superiorly displaced, showing as beak in lateral X-ray.

Type 3: complete fragment elevation anteriorly and posteriorly; it has two sub types

Type 3a: involves small portion of eminence

Type 3b: involves the majority of the eminence.

Type 4: displaced, comminuted fracture and type 4 added by Zariczyj.<sup>(2)</sup>

Different authors have conducted study regarding methods of treatment. Type 1 fractures universally treated with conservative method, for type 2 fractures

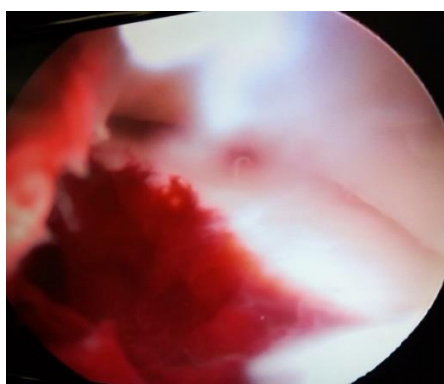
treatment is still controversial, for type 3 and 4 fractures many surgeons recommend retrograde wires, cancellous screws, suture anchors, suture bridge, k wire with tension band wire. In this study, we are assessing arthroscopic pull out suture technique in ACL tibial avulsion.

### Materials & Methods

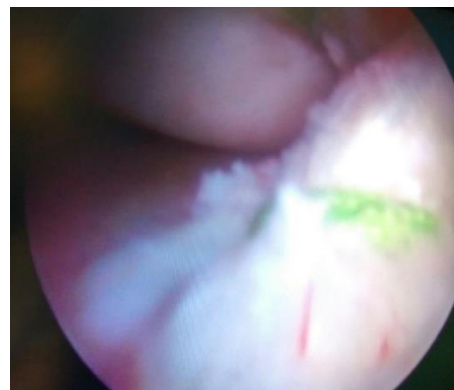This is prospective study done in two institutions by two surgeons between March, 2015 to March, 2017. Total number of 18 patients (12 males and 6 females) who went arthroscopic ACL tibial avulsion fixation were selected for the study. The written informed consent from the patients and institute ethical committee approval taken for the study. Patients with an acute injury with avulsion type 2, 3 and 4 were included in the study. Chronic injury, type 1 avulsion and patients not fit for anesthesia were excluded from the study. History and examination includes effusion, joint tenderness, knee joint range of motion, anterior drawer and Lachman tests, medical and lateral collateral ligament stress tests. Investigations includes Antero-posterior and lateral knee X-rays, magnetic resonance imaging (MRI). These investigations used to classify fracture type using Meyers and McKeever fracture classification, check other concomitant injuries like bone contusion, meniscal and other ligament injury.

In supine position, under spinal anaesthesia with perioperative antibiotic coverage, after limb is exsanguinated, tourniquet inflated.) The knee was assessed through the anterolateral and anteromedial portals using a 30° 4-mm arthroscope. Haematoma thoroughly washed and standard diagnostic arthroscopy done to assess meniscal or chondral injuries, and other ligament tear. Superomedial portal was done 4 cm proximal to and in line with the medial edge of the patella in knee extension Fracture visualized, curetted and temporary reduction done using 2 mm kirschner wire from superomedial portal, in some cases there was intermeniscal ligament and other soft tissue hindering reduction which is released. Using ACL jig two 2.7 mm guide wire drilled through medial tibial cortex on medial and lateral side of ACL footprint. Through medial portal bite is taken through ACL base posterior half, loop passed in accessory lateral portal, retrieved and fiber wire no 2 passed through this loop and exited in medial portal. Procedure repeated with bite taken in anterior half of ACL base. Medial and lateral Fiber wires are shuttled through medial and lateral tibial tunnel already drilled, using Prolene no one loop. Temporary Kirschner wire removed and fracture reduction assessed with arthroscope by keep pulling fiber wires, impingement checked in knee full range of motion. Fiber wires tied through suture disk on medial tibial cortex.

Postoperative patient were advised long knee brace for 2 weeks and were mobilised on toe touch from day 1 and heel press, static quadriceps exercises and straight leg raising in long knee brace encouraged. At 2 weeks, range of motion from 0 to 90° and partial weight bearing allowed, at 6 weeks full weight bearing allowed, at 10 weeks running and returning to sports activities allowed after 6 months.



**Fig. 1: Avulsed ACL**



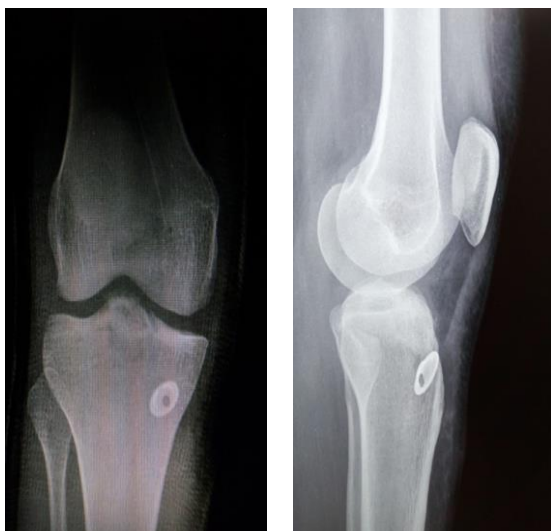**Fig. 2: Fiber wire securing ACL close to avulsion and in to tibial tunnel**

### Results

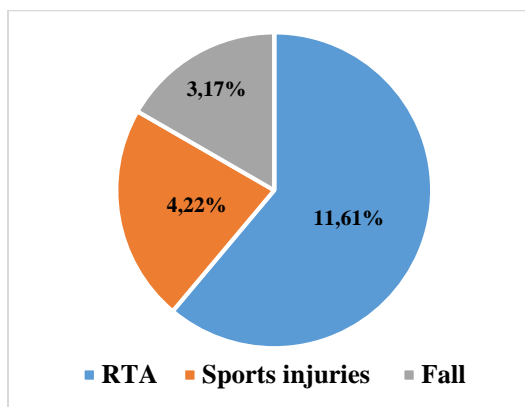
Total 18 (12 male and 6 female) patients were enrolled in the study, age ranging from 18 to 45 years (Mean 30.3 years). 7 patients with right knee and 11 patients with left knee involved. Effusion was mild in 7 cases, moderate in 9 cases and severe in 2 cases. On palpation, 10 patients had medial joint line tenderness and 8 had none. Out of 18 patients, 9 (50%) patients were of type 3, 6 (33.3%) patients were of type 2 and remaining 3 (16.6%) patients were of type 4. Average time of surgery from date of trauma was 6 days (range 2-14 days). Patients assessed at 2, 6, 12 and 24 weeks. Two patients (one male and another female) could not be traced for follow up at 12 months, in remaining 16 cases, 6 patients had anterior drawer positive without any symptoms of instability. In one patient ACL reconstruction done using autologous semitendinosus graft as he had symptoms of instability with non-union of ACL avulsion fragment. International Knee Documentation Committee (IKDC) score done in 16 patients at 12 months follow up. (Table.1)

**Table 1: Total number of patients with IKDC score range**

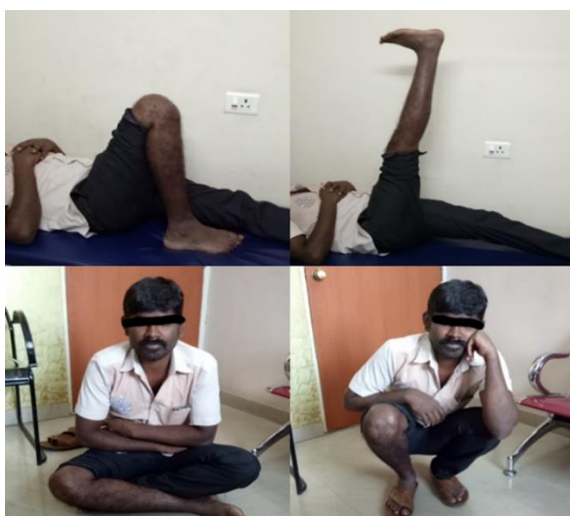IKDC Score	Number of patients	Percentage
90-95	11	68.75
85-90	4	25
70.6	1	6.25



**Fig. 3: Post-operative antero-posterior and lateral X-rays showing fixed ACL avulsion fragment with suture pullout in to suture disk**



**Chart 1: Mode of Injury**



**Fig. 4: Clinical photograph of Operated ACL Avulsion patient after one year follow up**

## Discussion

ACL tibial avulsion more common in skeletally immatures patients and less common in adults.<sup>(1,2)</sup> All ACL avulsion patients treated with surgery, except type 1 where conservative methods have proven effective. ACL retaining surgeries have an advantage of proprioception and neuromuscular control with the help of mechanoreceptors.<sup>(12)</sup> Many a times meniscus get entrapped under fractured tibial eminence, prevents anatomical closed reduction. Arthroscopy allows to treat additional meniscal, cartilage and other ligament injuries. Still surgery is not defined regarding screw fixation and suture pull out technique. Tsukada et al<sup>(13)</sup> studied that there was significant anterior translation with cyclic loading in fractures treated with pullout suture compared with screw fixation. On the contrary, Bong et al,<sup>(14)</sup> in their study of screw versus pull out suture fixation concluded that fibre wire fixation was more stronger than screw fixation. Some studies<sup>(15)</sup> found no significant difference in results with regard to the type of fixation and Seon et al.<sup>(16)</sup> studied that both the screws and suture pull out technique produced a relatively good results. Few studies have recommended pull out suture pull out technique for all cases.<sup>(17,18)</sup> In our study we used suture pull out technique, in all 16 follow up patients, 11(68.75%) had good results, 4 (25%) had fair results and one (6.25%) case went in to nonunion which is comparable to results done by SR Sundararajan et al.<sup>(19)</sup>

Tibial avulsion of ACL fixation with arthroscopic pull out sutures fixation has good post-operative functional out come in our study. So, we recommend this technique for treatment these type of fractures. However our study sample and follow up duration is less, further study is required with large sample and long follow up.

## References

1. Meyers MH, Mckeever FM. Fracture of the intercondylar eminence of the tibia. J Bone Joint Surg Am 1959;41-A:209-20.
2. Zaricznyj B. Avulsion fracture of the tibial eminence: Treatment by open reduction and pinning. J Bone Joint Surg Am 1977;59:1111-4.
3. Van Loon, T & Marti, R. K. A fracture of the intercondylar eminence of the tibia treated by arthroscopic fixation. Arthroscopy (1991),7,385-388.
4. Reynders, P, Reynders, K, & Broos, P. (2002). Pediatric and adolescent tibial eminence fractures: arthroscopic cannulated screw fixation. J Trauma,53(1),49-54.
5. Ahn, J. H, & Yoo, J. C. (2005). Clinical outcome of arthroscopic reduction and suture for displace acute and chronic tibial spinefractures. Knee Surg Sports Traumatol Arthrosc ,13(2),116-121.
6. Lehman RA Jr, Murphy KP, Machen MP, Kuklo TR ((2003). Modified arthroscopic suture fixation of a displace tibial eminencefracture. Arthroscopy 19(2):E6.
7. Su, W. R, Wang, P. H, Wang, H. N, & Lin, C. J. modified arthroscopic suture fixation of avulsion fracture of the tibial Intercondylar eminence in children. J Pediatr Orthop B,20,17-21.
8. Medlar, R. G & Jansson, K. A. Arthroscopic treatment of fractures of the tibial spine. Arthroscopy (1995),11,328-331.

9. Vega, J. R, Iribarra, L. A, Baar, A. K, Iniguez, M, Salgado, M, & Gana, N. (2008). Arthroscopic fixation of displaced tibial eminence fractures: a new growth plate-sparing method. *Arthroscopy Knee Surg Sports Traumatol Arthrosc.* A new procedure for tibial spine avulsion fracture fixation Matthew A. Mann Nicholas M. Desy Paul A. Martineau, January 2012,24(11),1239-1243.
10. Matthew A. Mann, Nicholas M. Desy, Paul A. Martineau. A new procedure for tibial spine avulsion fracture fixation January 2012. *Knee Surgery Sports Traumatology Arthroscopy.*
11. Yudong Gan, Dachuan Xu, Jing Ding and Yongqing Xu *Knee Surg Sports Traumatol Arthrosc.* Tension band wire fixation for anterior cruciate ligament avulsion fracture: biomechanical comparison of four fixation techniques (2012),20(5),909-915.
12. Schultz RA, Miller DC, Kerr CS, Micheli L. Mechanoreceptors in human cruciate ligaments. A histological study. *J Bone Joint Surg Am* 1984;66:1072-6.
13. Tsukada H, Ishibashi Y, Tsuda E, Hiraga Y, Toh S. A biomechanical comparison of repair techniques for anterior cruciate ligament tibial avulsion fracture under cyclic loading. *Arthroscopy* 2005;21:1197–201.
14. Bong, M, Romero, A, Kubiak, E, et al. Suture versus screw fixation of displaced tibial eminence fractures: a biomechanical comparison. *Arthroscopy* (2005),21(10),1172-6.
15. Hunter, R. E, & Willis, J. A. Arthroscopic fixation of avulsion fractures of the tibial eminence: technique and outcome. *Arthroscopy* (2004).Feb.,20(2),113-21.
16. Seon, J, Park, S. J, Lee, K. B, et al. A clinical comparison of screw and suture fixation of anterior cruciate ligament tibial avulsion fractures. *Am J Sports Med* (2009),37(12), 2334-9.
17. Lubowitz, J. Part II: arthroscopic treatment of tibial plateau fractures: Intercondylar eminence avulsion fractures. *Arthroscopy* (2005),21(1),86-92.
18. Biyani, A, Reddy, N. S, Chaudhury, J, Simison, A. J, & Klenerman, L. The results of surgical management of displaced tibial plateau fractures in the elderly. *Injury* (1995).
19. SR Sundararajan, S Rajasekaran, S Leo Bernard. Displaced anterior cruciate ligament avulsion fractures: Arthroscopic staple fixation: *IJO*,14(4),324-329.