

To compare outcomes in patients with diaphyseal fracture of tibia managed by intramedullary nailing with intact fibula vs fracture tibia with fibula

Madhukar K. T.¹, Moinuddin Basha K.^{2,*}

¹Associate Professor, ²PG Student, Dept. of Orthopaedics, Adichunchanagiri Institute of Medical Sciences, Bellur, Mandhya, Karnataka, India

*Corresponding Author:

Email: moin1503@gmail.com

Abstract

Introduction: Fractures of the tibia and fibula are relatively common and have been recognized as serious and debilitating injuries for centuries. The primary aim of the study was to compare outcomes in patient with a diaphyseal fracture of tibia managed by intramedullary nailing with intact fibula Vs fracture both bone of the leg.

Method: Total of 72 patients were included in this study. They were divided into 2 groups. Group A (12 out of 72) comprised patients with tibial diaphysis fracture alone, and Group B (60 out of 72) was made up of patients with both bone fractures of leg. Reamed intramedullary nailing was done in both Groups. Both the groups were followed up and compared in terms of duration of surgery, the rate of union.

Result: The average duration of surgery (group A-108 minutes, Group B-98.6 minutes), the rate of union was longer [20 weeks in group A and 18.2 weeks in group B] in group A. Group A were more proven for union-related problem. In group A, the delayed union was seen in 6 (50%) cases out of which 4 united readily with fibular osteotomy/partial fibulectomy and 2 patients were diagnosed with non-union. In group B, the delayed union was seen only in 4 (6.66%) and none were progressed to non-union.

Conclusion: Fracture tibia with intact fibula are more proven for union-related problems when compared to both bone leg fracture. Partial fibulectomy is an effective intervention in the management of delayed union in isolated tibia fracture.

Keywords: Isolated Tibia Diaphyseal Fracture, Intramedullary Nailing, Fibulectomy.

Introduction

Tibia is one of the most commonly fractured long bone presents in the body and it is because of its location the tibia is exposed to frequent injuries. Because one third of the tibial surface is subcutaneous throughout most of its length, open fractures are more common in the tibia than in any other major long bone.⁽¹⁾ Descriptions of the treatment of tibial fractures are included in the Edwin Smith Papyrus, an ancient Egyptian medical text dating back to at least 1500 to 1600 BC.⁽²⁾

The tibial diaphysis is the most common site of fracture in the tibia and about 80% of these injuries have associated fibular fractures.⁽³⁾ Compared to fractures elsewhere in the body, tibial fractures have relatively

high rates of non-union and malunion.⁽⁴⁾ Many studies blame the intact fibula for the cause for complication associated with management of tibia fracture like delayed union, non-union and malunion.

The fibula carries 6 to 15% of the load of the lower extremity.⁽⁵⁾ With a fibula, tibio-fibular length discrepancy develops and causes altered strain pattern in both tibia and fibula leading to delayed union, non union, or malunion of tibia leading to sequelae of joint disturbance.⁽⁶⁾

The aim of the present study was to compare outcomes in terms of duration surgery, rate of union, malunion, delayed union, non-union when tibial shaft fracture managed with reamed intramedullary nailing in patient with intact fibula Vs both bone leg fracture.

Methods and Material

In this study, 77 patients who sustained tibia fracture and underwent closed reduction and reamed intramedullary interlocking nailing for closed and open fractures in the department of orthopaedics, in a tertiary care centre were included in the study. Five patients were not available in follow up. 72 patients (56 males, 44 females) were available at final follow up for the analysis. Patients were grouped into group A and Group B. Group A consisted of 12 (22.22%) patient with isolated tibia fracture with intact fibula and Group B consisted of 62 patients (86.1%) with fracture of both tibia and fibula. About 76.5% of the patient belonged to 18-38 years age group, with 18 and half years being

youngest and 65 years being oldest patient. Out of 72, 56 (77.7%) were male patient and 16 (22.2%) were female.

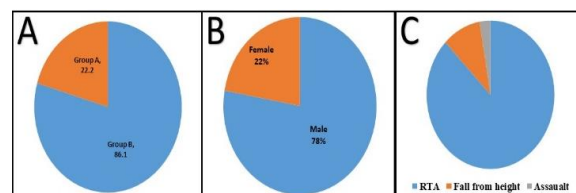


Fig. 1: (A) Distribution of cases into two Groups in present study; (B) Sex distribution in present study; (C) Different modes of injury in present study.

Inclusion criteria

1. Closed tibial fracture (with or without intact fibula)

2. Type 1 and type 2 open fracture of tibia (with or without intact fibula) as classified by Gustillo-andreson grading.
3. Tibial fracture in the age group above 18 years.

Exclusion criteria

1. Type 3 open fracture of tibia.
2. Tibial fractures with intra articular extension.
3. Pathological tibial fractures.

Patients were admitted, and general conditions were assessed and vital stabilised with appropriate measure in the emergency department and above knee dorsal slab applied to splint the limb. Patients were grouped into Group A and group B. Preoperative investigation were

The data collected regarding all the selected cases were recorded in a Master Chart. And patients were assessed at final follow up for malunions.

Results

Out of 72 patient, 12 patient (22.2%) had sustained isolated tibial fracture they were grouped into Group A, and rest 60 patient (83.3%) were grouped into Group B as they had sustained both tibia and fibula fracture. Most common side involved was right side accounting to 61.1% (44 out of 72), left side being 38.9 % (28 out of 72). In our study 47 out of 72 patient (65.25) had closed fracture and 25 out of 72 (34.72%) sustained open fractures out of which 10 (13.9%) were type 1 and 15 (20.8%) were type 2 according to Gustillo-andreson grading for open fractures.

Most common cause was RTA in the both groups (63 out of 72) accounting for 87.5% followed by fall from height or workplace injuries constituting about 9.72 % (7 out of 72) and 2.77% (2 out of 72) cause was due to assault.

Intra operatively the duration of surgery was measured from time of incision to suture closure. Average duration of surgery was 108 minutes in group A and 98.6 minutes in group B.

Table 1: Demographic Data of present study

		Group A	Group B
Sex	Male	9	47
	Female	3	13
Side	Right	7	37
	Left	5	23
Mode of injury	RTA	6	57
	Self Fall	4	3
	Assault	2	0
Open or closed fracture	Closed	7	40
	Open	5	20
Type of open fracture (Gustilo Anderson)	I	3	7
	II	2	13

Post operatively 54 out of 72 patients (75%) were mobilized within 5 days of operation, 9 patients (12.5%) were mobilized between 5 – 10 day of oT and rest 9 cases (12.5%) in were mobilized after 10 days.

done, along with X-ray of full length of tibia antero-posterior and lateral view was taken. All the fractures were managed with closed intramedullary interlocking nail. Wound inspected on post op day 2, 5 and 10 and sutures were removed on post op day 12. Patient mobilized with non-weight bearing with aid of walker on post op day 2 based on Patients general conditions. Patients were followed up at 2, 6, 12, 24 weeks. Patients are assessed clinically and Radiographs are obtained at each visits .Patient were asked to bear weight once radiological sign of fracture union were seen that is signs of union in at least 3 cortex.

During the follow up the in both the groups the union rate was 86.11% (62 out of 72), the average rate of union was 20 weeks in group A (12 weeks to 36 weeks) and 18.2 weeks (10 weeks to 32 weeks) in group B.

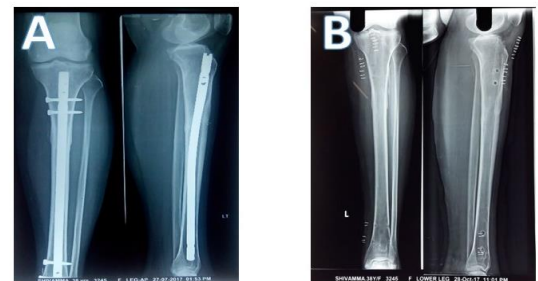


Fig. 2: (A): Group A X-ray at final follow up, (B): After Implant Removal

Patient were asked to full weight bear (FTB) once signs of union seen radiologically confirmed, and were observed that 63 out of 72 (87.5%) patient started FTB 10 to 18 weeks and 9 (12.5%) patients started FTB after 18 weeks.

In our study, 6 out of 12 patients of group A were observed to have delayed union at the end of 3 months. All 6 patients were subjected to fibular osteotomy\partial fibulectomy. Out of which 4 patient were successfully managed and showed signs of healing radiologically by end of 26 weeks. And rest of 2 patients who had initially sustained compound tibia fracture (type 2) had to be managed with bone grafting and went on to heal by end of 6 months.

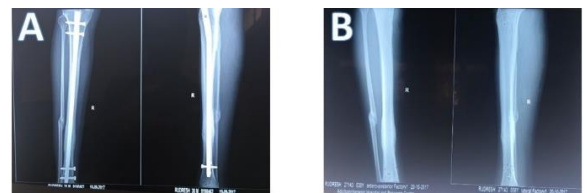

Fig. 2: (A): Group B X-ray at final follow up; (B): After Implant Removal

In group B, 4 out 60 were diagnosed with delayed union. And all four were compound fracture with superficial infection at the fracture site successfully

managed with antibiotics, flap coverage and grafting at end of 8 weeks.

And one patient out of 72 had deep infection which eventually ended up in non-union and was managed with implant removal followed by external fixation for 6 weeks, immobilized for further 6 weeks in functional PTB cast.

Table 2: Observation after Intervention

	Group A	Group B
Duration Of Surgery	108 Minutes	98 Minutes
Mean Time Of Union	20 Weeks (12weeks To 36 Weeks)	18.2 Weeks (10 Weeks To 32 Weeks)
Delayed Union	6	4
Non Union	2	0

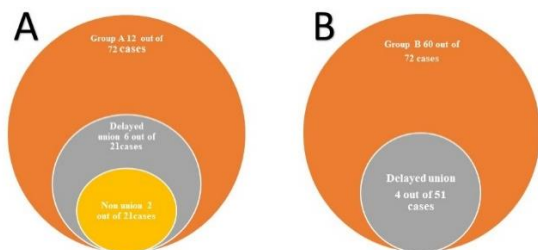


Fig. 4: Observation made in Group A(A) & Group B(B)

Discussion

Tibia being a subcutaneous weight bearing long bone is one of the commonest fractured long bones in the body. The commonest site being diaphysis. Compared to fractures elsewhere in the body, tibial fractures have relatively high rates of non-union and malunion.⁽⁴⁾

In our study, high energy trauma (RTA) was most common mode of injury accounting for 87.5 %. Isolated tibia fracture were less common and were equally associated with low energy trauma and high energy trauma when compared to Both bone leg fracture which more common and associated with high energy trauma.

Table 3: Different modes of injury in present study

MODE OF INJURY	GROUP A	GROUP B
RTA	6(50%)	57(95%)
Self Fall	4(33.3%)	3(5%)
Assault	2(16.7%)	0

Right side was more commonly affected then left side. In our study, closed tibial fractures (65.25%) were common then open (34.72%).

The mean duration of surgery in our study was observed to be was 108 minutes in group A comparatively more than group B in whom it was 98 minutes. It was observed that intra operative reduction

was tibia was difficult when intact fibula was present, especially when tibia is grossly displaced, which reflects in form of increased chance of malunion in case of isolated tibia fractures following IM nailing. Ranganath *et al* conducted a study and he stated that, the main difficulties encountered in the orthopaedic treatment of leg fractures with intact fibula are reduction of the tibial and an unusually high rate of varus malunion, and non-unions.⁽⁷⁾

In our observations, Group B cases showed fracture healing radiologically by mean period of 18.2 weeks, which was comparatively earlier then group A in whom mean union period noticed was 20 weeks.

Tibial shaft fractures with an intact fibula show a higher rate of delayed, non and mal-union than those with fibular fractures, especially when the tibial shaft fracture is displaced.⁽⁸⁾

In our study group A, consisting of isolated tibia fracture were more proven for union related problems compared to Group B. In group A delayed union was seen in 50% cases were as in group B it was only 6.66%.and non-union in group A was 16.6 % were as there was no non-union seen in group B. This correlated with literature. The fibula carries 6-15% of the load of the lower extremity.⁽⁵⁾ In presence of an intact fibula, if tibial fracture has to be compressed, a considerable fraction of the applied force is spent on deforming the intact fibula, decreasing the compression force on the tibial fracture fragments. Hence intact fibula prevents effective compression at the tibial fracture site.⁽⁹⁾

All 6 patients with delayed union of group A were subjected to fibular osteotomy/partial fibulectomy. Out of which 4 patient were successfully managed and showed signs of healing radiologically by end of 26 weeks. Thomas *et al* studied the stresses acting on tibia and fibula using cadaveric lower limb. They found out that during loading on intact tibia the anterior surface was in continuous relative tension. This tension diminished once partial fibulectomy was done .But when a transverse fracture was made on the tibia with intact fibula, a decreased compressive force was noted, leading to formation of an anterior gap. After partial fibulectomy there was increase in compressive strain in anteriomedial surface of tibia, helping in closing of the gap.⁽¹⁰⁾

Ahmed Shawkat Rizk conducted study on 20 patients with Partial fibulectomy for treatment of tibial non-union. He concluded that Partial fibulectomy should be added to the algorithm for the treatment of tibial nonunion as it is a simple, easy, rapid, and inexpensive method to treat certain types of tibial nonunion.⁽¹¹⁾

Conclusion

Tibial fractures with intact fibula are comparatively less common then fracture of both bone. They are associated with low energy trauma. When managed with closed reduction with IM nailing, intra operative reduction is difficult especially when there is gross displacement of tibia, and are associated with residual

varus deformity. They are more proven for delayed union, non-union. Delayed union in these cases can be successfully managed with partial fibulectomy.

References

1. S. Terry Canale, James H. Beaty, "Fractures of the lower extremity: Campbell's Operative Orthopaedics"- 12th edition;3:2644.
2. Breasted JH. *The Edwin Smith Surgical Papyrus*. Chicago, IL: Univ Chicago Press; 1980.
3. Puno RM, Teynor JT, Nagano J, et al. "Critical analysis of results of treatment of 201 tibial shaft fractures" *Clin Orthop Relat Res* (1986) 212,113-12.
4. Dujardyn J, Lammens J, "Treatment of delayed union or non-union of the tibial shaft with partial fibulectomy and an Ilizarov frame" *Acta Orthop Belg* (2007), 73:630-634.
5. Ranganath KV, Arun HS, Hariprasad S, "Surgical Management of Isolated Tibial Shaft Fractures with Closed Intramedullary Interlocking Nail" *Int J Sci Stud* (2016);3(12):110-114
6. Delee JC, Heckman JD, Lewis AG." Partial fibulectomy for un-united fractures of the tibia" *J Bone Joint Surg* (1981), 63-A:1390-1395.
7. Ranganath KV, Arun HS, Hariprasad S, "Surgical Management of Isolated Tibial Shaft Fractures with Closed Intramedullary Interlocking Nail" *Int J Sci Stud* (2016) 3(12), 110-114.
8. Thomas KA, Bearden CM, Gallagher DJ, "Biomechanical analysis of nonreamed tibial intramedullary nailing after simulated transverse fracture and fibulectomy" *Orthopedics* (1997) 20, 51-57.
9. De Rover, W.B.S., Alazzawi, S., Hallam, P.J. and Walton, N.P., " Ipsilateral tibial shaft fracture and distal tibial triplane fracture with an intact fibula: a case report" *Journal of Orthopaedic Surgery*, (2011) 19(3), 364-366.
10. Thomas KA, Harris MB, Willis MC, Lu Y, MacEwen GD, "The effects of the interosseous membrane and partial fibulectomy on loading of the tibia: A biomechanical study. *Orthopedics* (1995)18, 373-83.
11. Rizk AS, "Partial fibulectomy for treatment of tibial nonunion" *Egypt Orthop J* (2014) 49, 18-23.