

Tip apex distance - Is it enough to predict implant failure in trochanteric fractures

Biswajit Sahu^{1,*}, Alok Prusty², Barsha Tudu³

¹Associate Professor, ²Junior Resident, ³Professor, Dept of Orthopaedics, VIMSAR, Burla, Odisha, India

*Corresponding Author:

Email: drbiswasahu@yahoo.com

Abstract

Introduction: The tip-apex distance (TAD) is the sum of the distances from the tip of lag screw to apex of the femoral head on both AP and lateral radiographs. A TAD of greater than 25 mm is considered to be an accurate predictor of lag screw cut-out when dynamic hip screws are used to treat intertrochanteric hip fractures. The purpose of this study was to determine the factors affecting the clinical outcomes of trochanteric fractures treated surgically.

Materials and Methods: This retrospective study included 124 patients. The TAD values of this cohort were analysed from post-operative radiographs. The fractures were classified according to severity and the post-operative reduction and their affection to cut out rates was determined. These were correlated with functional status and inability to achieve fracture union at a mean follow-up of 12 months.

Results: Good reduction was obtained in 28 cases of type 1 fractures while all the fractures which had poor reduction were type 2 fractures. All type 1 fractures united at a mean of 12 months. Overall 14 patients experienced lag screw cut-out, all of which were type 2 fractures.

Discussion: The number of cut-outs had direct correlation to the severity of fractures and the TAD. While using dynamic hip screws, surgeons should try to achieve a TAD less than 25 mm to avoid lag screw cut-out. Though TAD plays a vital role in predicting implant failure in trochanteric fractures, quality of bone, fracture pattern, placement of screw etc also influence the outcome.

Keywords: Trochanteric Fracture, TAD, Implant Failure, DHS.

Introduction

Dynamic Hip Screw (DHS) fixation has been the gold standard for treating intertrochanteric fracture of the femur since the last many years.⁽¹⁾ The technical complications experienced in DHS are either penetration or cutting by the screw due to osteoporosis of the femoral neck and head or bending and breakage of the hip nailplate due to cyclic loading of the implant, which can also lead to pulling out of the screws.⁽²⁾ Currently, varus collapse with lag screw cutout is the most common mode of failure.⁽³⁾ The predisposing factors for implant failure include unstable fractures, severe osteoporosis, poor fragment reduction or inadequate placement of lag screw.

The quality of bone for purchase within the head and neck varies from one quadrant to another. Cleveland et al divided the head of femur into nine quadrants when viewed on lateral radiograph.⁽⁴⁾ Postero-inferior and central position of screw in the femoral neck and head produced good result, whereas anterior or superior position of screw produced higher incidence of cut-out.⁽⁵⁾ The antero-superior aspect of the head and neck is of the poorest quality.⁽⁶⁾ From a surgical technique perspective, a tip apex distance (TAD) less than 25 mm, as described by Baumgaertner has been suggested to decrease the risk of cutout.⁽⁷⁾

than three months of follow-up, type 3 and 4 Boyd & Griffin fractures and those with pathological fractures of the femur were excluded. There were no exclusions based on age or other medical comorbidity.

Data regarding patients' age, gender, fracture type, operative side, type of implant, quality of reduction, TAD, and three-month post-operative ambulatory status was collected. Pre-operative antero-posterior (AP) and lateral radiographs were used to correctly classify each fracture using the Boyd and Griffin classification.⁽⁸⁾ The quality of reduction was evaluated on the basis of displacement and angulation, and categorised as good, acceptable, or poor. Displacement criteria were met if there was less than 4 mm of displacement on either the AP or lateral X-ray. The angulation criteria were met if the neck shaft angle was normal or in slight valgus (130–150°) and there was less than 20° of angulation on the lateral X-ray. A reduction was classified as good if it met both criteria, acceptable if it met one criteria and poor if neither criteria was fulfilled. TAD was determined by measuring the distance from the tip of the lag screw to the apex of the femoral head on both AP and lateral radiographs (Fig. 1). TAD of all cases were adjusted for magnification by multiplying the measured TAD on both AP and lateral radiographs by the ratio of the true to measured lag screw diameter.

Materials and Methods

A retrospective review of all trochanteric fracture patients treated with DHS between May 2014 and May 2016 at VIMSAR, Burla, was done. Patients with less

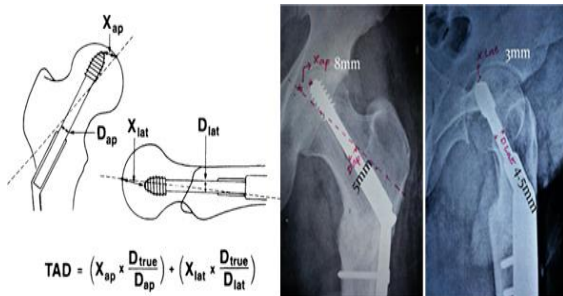


Fig. 1: Illustration of tip-apex distance (TAD) with the equation for correcting radiographic magnification

X_{ap} and X_{lat} -measured distance as illustrated on the anteroposterior and lateral X-rays, respectively.
 D_{true} -actual diameter of the lag screw used.
 D_{ap} and D_{lat} -measured diameter of the lag screw as illustrated on the anteroposterior and lateral X-rays.

Results

A total of 124 patients of type 1 and type 2 Boyd & Griffin Intertrochanteric fractures were treated with DHS during the study period. There were 80 cases of type 1 fractures and 44 cases of type 2 fractures. There were 72 males and 52 females with an average age of 65 ± 10 years.

Post-operative X-ray was done to document proper reduction and fixation of fracture fragments and for calculation of TAD. Complete weight bearing was allowed according to progression of radiological union at 3 months. The patients were followed up till union of the fracture or up to 9 months, whichever was earlier.

Good reduction was obtained in 28 cases of type 1 fractures (Fig. 2). Acceptable reduction was obtained in 52 cases of type 1 and 26 cases of type 2 fractures. There was poor reduction in 18 cases of type 2 fractures (Fig. 3).

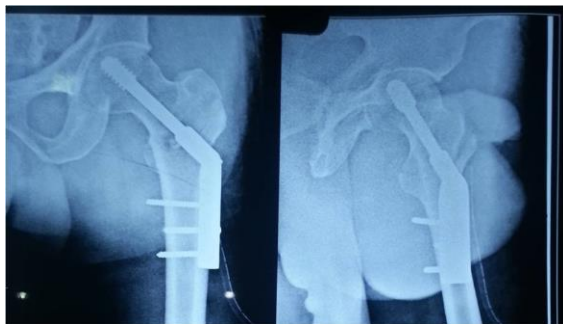

Fig. 2: No displacement on AP X ray; 2mm displacement on lateral X ray; Normal neck shaft angle on AP

X-ray : Good reduction

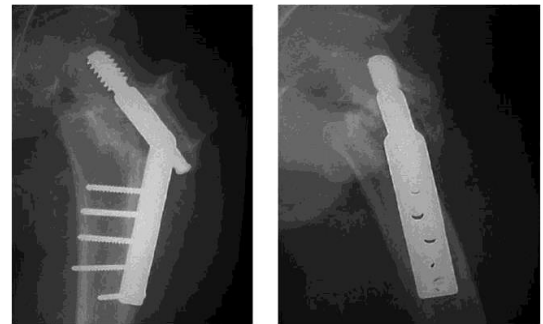


Fig. 3: >4 mm of displacement on lateral X-ray; >20 degrees of angulation on the lateral X-ray: Poor reduction

At 12 months follow-up, all type 1 fractures had united. All patients which had cut-out and non-union (n = 14) were type 2 fractures.

All fractures with good reduction had a better outcome with no cut out compared to those with poor reduction with cutout percentage of 55.56% (Graph 1)

Graph 1: Showing correlation of fracture reduction and cutout incidence

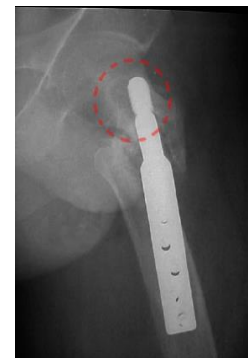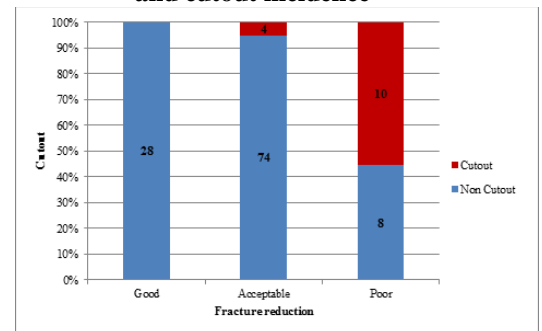
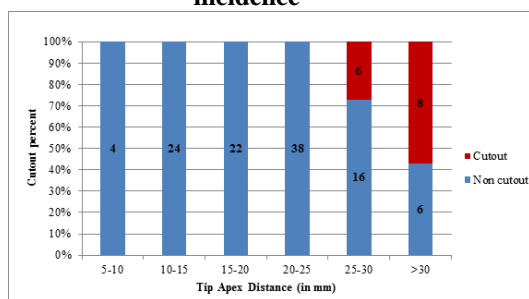


Fig. 4: Radiograph showing screw cutout in a case of TAD>25mm

Overall, there was an average TAD of $20 \text{ mm} \pm 9 \text{ mm}$ with a cut out rate of 1.2% (14 out of 124 patients). No patient with a TAD below 25 mm cut-out and 39% of patients with a TAD above 25 mm had cut-out (Fig. 4), thus providing a strong statistical relation between lag screw cut-out and TAD (Graph 2).

Graph 2: Showing correlation of TAD and cutout incidence

Discussion

Intertrochanteric fractures are increasing in incidence due to increasing number of elderly individuals. Type 1 and 2 Boyd & Griffin fractures are fixed by conventional dynamic hip screw or newer forms of intramedullary sliding devices. DHS fixation has been shown to be successful in many studies of intertrochanteric fractures. The dominant failure mode is superior migration of the lag screw, leading to varus collapse and cut-out of the lag screw from the femoral head.⁽⁹⁾ The weight-bearing portion of the acetabulum is destroyed by the screw leading to catastrophic outcomes. Early weight bearing is also detrimental in intertrochanteric fractures.

Schumpelick et al proposed that the tip of the screw should be 3-5 mm from the articular surface¹¹. Very strong statistical relationship has been found between an increased TAD and the rate of cutout. Implant failure rates increase with severity of fractures and improper reduction.⁽¹⁰⁾

This study stresses on the importance of accurate surgical technique in anatomical reduction, maintenance of the reduction and fixation of the fracture. Surgeons should strive to achieve a TAD <25mm for better results in DHS. For predicting implant failure in Intertrochanteric fractures, TAD is one of the most important criteria albeit not the only one for achieving better results. The quality of bone, pattern of fracture, placement of the screw etc also greatly influence the outcome in trochanteric fractures.

References

1. Singh AP, Kochar V. Intramedullary Nail Versus Dynamic Hip Screw; Intramedullary Nail Advantages And Disadvantages. *Trauma International* 2015 July-Sep;1(1):17-20
2. Nordin S, Zulkifli O, Faisham WI. Mechanical failure of Dynamic Hip Screw (DHS) fixation in intertrochanteric fracture of the femur. *Med J Malaysia* 2001;56(Suppl D):12-7.
3. Chua YP, Kwan MK, Ng WM, Saw A. Use of the Tip-Apex Distance in predicting Dynamic Hip Screw Cut Out in Intertrochanteric Fracture of the Femur in Asian Population. *Malaysian Orthopaedic Journal*. 5.24-27. 10.5704/MOJ.1107.006.
4. Cleveland et al, *J Bone Joint Surg Am*. 1959 Dec;41-A:1399-408.
5. Lee YS, Huang HL, Lo TY, Huang CR. Dynamic hip screw in the treatment of Inter-trochanteric fractures: a comparison of two fixation methods *Int Orthop*.2007 Oct;31(5):683-688
6. Jensen JS, Tøndevold E, Mossing N. Unstable trochanteric fractures treated with the sliding screw-plate system. A biomechanical study of unstable trochanteric fracture. *Acta Orthop Scand* 1978;49:392-7
7. Baumgaertner MR, Curtin SL, Lindskog DM, Keggi JM .The value of the tip-apex distance in predicting failure of fixation of peri-trochanteric fractures of the hip. *J Bone Joint Surg Am*. 1995 Jul;77(7):1058-64.
8. Boyd HB, Griffin LL (1949) Classification and treatment of trochanteric fractures. *Arch Surg* 58:853-866
9. Fitzpatrick DC, Sheerin DV, Wolf BR, Wuest TK. A randomized, prospective study comparing intertrochanteric hip fracture fixation with the dynamic hip screw and the dynamic helical hip system in a community practice. *The Iowa Orthopaedic Journal*. 2011;31:166-172.
10. Schumpelick W; Jantzen PM. A new principle in the operative treatment of trochanteric fractures of the femur. *J Bone Joint Surg Am*, 1955 Jul;37(4):693-698.

Note: This research did not receive any specific grant from funding agencies in the public, commercial, or not-for-profit sectors.