

## Unusual presentation of the wartenberg syndrome as writers cramp

Shailesh Gupta<sup>1</sup>, Gaurav Jain<sup>2,\*</sup>

<sup>1</sup>Consultant, <sup>2</sup>Resident, Dept. of Orthopaedic, Arihant Hospital, Indore, India

\*Corresponding author:

Email: dr.gaurav.jain09@gmail.com

### Abstract

A 57 year old male, clerk by profession, presented to us with complaints of right thumb pain with limitations of movements at thumb, thinning of the thumb and deformity of nail.

The patient had right thumb pain in doing his clerical work i.e. writing, holding files etc. typical of writers cramp. He started to experience disturbance in sleep due to pain that was radiating over the radial aspect of the hand & progressively increasing. On local examination, there was atrophy of the pulp of the thumb (Fig. 1) with relative paleness), clubbing of the nail, hardly any movement at interphalangeal joint (active or passive), swelling over the 1<sup>st</sup> MCP joint, tender with crepitus on movement, with no redness or local rise of temperature. Routine blood and urine investigations were within normal limits. X-ray of the thumb showed osteopenia of the metacarpal & phalanges, with metaphyseal cystic lesion of the 1<sup>st</sup> metacarpal distal end & flattening of 1<sup>st</sup> metacarpal head. There was narrowing of the 1<sup>st</sup> MCP joint space with few osteophytes around 1<sup>st</sup> MCP joint (Fig. 2). Hence to rule out a possible vascular pathology, investigation such as colour doppler, peripheral oxygen saturation were done. A trial of peripheral vasodilator gave no relief to the patient. The MRI of hand, forearm and arm, rule out any space occupying lesion causing compression over the anterior interosseous nerve. The nerve conduction study and electromyography also showed normal pattern.

Considering the severity of pain and low threshold for stimulation. Thus a pathology of superficial radial nerve was sought. Hence a trial block of superficial radial nerve at mid forearm level was given. With immediate effect the patient's pain was relieved and his movements at thumb were painless. A review of literature located one article with a case series of wartenberg syndrome, initially presented as writer's cramp. With this idea the exploration of superficial radial nerve was planned. Intra-operatively no space occupying lesion was found. Instead the superficial radial nerve was entrapped near its point of exit beneath Brachioradialis's tendinous portion (Fig. 3). The nerve was explored till 2/3<sup>rd</sup> of the forearm and was freed from the surrounding.

Because of the 1<sup>st</sup> MP joint advance arthritis arthrodesis of this joint was done in same sitting (Fig. 4). The patient was given 4 weeks of thumb spica and later only MP joint immobilization was done using Aluform splint till union.

At one year followup the patient is pain-free with negligible improvement in thumb appearance (Fig. 5.1, 5.2).

A 57 year old male, clerk by profession, presented to us with complaints of right thumb pain with limitations of movements at thumb, thinning of the thumb and deformity of nail.

Symptoms started 4 years ago with right thumb pain in doing his clerical work i.e. writing, holding files etc. He could not write more than five lines in one sitting (typical of writers cramp). The pain which was initially intermittent in nature, aggravated with writing, gradually becoming continuous. He started to experience disturbance in sleep due to pain that was radiating over the radial aspect of the hand. With time, pain became so disabling that the patient avoided using his right thumb. The patient did not give any history of trauma, insect bite, thorn prick, joint pain, or morning stiffness. Patient had no co-morbidity. On local examination, there was atrophy of the pulp of the thumb (Fig.1) with relative paleness (SpO<sub>2</sub> was 99%), clubbing of the nail, hardly any movement at interphalangeal joint (active or passive), swelling over the 1<sup>st</sup> MCP joint (synovitis), tender with crepitus on movement, with no redness or local rise of temperature. Routine blood and urine investigations were within normal limits. X-ray of the thumb showed osteopenia of the metacarpal & phalanges, with metaphyseal cystic lesion of the 1<sup>st</sup> metacarpal distal end & flattening of 1<sup>st</sup>

metacarpal head. There was narrowing of the 1<sup>st</sup> MCP joint space with few osteophytes around 1<sup>st</sup> MCP joint (Fig. 2). With the clinical presentation (atrophy of pulp and pain, diffuse pain in radial aspect of hand, continuous pain in radial aspect of the hand) a pure 1<sup>st</sup> MCP joint arthritis did not seem to be the underlying cause. Hence to rule out a possible vascular pathology, investigation such as colour Doppler, peripheral oxygen saturation were done. A trial of peripheral vasodilator gave no relief to the patient. The patient was then subjected to the MRI of hand, forearm and arm, to rule out any space occupying lesion causing compression over the anterior interosseous nerve (specifically examined in view of minimum function of the FPL) but the MRI report was normal. The nerve conduction study and electromyography also showed normal pattern.

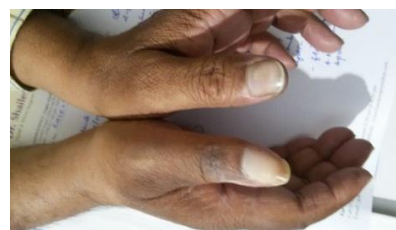

Fig. 1

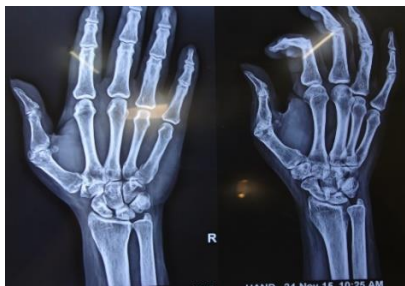

Fig. 2

We sought for Rheumatologist opinion but they ruled out any connective tissue disorder. Then a biopsy of the 1<sup>st</sup> MCP joint was taken to rule out crystal arthropathy, tuberculosis or infection. The reports came to be chronic inflammation with no sign of any of the above mentioned disease.

Considering the location, severity of pain and low threshold for stimulation, pathology of superficial radial nerve was sought the radial nerve gives a superficial branch nerve after crossing the lateral humeral epicondyle, which enters subcutaneous tissue between the tendons of the brachioradialis and the extensor carpi radialis longus in the mid-forearm. The usual site for the compression is where the tendons of the brachioradialis and extensor carpi radialis longus approximate. Hence a trial block of superficial radial nerve at mid forearm level was given. With immediate effect the patient's pain was relieved and his movements at thumb were painless. A review of literature located one article with a case series of wartenberg syndrome, initially presented as writer's cramp. With this idea the exploration of superficial radial nerve was planned. Intra-operatively no space occupying lesion was found. Instead the superficial radial nerve was entrapped near its point of exit beneath Brachioradialis's tendinous portion (Fig. 3). The nerve was explored till 2/3<sup>rd</sup> of the forearm and freed from the surrounding.

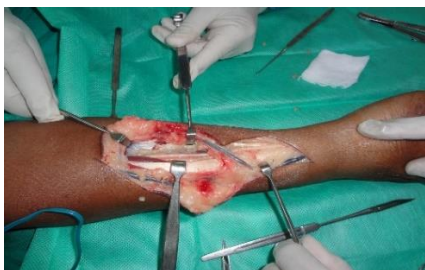

Fig. 3

Because of the 1<sup>st</sup> MP joint advance arthritis arthrodesis of this joint was done in same sitting (Fig. 4). The patient was given 4 weeks of thumb spica and later only MP joint immobilization was done using Aluform splint till union.

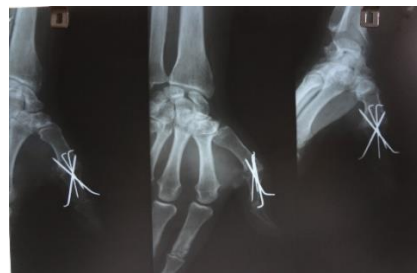

Fig. 4

At one year followup the patient is pain-free with negligible improvement in thumb appearance (Fig. 5.1, 5.2).



Fig. 5.1

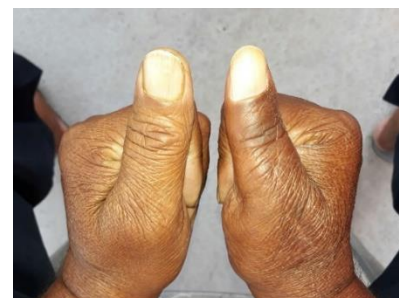


Fig. 5.2

## Discussion

Superficial radial nerve uncommonly suffer the compressive insult leading to neuropathy. Since wartenberg in 1932 described the entrapment of the SRN, the understanding of the pathology has improved with time.<sup>(1)</sup> The cadaveric studies showed that SRN also exhibit anatomical variation.<sup>(2)</sup> Intraneural as well as extraneural space occupying lesion may mimics wartenberg syndrome.<sup>(3)</sup> Walter Ehrlich et al reported a case who presented as writers cramp.<sup>(4)</sup> We found that the unusual way of presentation of wartenberg syndrome with interphalangeal joint arthritis, clubbing of nail and pulp atrophy of thumb created a lot of confusion for diagnosis. The art of taking detailed history should be of prime importance and is key for making diagnosis. Reviewing literature helped us in making correct diagnosis. We feel that cases of writer's cramp should be evaluated for wartenberg syndrome.

## References

1. Wartenberg R. Cheiralgia paresthetica, Neuritis des Ramus. Superficialis nervi radialis, Z Neurol Psychiatr 1932;141:145-55.

2. Davidovich ER, Nascimento OJ, Superficial radial nerve-lateral antebrachial cutaneous nerve anatomic variation, *Brain Behav*, 2014 Jan;4(1):70-4. doi: 10.1002/brb3.195. Epub 2013 Dec 1.
3. Balakrishnan CI, Bachusz RC, Balakrishnan A, Elliot D, Careaga D, Intraneural lipoma of the radial nerve presenting as Wartenbergsyndrome: A case report and review of literature, *Can J Plast Surg*. 2009 Winter;17(4):e39-41.
4. Walter Ehrlich, A. Lee Dellon, Susan E. Mackinnon, Cheiralgia paresthetica (entrapment of the radial sensory nerve), *Journal of Hand Surgery*, Vol. 11, Issue 2, p196-199. Published in issue: March 1986