

Study of clinical outcome in posterior plating for fibula in bimalleolar fracture ankle

Shriniwas Yemul¹, Pravin Narote^{2,*}

¹Associate Professor, Dept. of Orthopaedics, Ashwini Rural Medical College, Hospital and Research Centre, Solapur, Maharashtra, ²Consultant Orthopaedics Surgeon, Dept. of Orthopaedics, Chandan Neurosciences Hospital, Solapur, Maharashtra, India

***Corresponding Author:**

Email: pravin.narote@yahoo.com

Abstract

Introduction: The anatomy of the joint makes it very unstable in cases of fractures or ligamentous injuries of the ankle, because the whole body weight is transmitted through the ankle and locomotion depends upon the stability of the ankle joint. In the post-operative period, the protocol of mobilization of the ankle has been a topic of conflict. The goals of treatment include achieving sound union of fracture and an ankle that moves and functions normally without pain.

Materials and Methods: This is prospective consecutive case series of 60 patients of bimalleolar ankle fracture, undergone internal fixation in the form of plate fixation over posterior surface of fibula for lateral malleolus and cancellous screw fixation for medial malleolus. Data collection was done using history sheet, clinical examination, and radiological examination at intervals while functional outcome was assessed at follow up visits using Weber's assessment protocol.

Results: 50 (83.3%) cases radiological union is achieved by 6 weeks while 10(16.7%) cases union time was 10 weeks. Average time for union was 6.7 weeks. The final outcome as per the Weber's assessment protocol was 50% as excellent, 40% as good and 10% as poor result which showed good correlation with level of reduction achieved graded from immediate post-operative radiographs.

Conclusion: Accuracy of reduction and rigid fixation was found to be a major determinant of functional outcome irrespective of the type of fracture. Posterior plate fixation gives bicortical screw purchase leading to secure fixation, no intra-articular penetration, decreased complications, hardware prominence and wound dehiscence.

Keywords: Bimalleolar ankle fracture, Weber's assessment, Lateral malleolus, Kristensen grade, Lauge-hansen classification.

Introduction

Ankle fractures are one of the most common injuries treated by orthopedic surgeons. Ankle fractures have been the subject of numerous studies and articles regarding the mechanism of injury, classification and treatment modalities.

There has been an increase in the prevalence of such fractures over the last two decades both in the young, active patients and in the elderly.^{1,2}

Most ankle fractures are complex injuries that are difficult to manage. These injuries gain importance because the whole body weight is transmitted through the ankle and locomotion depends upon the stability of the ankle joint. They have the potential to produce significant long-term disability and complications in the form of pain, instability and early degenerative arthritis.³

As a result of a better understanding of the biomechanics of the ankle, improvements in fixation techniques and findings of outcome studies, there has been a gradual evolution in the effective strategies for the treatment of ankle fractures. The goals of treatment include achieving sound union of fracture and an ankle that moves and functions normally without pain. It has been shown experimentally by Paul L. Ramsey that about one mm lateral shift in talus produces about 42 per cent of decrease in tibio-talar contact area.⁴ This obviously shows the need for perfect anatomical reduction which

could be better achieved by open reduction and better maintained by internal fixation.

The final outcome of a fractured ankle is of prime importance, as the treatment should benefit the patient just not in short term but also in the long term. The treatment of fractures has its challenges in cases where the fracture is complicated by co-morbid conditions such as Diabetes mellitus, peripheral vascular diseases and neuropathic conditions which complicates the treatment and influences the overall outcome. A thorough understanding of the ankle anatomy, mechanism of the injury, interpretation of the radiographs and adherence to basic principles of fracture management are the basis for a good result. Considering all of the above facts, we have planned to evaluate the results of bimalleolar fractures treated at hospital.

Materials and Methods

This is a prospective case series study carried out on the patients with bimalleolar fracture ankle, attending the emergency/outdoor and indoor services with minimum follow up period of six month and maximum up to 2 years at ARMCH & RC, who gave their informed consent to undergo the procedure under anesthesia and participation in the study. Sixty such patients were included in the study. Patients admitted to this hospital were in the age group 20 yrs. to 75 yrs.

Exclusion Criteria: Patients with co-morbid conditions preventing surgical intervention, more than 3 weeks duration of injury, immature skeleton, local tissue condition preventing or prolonging immediate surgery, Pilon fractures, posterior malleolar fractures. The entire lower leg, including the full length fibula was examined. Patients were stabilized haemodynamically and were administered adequate analgesia. Antero-posterior x-ray was taken in line with the second ray of the foot. The lateral view was obtained with the tibia perpendicular to the long axis of the foot and the beam was centered on the talus.⁵

For assessment of the LCL complex, an anterior drawer lateral view was obtained with the foot supported by a pad under the heel and a posteriorly directed force applied to the distal tibia. Brostrom claimed that as little as 3-mm anterior talar displacement indicates LCL rupture.⁶ Injury to syndesmosis was seen commonly in PER, PA and some SER type of injury in which lateral displacement of the talus and widening of distal syndesmosis was noted on stress view.⁷ The fractures were classified according to the Lauge-Hansen's classification⁸ depending on radiological assessment. Informed consent for the surgical procedure was obtained. Antibiotics were administered at the time of induction of anesthesia. The patient was placed in supine position with a sand bag under the ipsilateral buttock. The affected limb was prepared with a primary scrub with betadine. The parts were then painted with betadine and spirit. The reconstruction of the fibula was given priority and therefore the lateral side was dealt with before the medial side.⁹

Approach to the Lateral Malleolus: A 10 to 15-cm longitudinal incision was made along the posterior border of the fibula all the way to its distal end and continuing for a further 2 cm, centering the incision at the level of the fracture. Full thickness skin flap was created up to peroneal fascia. Injury to superficial peroneal nerve was avoided by retracting it along with muscles. Fracture site was opened by gentle distraction, re-creating the mechanism of injury, and organized hematoma was drained and periosteum was elevated at fracture site.

Implants: The implants used for the fixation of fractures were as follows:

The medial malleolus was fixed with 4mm cancellous screws in 60 cases. Of which six were single screw and additional k-wire due to small fragment while other 54 cases two screws were used. The lateral malleolus was fixed with Dynamic compression plate in all 60 patients.

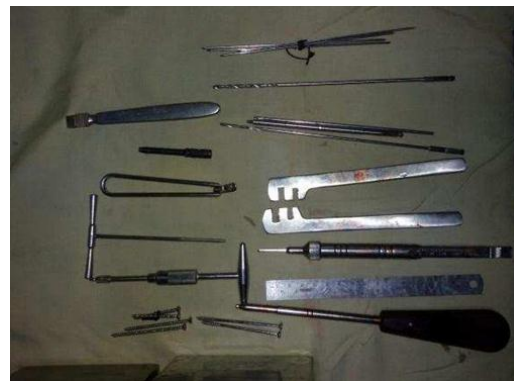

Fig. 1: Basic instrument set



Fig. 2: Image showing Power drill

System and Implants



Fig. 3: DCP and 3.5mm cortical screw set and cancellous screws

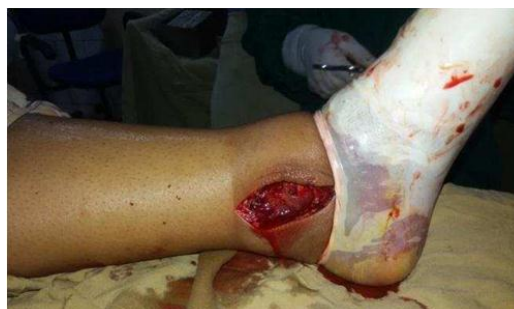

Fig. 4: Medial malleolus exposure

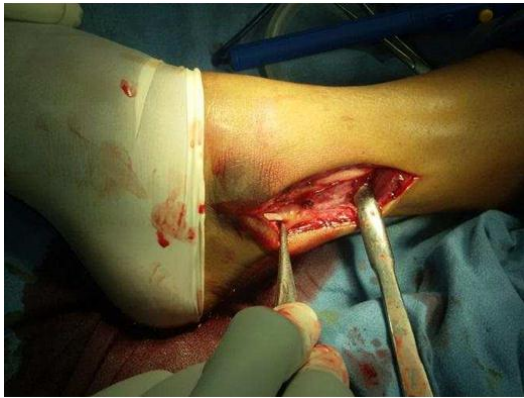

Fig. 5: Lateral malleolus exposure

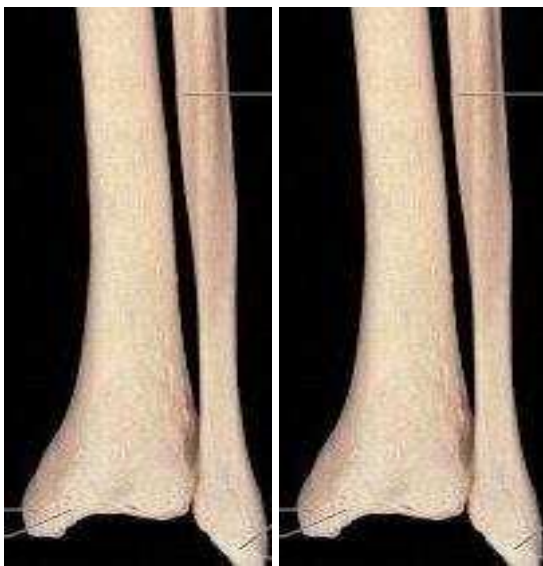


Fig. 6: Shape of distal fibula and contouring of plate

Reduction and Fixation

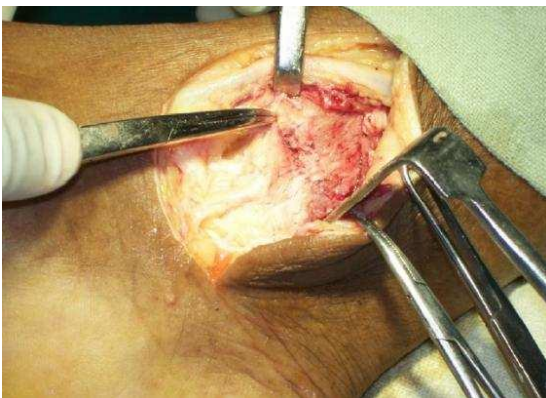


Fig. 7: Medial malleolus reduction

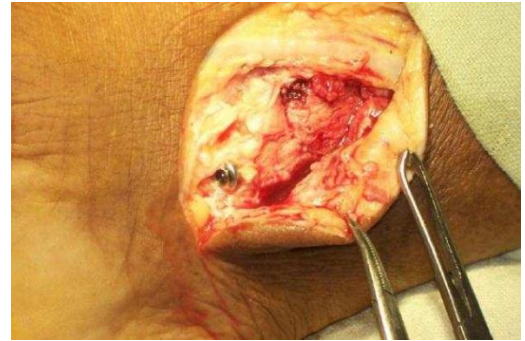


Fig. 8: Medial malleolus fixation

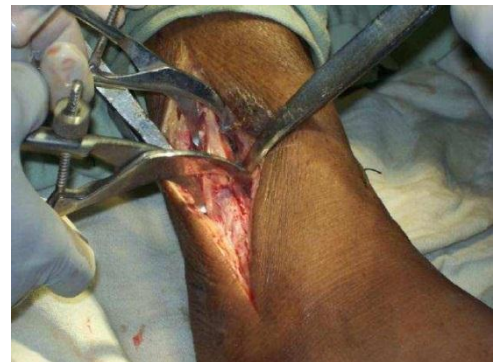

Fig. 9: Lateral malleolus reduction

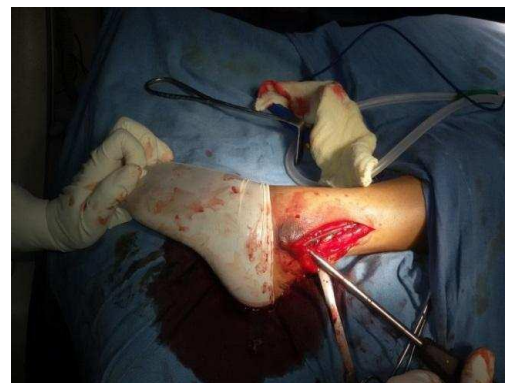

Fig. 10: Lateral malleolus fixation

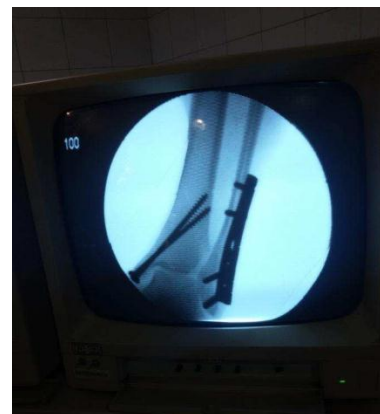

Fig. 11: Post-operative intensifier image

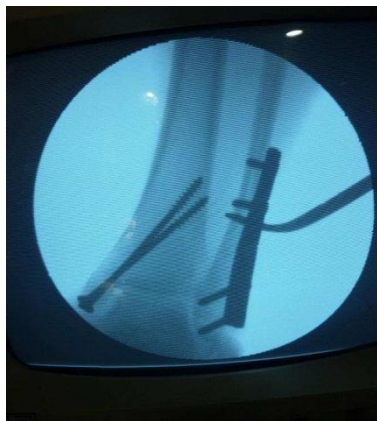

Fig. 12: Cotton test for syndesmotic

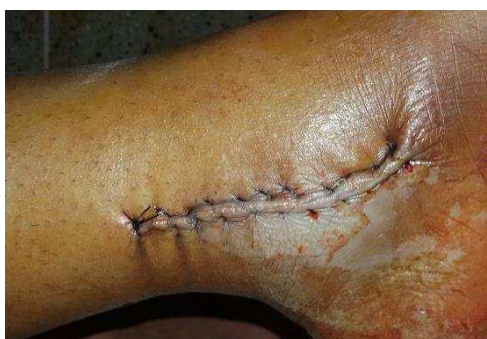

Fig. 13: Medial Malleolus Closure

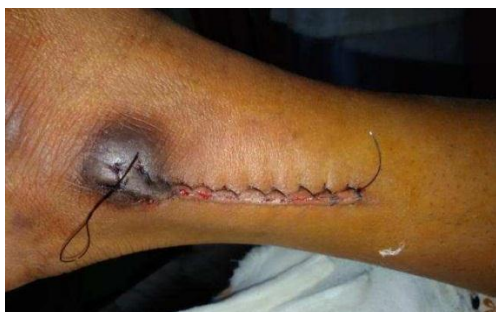

Fig. 14: Closure of lateral malleolus

Approach to the medial Malleolus: A 10-cm longitudinal curved incision on the medial aspect of the ankle, with its midpoint just anterior to the tip of the medial malleolus was made. Periosteum was elevated at fracture site and edges were freshened. Reduction was done under direct vision and periosteum interposition between fracture edges was avoided. Medial malleolus was fixed with partially threaded 4mm cancellous screws directed obliquely upwards.

Syndesmosis Transfixation: Decision regarding syndesmotic fixation was made after fixation of medial and lateral malleolus depending upon intra-operative fluoroscopic picture. Cotton's test⁵ was done to find out syndesmotic instability. The reduction of the tibio-fibular joint was maintained during placement syndesmotic screw with clamps. The fixation screw was used independently or in conjunction with a

plate, depending on the type and location of the fibular injury.

Post-op: Patients were administered adequate analgesics. I.V. Antibiotics were administered for 72 hours postoperatively followed by oral antibiotics for 7 days. Radiological assessment of reduction was done using modified Kristensen's criteria¹⁰ post operatively. The criteria for the radiological assessment of reduction were given by Good, Fair and Poor.

Sutures were removed at follow up in the outpatient clinic at 11th post-operative day. Patients were advised to continue toe-touch weight bearing ambulation with a walker for a period of 6 weeks. However in patients who had other associated injuries, ambulation was delayed or mobilized on a wheelchair. Radiographs were done at six weeks. Presence of callus and status of the joint was noted. Partial weight bearing with support was started depending upon radiographic findings, where patients were allowed to put up to 50% of the body weight.

Patients were followed up at 10 weeks after which foot flat weight bearing as tolerated with walker support was started where patients were allowed to put more than 50% of the body weight as tolerated. Patients were followed up monthly up to six months and yearly thereafter.

At each assessment, all patients were questioned with regard to pain, use of analgesics, stiffness, swelling, activities of daily living, use of walking aids, and return to work and participation in sports. At examination, the gait, any thickening, swelling, tenderness of the ankle and the range of motion of the ankle and subtalar joint were evaluated. Antero posterior and lateral radiographs of ankle were made at the time of examination. The patients were evaluated as per the rating of the Weber's functional assessment protocol.¹¹

Statistical Analysis: Descriptive statistics such as mean, SD and percentage were used to present the data. Comparison between categorical variables was done by using Fisher's exact test. Association between categorical variables was tested by using chi-square (χ^2) test. A p-value less than 0.05 were considered as significant. Analysis of data was carried out using Software Package for Social Sciences (SPSS v.16).

Showing Excellent Outcome

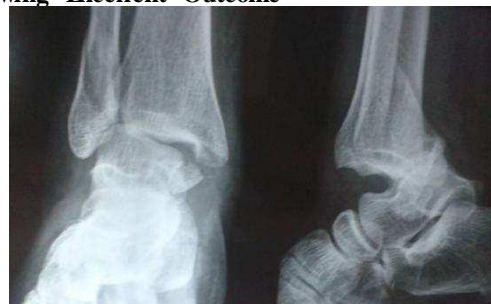

Fig. 15: Antero-posterior

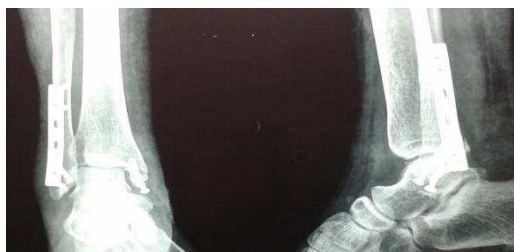

Fig. 16: Antero-posterior and lateral view Radiograph pre-op lateral view radiograph post-op

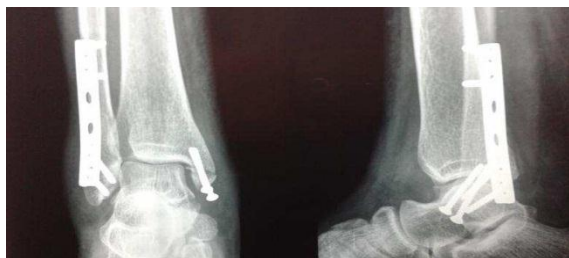

Fig. 17: Antero-Posterior and lateral view radiograph at 6-week

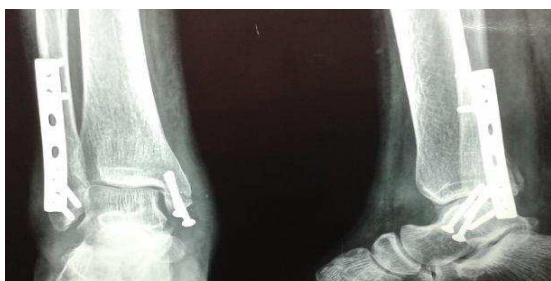

Fig. 18: Antero-posterior and lateral view radiograph at union 10 week

Results

In the present study, majority of the cases i.e. 31(51.67%) were in the age group of 21-30 years, followed by 10 (16.67%) cases in the age group 31-40 years. The mean age was 36.85 years. Maximum numbers of males involved were in 21-30 age group while maximum females involved were in age group of 51-60 years. Majority of the patients were males-42 cases (70%) and 18 (30%) were females.

Table 1: Distribution of incidence of fractures according to Lauge-Hansen classification

Type	Frequency	Percentage
Pronation Abduction	2	3.3
Pronation Dorsiflexion	2	3.3
Pronation External Rotation	20	33.3
Supination Adduction	12	20.0
Supination External Rotation	24	40.0
Total	60	100.0

Supination- External rotation injury was the most common mechanism of injury observed in our study as per Lauge-Hansen’s classification comprising up to 40% of the total number.

Table 2: Level of reduction achieved over post-op radiograph

Kristensen Grade	No of patients	%
Good	40	66.7
Fair	20	33.3
Poor	0	0
Total	60	100

Post-operatively 66.7% of patients were graded as good reduction, 33.3% were as fair reduction and none of the patient was graded as poor reduction according to modified Kristensen’s criteria.¹⁰

Table 3: Time required for union after surgical management

Time for union (weeks)	Frequency	Percentage
6 week	50	83.3
10 week	10	16.7
Total	60	100.0

50 (83.3%) cases radiological union was achieved by 6 weeks while 10(16.7%) cases union time was 10 weeks. Average time for union was 6.7 weeks.

Table 4: Final outcome according to Weber’s grade

Final outcome	Frequency	Percentage
Excellent	30	50.0
Good	24	40.0
Poor	6	10.0
Total	60	100.0

30 cases (50%) were graded as excellent and 24 cases (40%) as good results. 6 cases (10%) were graded as poor outcome. All the patients who were graded as excellent and good results returned to normal activity and had regained their full ankle movements by the end of three months.

Association of Final outcome and Lauge-Hansen Classification:

In supination external rotation group 11 cases out of 24 (45.83%) were graded as excellent and 9 cases (37.50%) were graded as good while 4 cases (16.67%) as poor outcome.

In pronation external rotation group 11 cases out of 20 (55%) were graded as excellent and 7 cases (35%) were graded as good whereas 2 cases (10%) as poor outcome.

In supination adduction group 5 cases out of 12 (41.67%) were graded as excellent and 7 cases

(58.33%) were graded as good and no case in this group was graded as poor outcome.

In pronation abduction 2 cases out of 2(100%) were graded as excellent outcome.

In pronation dorsiflexion group 1 out of 2(50%) was graded as excellent and one case (50%) was graded as good outcome.

Table 5: Distribution of cases according to Lauge-Hansen Classification and outcome

Lauge-Hansen's class	Final Outcome (%)			Total
	Excellent	Good	Poor	
Pronation Abduction	2 (100)	0	0	2
Pronation Dorsiflexion	1 (50)	1 (50)	0	2
Pronation External Rotation	11 (55)	7 (35)	2 (10)	20
Supination Adduction	5 (42)	7 (58)	0	12
Supination External Rotation	11 (46)	9 (38)	4 (17)	24
Total	30	24	6	60

$$\chi^2 = 1.17, df=2, p=0.56$$

There was no statistical significant association found between final outcome and type of fracture according to Lauge-Hansen's classification ($p=0.56$). This could be attributed to smaller sample size and smaller follow up duration.

Correlation between Post-operative Reduction and final Outcome: In the present study, 40 patients were graded to have good post-op reduction while 20 patients were graded as fair reduction on immediate post-op radiographs as per the stated criterion. 30(75%) cases out of 40 with good post-operative

reduction were graded as excellent according to Weber's assessment protocol whereas 10(25%) cases achieved good functional results. None of the case with good post-operative reduction was graded as poor functional outcome.

Out of 20 cases with fair post-operative reduction, 14(70%) cases were graded as good functional results while 6(30%) cases were graded as poor results. None of the cases with fair level of post-op reduction were able to achieve excellent functional outcome.

Table 6: Correlation between Post-operative radiographic grading based on Kristensen's radiological criteria and final outcome

Post-op radiograph grade	Final Outcome (%)			Total
	Excellent	Good	Poor	
Fair	0	14 (70)	6 (30)	20
Good	30 (75)	10 (25)	0	40
Total	30	24	6	60

$$\chi^2 = 30, df=1, p<0.0001$$

The statistical association between functional outcome and level of reduction achieved on post-operative radiographs was significant with p -value <0.0001 . Level of reduction on immediate post-operative radiograph was found to correlate statistically with functional outcome. Final outcome was found as dependent over level of reduction achieved by doing open reduction and internal fixation. Adequacy of reduction can be stated as determinant of final outcome.

Discussion

Bimalleolar ankle fractures are intra-articular fractures and commonly caused by rotational forces. Most of these are displaced and unstable fractures demands accurate reduction and stable fixation. Treatment of bimalleolar fractures with accurate open reduction and internal fixation by placing plate over posterior aspect of fibula is being proven biomechanically superior.^{12,13}

The fractures of the ankle are injuries seen in the young and middle aged patients commonly. The mean age in our series was noted to be 36.85 yr. with a male predominance of 70%.

Mechanism of Injury according to Lauge-Hansen Classification: The most common mechanism of injury was Supination-external rotation injury with 40% incidence followed by pronation external rotation in 33.3% of the cases.

Supination external rotation was most common pattern observed in our study (40%). The findings were similar to observations of Roberts SR¹⁴ study, Beris¹⁵ et al study.

Radiographic Evaluation: Post operatively 66.7% of patients were classified as a good result whereas 33.3% achieved fair results with no case was graded as poor result radiologically. As most of the fractures included in the study were displaced fractures and with surgical intervention in the form of open reduction

and internal fixation we were able to get anatomical reduction in most of the cases.

Time for Union: 50 (83.3%) cases radiological union was achieved by 6 weeks while 10(16.7%) cases union time was 10 weeks. Average time for union was 6.7 weeks. No cases of malunion, non-union were noted during study. These results were comparable to Gul¹⁶ et al study in which time required to join work (union and full weight bearing without support) was calculated 54.6 15.5 days from date of injury. In that study they used lateral semi tubular plate fixation and observed one case of loss of reduction and one case of non-union. In another similar study by Simanski¹⁷ et al concluded that average time for union with early weight bearing were able to be full weight bearing was by 7 week 3 days and returned to work by 8 week 5days. Time for bone union was comparable to Gul¹⁶ et al study and Simanski¹⁷ et al study.

Jung Ho Noh¹⁸ et al in his study used immobilization short leg splint for two weeks and functional bracing for next four weeks with active assisted ankle movement followed by non-weight bearing and full weight bearing as tolerated as mobilization protocol concluded mean union time as 15.8 weeks in metallic implant group.

We concluded from our study that using DCP as osteosynthesis material had given more rigid support as compared to semi tubular plate and early weight bearing was started without risk of implant failure or loss of reduction.

Functional Outcome: In present study, based on the Weber's assessment protocol,¹¹ 50% of the patients achieved excellent functional results while 40% were good and 10% of the patient graded as poor results.

In Noe Martinez Velez¹⁹ et al study functional outcome was graded 13.63% as excellent, 81.81% as good and 4.5% as poor.

In Winkler-Weber study²⁰ 66.65% were graded as excellent, 27.95% graded as good and 5.4% were graded as poor.

In Beris²¹ et al study 74.3% were graded as good to excellent, 14.6% graded as fair and 11.1% as poor.

In Erhan Yilmaz²² et al study 58% were graded as good to excellent, 26% graded as fair and 16% as poor.

Results of the present study are closely comparable to Winkler-Weber²⁰ study. The functional results were better than that of Noe Martinez Velez¹⁹ et al where they obtained 13.63% results as excellent and 81.81% results as good outcomes. This was observed because Noe Martinez Velez¹⁹ et al study included patients with injury less than 2 weeks whereas present study maximum patients were operated within 24 hours. Poor outcome of present study was 10%, was found to be comparable with Beris²¹ et al study

which had poor outcome in 11.1% of the cases and Erhan Yilmaz²² et al study, who observed poor outcome as 16% of cases. It was observed to be more than Noe Martinez Velez¹⁹ et al study (4.5%), Winkler-Weber²⁰ study (5.4%), which could be attributed to period of post-operative immobilization in plaster cast for six weeks in those studies while in present study, no immobilization and early weight bearing was practiced.

In the present study, 40 patients were reported to be having good post-op reduction while 20 patients had fair reduction on immediate post-op radiographs.

30(75%) cases out of 40 with good post-operative reduction were noted to have excellent outcome according to Weber's assessment protocol¹¹ whereas 10(25%) noted to achieve good functional results. None of the case with good post-operative reduction was noted to have poor functional outcome.

Out of 20 cases with fair post-operative reduction, 14(70%) cases noted to have good functional results while 6(30%) cases achieved poor results. These results were statistically significant with p-value of <0.0001. Quality of reduction based on immediate post-operative radiograph was found to be closely correlating with final functional outcome and could be used as one of the predictor of excellent outcome.

Conclusion

Accuracy of reduction and rigid fixation was found to be a major determinant of functional outcome irrespective of the type of fracture. Posterior plate fixation gave bicortical screw purchase leading to secure fixation, early post-operative mobilization and early weight bearing, decreased complications, reduced intra-articular screw penetration, hardware prominence and wound dehiscence. Early post-operative mobilization and early weight bearing had led to early functional recovery.

References

1. Bauer M, Benger U, Johnell O. Supination-eversion fractures of ankle joint: Changes in incidence over 30 years. *J Foot Ankle* 1987;8:28-8.
2. Daly PJ, Fitzgerald RH, Melton LJ, Lstrup DM. Epidemiology of ankle fractures. *Acta Orthopaedica Scandinavian* 1987;58:539-44.
3. Carragee EJ, Csongradi JJ, Bleck EE. Early complications in the operative treatment of ankle fractures. *J Bone Joint Surg* 1991;73B: 79-82.
4. Ramsey PL, Hamilton W. Changes in tibiotalar area of contact caused by lateral talar shift. *J Bone Joint Surg (Am)* 1976;58A:356-357.
5. Marsh JL, Saltzman CL. Ankle fractures. In: Bucholz RW, Heckman JD and Court-Brown CM, editors. *Rockwood and Green's fractures in adults*, Vol.2, 6th ed. Lippincott;2006:p2148-2202.
6. Brostrom L. Sprained ankles: Anatomic lesions in recent sprains. *Acta Chir Scand* 1964;128:483.

7. Pankovich AM. Fractures of the fibula proximal to the distal tibiofibular syndesmosis. *J Bone Joint Surg Am* 1978;60:221-229.
8. Matthew I. Rudloff. Fractures of lower extremity. In: Canale ST and Beaty JH editors. *Campbell's Operative Orthopaedics*. Vol. 3, 12th ed. Mosby; 2008:p2617-28.
9. De souza LJ. Fractures and dislocations of ankle. In: Gustilo RB, Kyle RF, Templeman D, editors. *Fractures and dislocations*. St.Louis: Mosby; 1993:p.997-1043.
10. Gregory Joy, Michael J Paizakis, Paul J Harvey Jr. Precise evaluation of the reduction of severe ankle fractures, technique and correlation with end results. *J Bone Joint Surg (Am)* 1974;979-93.
11. Hughes JL et al. Evaluation of ankle fractures. *CORR* 1979 January; 138:111.
12. Marcelo Mercadante et al, Biomechanical Study: Resistance Comparison of Posterior Antiglides Plate and Lateral Plate on Synthetic Bone Models Simulating Danis-Weber B Malleolar Fractures. *Rev Bras Ortop* 2013;48(3):221-227.
13. Manoli et al. Antiglides plate for distal fibular fixation. *J Bone Joint Surgery (Am)* 1987 April;69A(4):595-605
14. Roberts RS. Surgical treatment of displaced ankle fractures. *Clin Orthop* 1983;172:164-70.
15. Beris AE, Kabbani KT, Xenakis TA, Mitsionis G, Soucacos PK, Soucacos PN. Surgical treatment of malleolar fractures - a review of 144 patients. *CORR* 1997 Aug;341:90-8
16. Arif Gul, Nick Gillham et al. Immediate unprotected weight bearing of operatively treated ankle fractures. *Acta Orthop Belg* 2007;73:360-365.
17. Simanski et al Functional Treatment and Early Weight bearing After an Ankle Fracture: A Prospective Study. *Journal of Orthopaedic Trauma* 2006 Feb;20 (2):108-114.
18. Jung Ho Noh et al. Outcome of operative treatment of unstable ankle fractures: comparison of metallic and biodegradable implants. *J Bone Joint Surgery (Am)* 2012;94:e116 (1-7)
19. Noe Martinez Velez, et al. Posterior antiglide plate vs. lateral plate to treat Weber type B ankle fractures. *Acta Ortopedica Mexicana* 2004; 18(Suppl. 1): Jul.-Dec:S39-S44.
20. Winkler B, Weber BG, Simpson LA. The dorsal antiglide plate in the treatment of Danis-Weber type B fractures of the distal fibula. *Clin Orthop* 1990;(259):204-209.
21. Beris AE, Kabbani KT, Xenakis TA, Mitsionis G, Soucacos PK, Soucacos PN. Surgical treatment of malleolar fractures - a review of 144 patients. *CORR* 1997 Aug;341:90-8
22. Erhan Yilmaz et al. The results of surgical treatment in ankle fractures. *Acta orthop Traumatol Turc* 2002;36:242-247.