

# Comparative Study of Tricortical versus Quadricortical Syndesmosis Fixation in Ankle Fractures

Sachin Jain<sup>1,\*</sup>, Dinesh Sonkar<sup>2</sup>, Sunil Rajan<sup>3</sup>

Dept. of Orthopaedics & Traumatology, GR Medical College, Gwalior, Indore

\*Corresponding Author:

Email: drsachinjainortho@gmail.com

## ABSTRACT

**Objective:** To assess short-term functional results in 2 types of syndesmotic fixation, comparing the traditional rigid quadricortical syndesmotic screw fixation with a more dynamic tricortical screw fixation.


**Method:** *PATIENTS:* Thirty nine patients (Age group: 20 to 50 yr) with closed ankle fractures in which the syndesmosis was found to be unstable clinically, radiographic and confirmed intra operatively. *INTERVENTION:* The unstable syndesmoses were fixed with either one cortical screw through both tibial cortices (n = 18) QSF or two cortical screws engaging only 1 cortex of the tibia (n = 21) TSF. The quadricortical and the tricortical screws were removed only in the case of discomfort. However, all quadricortical screws were removed at 6 month follow up. Rehabilitation was the same in both groups. *DESIGN:* Prospective, randomized single blinded clinical study. *SETTING:* Department of orthopaedics and traumatology MGM Medical College & M Y Hospital Indore. And G.R. Medical College & Jayarogya Hospital, Gwalior.

**Results:** At the end of three months mean OM score was 65.35 (55 to 75) For TSF group as compared to 59.58 (55 to 65) in QSF group. Mean values were similar between the two groups with respect to pain, swelling, support, running and jumping. The overall difference noted in two groups was due to difference in Mean value for functional parameter like stair climbing, Squatting and activities of daily living. At six months there was no significant difference in any parameter of OM score. Hence the overall scores were with non-significant difference {TSF 76.42 (70 To 80) and QSF 72.42 (65 to 80).

A three months DID was 12.07 (9 to 17) in TSF and 9.75 (6 to 13) in QSF with significant difference in two groups. At six months difference was non significant 4.75 for TSF and 4.42 for QSF Group. The one set of tricortical screws and two Quadricortical were removed in patients due to infection. Quadricortical group was re-operated in 3 (16.66 %) cases for screw removal in case of screw breakage before 6 month follow up. While one set of tricortical screws were removed due to loosening. All removal was done after 4 months as all fractures shown clinical and radiological union at 3 months.

**Conclusions:** In this study confirmed that Syndesmosis fixation with 2 tricortical screws is safe and improves early function. After 6 months, however, there were no significant differences between the 2 groups in functional score, pain, and dorsiflexion.

**Keywords:** DID: Difference in dorsiflexion, OM Score: Olerud Molander Score QSF quadricortical screw fixation TSF Tricortical screw fixation

Access this article online	
Quick Response Code:	Website: www.innovativepublication.com
	DOI: 10.5958/2395-1362.2015.00014.6

## INTRODUCTION

Ankle fracture injuries are common with incidence of approx. 107-187 per 100000 person year.<sup>1,2</sup> Previous clinical investigations have identified certain factors associated with poor prognosis after the operative management of unstable ankle fracture. Ankle injuries about the ankle joint cause destruction of not only the bony architecture but also often of the ligaments and syndesmosis. Approximately 5% to 10% of all ankle sprains<sup>3,4</sup> and 10- 23% of all ankle fractures<sup>5</sup> involve trauma to the distal tibiofibular syndesmosis. Currently, however, 17% to 74% of ankle injuries among young athletes are associated with distal tibio fibular syndesmosis injuries.<sup>(5)</sup> This apparent increase in the

incidence of syndesmosis injuries can be attributed to an increase in knowledge, understanding, and awareness of syndesmosis injuries. The coexistence of osseous or deltoid ligament injuries can critically destabilize the ankle. The 2 most common mechanisms of such injury are external rotation<sup>6,7,12</sup> and hyperdorsiflexion<sup>6,7,8-11</sup>. Other reported causes of syndesmosis injury are eversion,<sup>12,13</sup> inversion<sup>12</sup>, plantar flexion,<sup>14</sup> pronation, and internal rotation.

The tibia and fibula spread on the talus, the ankle mortise is disrupted and the ankle can become very unstable. With 1 mm lateral shift of talus joint surface pressure increases by 42% i.e. reduces Weight bearing area by 20-40%<sup>(15)</sup>. (Section of the AITFL (antero inferior tibio fibular ligament) gives diastasis of 2.3 mm; section of AITFL + IOL (interosseus ligament) give diastasis of 4.5 mm; all 3 ligaments are sectioned, it measures 7.3 mm.)

Accurate restoration of the ankle mortise and stable fixation of the disrupted syndesmosis are essential for optimum functional outcomes.<sup>16</sup> Syndesmotic injuries can be associated with a syndesmotic-level (Danis-Weber type B injury) or

supra-syndesmotic level (Danis-Weber type C injury) fracture of the fibula. The Weber type C ankle fractures is considered most commonly associated with instability of the syndesmosis.<sup>17</sup> Hence in this study, We reviewed our experience with Weber type-C fractures with syndesmotic injuries to examine factors which affect the final functional result.

Ankle fracture Classification	
<b>Weber A</b>	= Lauge Hansen Supination adduction
<b>Weber B</b>	= Lauge Hansen Supination exorotation
<b>Weber C</b>	= Lauge Hansen Pronation exorotation

The conventional method has been putting a screw through fibula engaging all four cortices. It is reported to decrease the range of movement and has to be removed before weight bearing started. Other Reports promotes two screws through fibula and engaging only one cortex of tibia. It is considered to be better in functional outcome and patient compliances. To confirm it we conducted study where functional outcome recorded in both groups after allowing the patient to bear weight without screw removal.

#### PATIENTS AND MATHODS

This was a prospective randomized control study. All patients who sustained ankle fracture requiring surgical intervention at our institutes were entered into a database and followed. At the time of hospital admission, a baseline radiological and clinical evaluation was done. All fractures were classified according to the OTA-Weber classification.

Weber type c with supra syndesmotic fracture and associated syndesmotic injury were selected. They were randomized simply by even and odd numbers, those patients with odd numbers were divided into tricortical screw fixation (TSF) Group and those with even numbers were divided in quadricortical screw fixation (QSF) group. All operations were performed by same qualified orthopaedic surgeon. At the time of surgery American society of anesthesiologist (ASA) classification of operative risk, injury characteristics (including mechanism of injury and mortice displacement measured as widening of medial joint space, syndesmotic space widening & tibio-fibular overlap), and stress view and pulling (Hook) test in image intensifier (for confirmation of syndesmotic injury) were recorded in the database. In Hook test we pull the fixed fibula with bone hook laterally & anteroposteriorly under fluoroscope and look for the maximum possible diastasis. (Briggs et al (2004)<sup>(18)</sup> suggested the main direction of instability is anteroposterior rather than laterally.) Accurate assessment of length and rotation is possible with intra-operative imaging of the involved ankle joint. The medial clear space, tibiofibular overlap, and tibio fibular clear space need to be accurately restored in the mortise view.<sup>(15)</sup> The dense subchondral bone of the distal tibia should be at the same level as a small spike seen on the fibula, with an unbroken Shenton line of the ankle.<sup>(19)</sup> It would be wise to get lateral imaging of the ankle as well and comparison views of the normal ankle to achieve the required result

Also recorded was each patients' post operative complications such as medical, surgical, infection, the physiotherapy sessions, duration of splint support, functional out come at 3 and 6 months, ankle instability, time for partial and full weight bearing mobilization, implant failure, early sign of osteoarthritis.

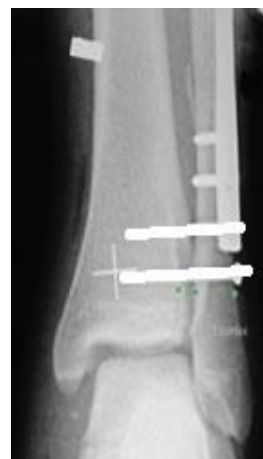
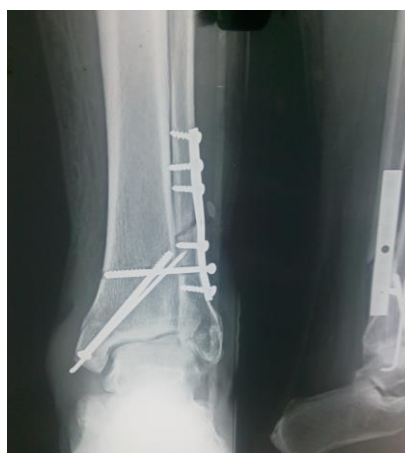
Image representative image

QUADRICORTICAL SCREW

TRICRTICAL SCREWS

Postoperatively all the ankles were splinted kept immobilized for 2 to 3 week. At first post operative visit, sutures were removed and patients were provided with a functional brace. At this time active assisted ankle movements were supervised by physiotherapist or doctor. All patients were kept non wt bearing. At 8-10 weeks follow up visit pts were allow to bear wt as tolerated.

The examination, by the doctor included an evaluation of tenderness active range of movements of ankle, mobility and strength testing. Radiographs AP, LATERAL and stress views were assessed for bony union, maintenance of the ankle mortise breakage of metal and for the development of osteoarthritis. Fracture union was defined as loss of the fracture line in the distal fibula and medial malleolus. Functional status was evaluated at 3 and 6 months visit using olerud molander outcome tool and difference in dorsiflexion. The comparison were made between the groups using unpaired student t-test and Nonparametric Methods with p value of <0.05 defining statistical significance. In order to evaluate the effect that patient's age and weight had on our results, logistic regression analysis were performed, examining the effect of age and weight on each outcome parameter.

**RESULTS**

Between October 2006 and Feb. 2012 a total of 195 patients who underwent surgery for an ankle fracture were entered into database, out of which 44 could be diagnosed to have syndesmotoc rupture and were fixed. Of these 39 had complete follow up allowing inclusion in study. 54% (21) were TSF group and 46% (18) were QSF group.

**Injury Character and Surgical Data**

There was no difference between two groups with respect to time to radiological and clinical union By three months 21 (100%) fractures united in TSF group and 18 (100%) in QSF group. Most common constructs for fixation included lateral plates with syndesmotoc screws (100%) medial fixation with laterally inserted syndesmotoc screws (=90%), and syndesmotoc screws only (0%).

Total seven patients underwent screw removal before 6 months. In TSF group only two cases implants were removed after union first because of infection and second due to loosening while QSF group was re-operated in 3 (16.67%) cases for screw removal in case of implant breakage and in 2 (11%) cases implant removed for infection.

**OM SCORE**

At the end of three months mean OM score was 65.35 (55 to75) for TSF group as compared to 59.58 (55 to 65) in QSF group. Mean values were similar between the two groups with respect to pain (16.4 for tsf and 16.6 for qsf), swelling (4.28 for tsf and 4.16 for qsf), support (6.77 for tsf and6.67 for qsf) running and jumping (1.1 for tsf and 1.25 for qsf). The overall difference noted in two groups was due to difference in functional parameter like stair climbing (7.85 for tsf and 5.00 for qsf) Squatting (3.93 for tsf and 1.67 for qsf) and activities of daily living (12.5 for tsf and 9.16 for qsf).

OM Score	3 months		
	TSF	QSF	Difference
<b>Parameter</b>			
Pain	16.52	16.6	0.08
Swelling	4.24	4.16	0.08
Stair climbing	7.85	5.55	<b>2.35</b>
Running	1.12	1.19	0.07
Jumping	1.12	1.19	0.07
Squatting	3.93	1.87	<b>2.06</b>
Support	6.77	6.67	0.01
Work daily living	12.5	9.9	<b>2.6</b>

At six months there was no significant difference in any parameter of OM score. Hence the overall scores were with non-significant difference {TSF76.42 (70 To80) and QSF72.42 (65 to80)}.

**DIFFERENCE IN DORSIFLEXION**

DID was 11.0 (4 to18) in TSF and 9.75 (6 to13) in QSF with significant difference in two groups. At six months difference was non significant4.75 for TSF and 4.42 for QSF.

Outcomes	TSF Group	QSF Group	Mean Difference
Functional Scores at 3 Months*	65.35	59.58	5.77
Functional Scores at 6 Months	76.42	72.42	4
Dorsiflexion Difference at 3 Months#	11	9.75	1.25
Dorsiflexion Difference at 6 Months	4.75	4.42	0.33

\*Olerud –molander subjective functional score

#Difference in dorsiflexion between fractured and non fracture ankle.

## DISCUSSION

Regaining the fibular length and achieving the correct rotation of the fibula relative to the tibia are absolutely vital for restoration of the proper tibiofibular relationship. Since most pronation external rotation injuries hence Weber type c fractures are associated with rupture of syndesmosis and interosseous membrane, we supplement rigid fixation of the fibula and medial malleolus with some type of trans-syndesmotic fixation after confirming syndesmotic injury under fluoroscopic imaging. Preoperative radiographs and biomechanical criteria are unable to routinely predict the presence or absence of syndesmosis instability. Evidence exists in the literature that the traditional radiographic measurements of ankle fractures do not correlate with injury to the syndesmosis as accurately as once thought. Our consideration that four standard radiographic measurements would not predict syndesmosis injury in ankle fractures, we evaluated all patients with ankle fractures and confirmed intraoperatively. It is probably best to stress test under fluoroscope all ankle fractures after bony stabilisation.

Although the syndesmotic screw is often employed, the published guidelines for its use have been vague and conflicting. Rigid bimalleolar fixation was frequently not sufficient to stabilize syndesmotic disruption. (London Health Sciences Center, University of Western Ontario) and suprasyndesmotic fractures need to be fixed for syndesmosis

Boden et al<sup>(20)</sup> concluded:

- Combination of irreparable medial joint injury along with disruption of the syndesmosis > 4.5 cm proximal to the joint (Weber C), is an indication for surgical fixation;
- Disruption between 3 to 4.5 cm: indication for fixation remains unclear;
- With <3 cm of syndesmotic disruption above plafond, there is little or no alteration was seen of ankle loading characteristics;
- If there is a medial malleolar fracture with the deep deltoid attached stable fixation of this should stabilise the joint, no matter how high the fibular fracture is. A plate would be applied to the fibula if feasible

Van den Bekerom (2010)<sup>(21)</sup> confirmed that Boden's criteria had a specificity of 0.96 but a sensitivity of only 0.39: they are good at ruling in the need for a syndesmosis screw but less at ruling it out.

Deltoid incompetence is present in conjunction with fracture of the medial malleolus (mostly ant malleolus), fixation of the medial malleolus fracture does not necessarily restore competence of the deltoid ligament or stability. If the anterior colliculus is fractures and the mortise is

incongruent, the deep deltoid ligament must also be torn.<sup>(22)</sup>

Current recommendations suggest a low fibula fracture (Weber type B) does not exclude the need for syndesmosis fixation. Up to 27% of even trans-syndesmotic (AO type B) fractures may have significant syndesmotic injuries.<sup>(23)</sup>

Posterior malleolus fracture now considered for fixation for Syndesmotic stabilization. Gardner (2006)<sup>(24)</sup> demonstrated in a cadaver model that posterior malleolar fixation resorted 70% of syndesmosis stability compared with 40% after syndesmotic screw insertion.

The height of a fracture which will require a diastasis screw depends upon the maximum increase in the width of the syndesmosis which is compatible with satisfactory function. This has been reported to vary from 1 mm to 2 mm<sup>25,26</sup>, and our study the maximum permissible increase is 2 mm (i.e. >4 mm medial clear space). Both the 3.5 and 4.5 mm screws demonstrated similar biomechanical characteristics and did not find a biomechanical advantage of a 4.5-mm screw over a 3.5-mm in fixation of the syndesmosis; Biomechanical comparison of syndesmosis fixation with 3.5- and 4.5-millimeter stainless steel screw.<sup>(27)</sup>

As screw removal has been an issue for debate all time. A diastasis screw prevents normal movement between the tibia and fibula, and may encourage the development of a synostosis.<sup>(21)</sup> Weight-bearing with a diastasis screw in place may cause the screw to break or loosen with the appearance of a lucent line around the screw in the tibia.<sup>(28,29)</sup>

Recommendations in the literature range for routine removal of screw before weight bearing is allowed to removal after fracture healed only symptoms develop. Recent literature in general does not support routine removal of the syndesmotic screw and outcome appears to be similar both in retained and removed screws. However, one study showed lower outcome scores in intact retained screws.<sup>(30)</sup> In the reviewed studies, broken screws did not result in an adverse effect on outcome, as broken screws had similar or improved outcome over intact screws. This might be considered a plea for omitting the routine removal of syndesmotic screws. This is reflected in three surveys on syndesmotic screw usage showing increased numbers of retained screws, from 8% in 2004, 14% in 2008 to 35% in 2010. Although widening of the syndesmosis following routine removal of a syndesmotic screw is normal and for the most part clinically insignificant. But, in general, late significant diastasis of syndesmosis creates a much more difficult problem than a broken screw: Broken screw can be removed easily if breakage occurs.<sup>(31)</sup> It is advisable to leave the screw in place for at least 4 months. The higher the fibular

fracture the more widening will occur.<sup>(32)</sup> Even screw break Retention of the syndesmotic fixation even in the face of mechanical failure does not appear to pose a significant problem.<sup>(33)</sup> considering it we went with the choice of leaving the screw in place during the study.

To evaluate the results we used the OM score which is more of a subjective score and DID score which is an objective test based on biomechanical recovery of joint. As dorsiflexion requires a good joint anatomy and mechanics. Our study on 39 fractures of the ankle confirmed the finding of previous reports that open reduction and internal fixation using the AO-ASIF method is an excellent treatment for fractures of the ankle that are having syndesmotic injury. A good or excellent result was obtained in 90 per cent of our patients.

It was impossible for us to compare the group treated operatively and a corresponding group treated non-operatively, either in our own institutions or as reported in the literature. The latter group would be hard to come by because the fractures under discussion do not lend themselves to anatomical reduction by closed methods. According to Sneppen, Weber found that the lateral malleolus carries about one-fifth of the talar pressure. In addition, it has been suggested that shortening and lateral displacement of the fibula are the most common causes of osteoarthritis of the ankle after fracture. Incongruities between the tibia and talus that result in osteoarthritic changes can be related to malreduction of the syndesmosis or of the fibula, allowing lateral displacement of the talus.

## CONCLUSION

Study confirmed that Syndesmosis fixation with 2 tricortical screws is safe and improves early function. After 6 months, however, there were no significant differences (hence inconclusive) between the 2 groups in functional score, pain, and dorsiflexion.

## REFERENCES

- Daly PJ, Fitzgerald RH, Jr., Melton LJ, et al (1987) Epidemiology of ankle fractures in Rochester, Minnesota. *Acta Orthop Scand*; 58:539-44.
- Jensen SL, Andresen BK, Mencke S, et al (1998) Epidemiology of ankle fractures. A prospective population-based study of 212 cases in Aalborg, Denmark. *Acta Orthop Scand*; 69:48-50.
- Dubin JC, Comeau D, McClelland RI, Dubin RA, Ferrel E. Lateral and syndesmotic ankle sprain injuries: a narrative literature review. *J Chiropr Med*. 2011 Sep;10(3):204-19. Epub 2011 Jul 23.
- Kellett JJ. The clinical features of ankle syndesmosis injuries: a general review. *Clin J Sport Med*. 2011 Nov;21(6):524-9.35 Wright RW, Barile RJ, Surprenant DA, Matava MJ. Ankle syndesmosis sprains in national hockey league players. *Am J Sports Med*. 2004; 32(8): 1941-1945.
- Hopkinson WJ, St. Pierre P, Ryan JB, Wheeler JH. Syndesmosis sprains of the ankle. *Foot Ankle*. 1990;10:325-330.
- Boytim MJ, Fischer DA, Neumann L. Syndesmotic ankle sprains. *Am J Sports Med*. 1991;19:294-298.
- Kleiger B. The mechanism of ankle injuries. *J Bone Joint Surg Am*. 1956;38:59-70.
- Edwards GS, Jr., De Lee JC. Ankle diastasis without fracture. *Foot Ankle*. 1984;4:305-312.
- Pankovich AM. Maisonneuve fracture of the fibula. *J Bone Joint Surg Am*. 1976;58:337-342.
- Fritschy D. An unusual ankle injury in top skiers. *Am J Sports Med*. 1989;17:282-286.
- Taylor DC, Bassett FH. Syndesmosis ankle sprains: diagnosing the injury and aiding recovery. *Physician Sports med*. 1993;21(12):39-46.
- Turco VJ. Injuries to the ankle and foot in athletics. *Orthop Clinics North Am*. 1977;8:669-682.
- Grath GR. Widening of the ankle mortise: a clinical and experimental study. *Acta Chir Scand Suppl*. 1995;263(66):1-46.
- Ramsey PL, Hamilton W. Changes in tibiotalar area of contact caused by lateral talar shift. *J Bone Joint Surg Am*. 1976;58(3):356-357.
- Zalavras C, Thordarson D. Ankle syndesmotic injury. *J Am Acad Orthop Surg*. 2007;15:330-9.
- Zalavras C, Thordarson D. Ankle syndesmotic injury. *J Am Acad Orthop Surg*. 2007;15(6):330-339.
- Briggs and Burrow; Injury Volume 35, Issue 8, August 2004, Pages 814-818.
- Weber BG. Lengthening osteotomy of the fibula to correct a widened mortise of the ankle after fracture. *Int Orthop*. 1981;4:289-93.
- Boden, S. D; labropoulos, P. A; mc Cowin, P; lestini W. F; and Hurwitz S. R: mechanical considerations of syndesmosis screw. A cadaver study. *J bone and joint Surg.*,71-a 1548-1555,dec 1989.
- Van den Bekerom MP, Hogervorst M, Bolhuis HW, van Dijk CN (2008) Operative aspects of the syndesmotic screw: review of current concepts. *Injury* 39(4):491-498.
- Paul Tornetta Competence of the Deltoid Ligament in Bimalleolar Ankle Fractures after Medial Malleolar Fixation 2000; *J Bone Joint Surg.*, 82A (6):843 -48.
- Stark E<sup>1</sup>, Tornetta P 3rd, Creevy WR Syndesmotic instability in Weber B ankle fractures: a clinical evaluation *J Orthop Trauma*. 2007 Oct; 21(9):643-6.
- Gardner, Michael J; Brodsky, Adam; Briggs, Stephen M; Nielson, Jason Clinical Orthopaedics & Related Research: June 2006 - Volume 447 - Issue - pp 165-171.
- Leeds HC, Ehrlich MG. Instability of the distal tibiofibular syndesmosis after bimalleolar & trimalleolar fractures. *Jb ONE JOINT Surg. (AM)* 1984;66A:490-503.
- Pttrone F. A; gail, Mitchell; pee, david; Fitzpatrick, Thomas; and van herpe L. B: quantitative criteria for predilection of the results after displaced fracture of ankle. *J bone and joint surg.*, 65-a:667-677, June 1983.
- Thompson MC, Gesink DS (2000) Biomechanical comparison of syndesmosis fixation with 3.5- and 4.5-millimeter stainless steel screws. *Foot Ankle Int* 21(9).
- Kayue RA. Stabilisation of ankle syndesmosis injuries with a syndesmosis screw. *Foot & ankle* 1989;9:290-3.
- Stiehl JB, Schwartz HS, Long term of pronation-external rotation ankle fracture dislocations treated with anatomical open reduction, internal fixation. *J Orthop Trauma* 1990;4:339-45.
- Manjoo A, Sanders DW, Tieszer C, MacLeod MD (2010) Functional and radiographic results of patients with

- syndesmotic screw fixation: implications for screw removal. *J Orthop Trauma* 24 (1):2–6.
30. Melvin JS, Downing KL, Ogilvie CM (2008) A technique for removal of broken cannulated tricortical syndesmotic screws. *J Orthop Trauma* 22(9):648–651.
  31. AAOS Podium presentation, San Diego, USA Wahlquist M, Ebraheim NA, Foster SA Toledo OH.
  32. John R. Shank, MD; Steven J. Morgan, MD Wade R. Smith foot & ankle international / American Orthopaedic Foot and Ankle Society [and] Swiss Foot and Ankle Society. 09/2006; 27(8):567-72.