

Piercing Injury of Thigh with Branch of Tree

Rajendra Kumar Ahire¹, Harshal sakale^{2,*}, Vinit K Jain³

^{1,2}Assistant Professor, ³Associate Professor, Dept. of Orthopaedics,
Pt. JLN Memorial Medical College & Bhimrao Ambedkar Hospital, Raipur, Chattisgarh

***Corresponding Author:**

Email: harshal2082@rediffmail.com

ABSTRACT

Penetrating injuries are dangerous and deserve emergency treatment due to the risk of injuring vital structures. We present an unusual case of a young male patient who sustained piercing injury of thigh with a tree branch due to fall from the tree. Careful planning, proper evaluation of such patient is required before extracting such foreign bodies.

Key words: Penetrating, Foreign body, Thigh

Access this article online	
Quick Response Code:	Website: www.innovativepublication.com
	DOI: 10.5958/2395-1362.2015.00026.2

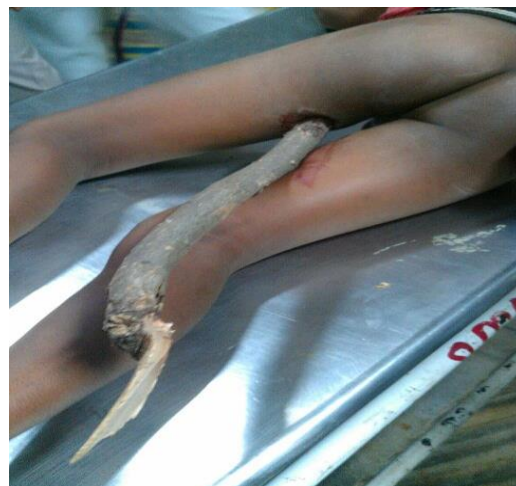INTRODUCTION

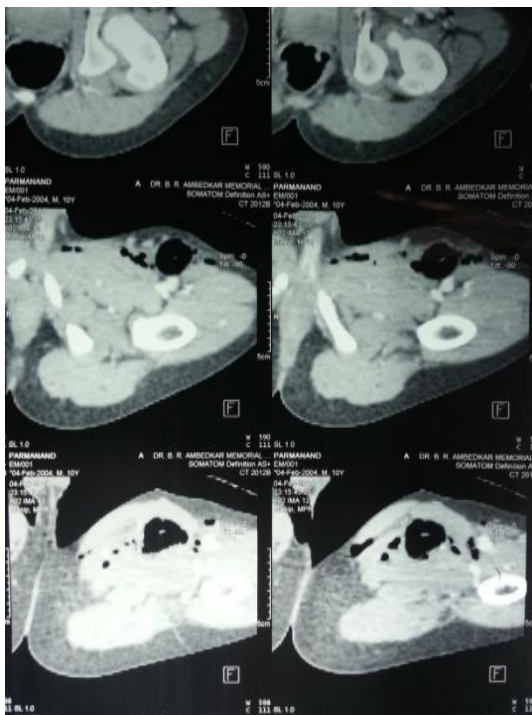
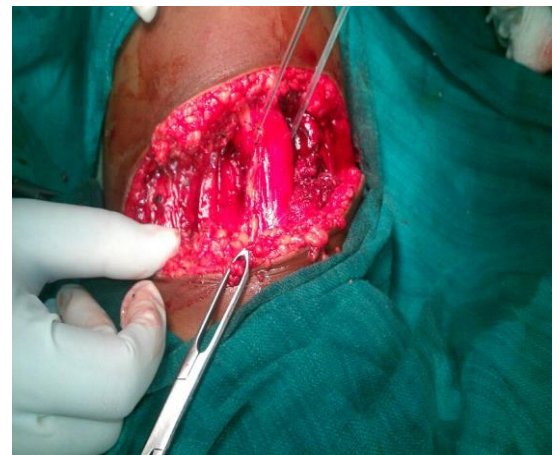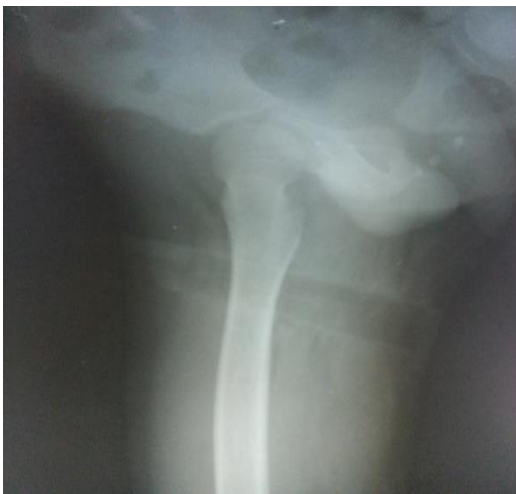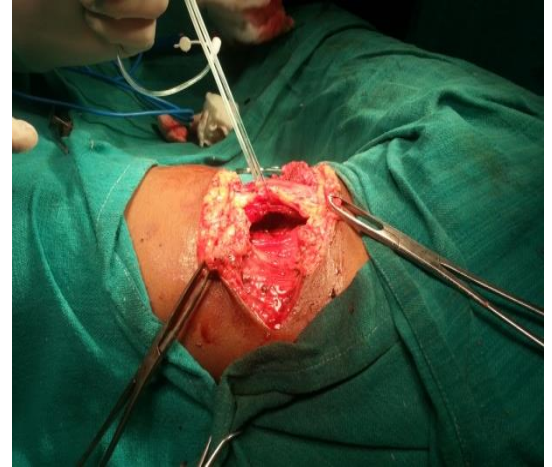
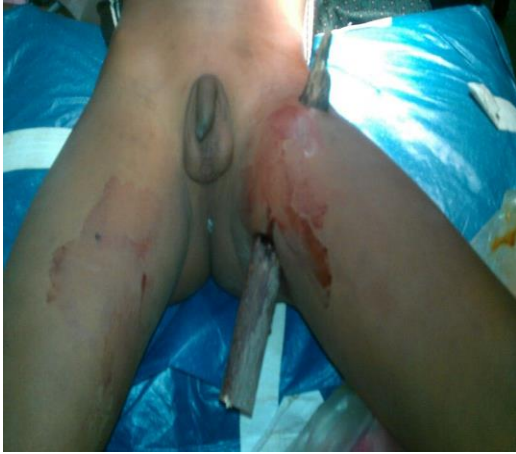Patients presenting with Piercing foreign bodies like large wooden stick through the extremities is unusual and uncommon in day to day orthopaedic and Traumatology practice. These patients need an emergent intervention as these large foreign bodies have potential of causing complication.

CASE REPORT

A 10 year old male patient suffered a fall from the tree over the adjoining small tree resulting in the penetrating injury to his left thigh with the branch of small tree (fig [A]). This patient presented during evening hours in Department of orthopaedic and traumatology of Pandit Jawaharlal Nehru Memorial Medial College and Bhimrao Ambedkar hospital Raipur. On initial examination patient was lying prone, with a large branch of tree of approximately 4 feet penetrating through and through in the proximal thigh. The branch was entering the thigh through posteromedial aspect and exiting through the anterolateral aspect through Scarpa's triangle [fig B]. There was no active bleeding and femoral pulsation was equal on both sides with intact distal neurovascular status. Initially patient was transfused crystalloids and administered broad spectrum antibiotics. Immediate cutting of excess of wood length was done in emergency room itself by hexa blade holding the proximal fragment firmly so that the stick could not roll on [fig B]. The limb was immobilized and no manipulation of the piercing tree branch was done in the emergency room lest it may

lead to disastrous bleeding. X-Ray left hip with thigh and Doppler study of the left lower limb was done. They revealed that there was no bony and vascular injury [fig C]. Since the foreign body was exiting from scarpa's triangle and very close to femoral artery a CT-Angiography was performed. It was found that the rough external surface of foreign body was touching the Tunica-adventitia of femoral Artery [fig D]. After proper informed consent and preanaesthetic work up, the patient was taken for emergency wound exploration and removal of foreign body. An Anterior oblique incision was given in proximal thigh extending from medial to lateral, in the direction of foreign body. The entry and exit point were explored thoroughly, by blunt dissection. The under surface of the foreign body was separated from the vascular bundle carefully. After carefully separating the foreign body from all around, it was extracted with the help of naso gastric tube. The wound was washed with hydrogen peroxide and Betadine solution and Closed in layers [Fig E, F]. The patient recovered and was discharged on 15th day.





DISCUSSION

Piercing or penetrating injury of the extremities is rare. Though rare, they can lead to catastrophic neurovascular complications. Our patient recovered uneventfully, probably due to the relatively uncomplicated track of the foreign body without any associated injuries of neurovascular structures. Diagnostic modalities like Doppler and C.T scan are helpful before exploration of such foreign bodies. A penetrating axillary injury with branch of tree had been reported which was extracted after thorough exploration of wound¹. In another case piercing injury of pelvis by steel bar was reported which was later extracted after proper investigation and exploratory laparotomy². Similar case was reported in Chinese medical journal in which there was penetrating trauma to pelvis by steel bar, that bar was extracted uneventfully³. Foreign body injuries may result in complications such as infection, migration and neurovascular injury. Hence it is important to do complete physical and radiological examination to achieve the best outcome⁴. We conclude that these piercing foreign bodies are rare but they require emergent treatment by proper use of diagnostic modalities and early operative intervention, and

extraction after thorough exploration of the complete tract. No attempt should be made to extract the foreign body in emergency room as it might be tamponading a major vessel injury and its removal may lead to torrential bleeding; hence, it should always be performed under controlled settings in the operating room.

REFERENCES

1. Mouaffak Y¹, Elfadel B, Boutbaoucht M, El Adib AG, Younous S, Aderdour L, El Fezzazi R. A case of penetrating axillary trauma. *Rev Stomatol Chir Maxillofac*. 2011 Dec;112(6):369-71. doi: 10.1016/j.stomax.2011.08.002. Epub 2011 Sep 28.
2. Soon Hyuck Lee, MD; Si Young Park, MD; Jin Kim, MD; Young-Jae Huh, MD Piercing Injury of the Pelvis With a Steel Bar *Orthopedics* January 2012 - Volume 35(1): e88-e90.
3. ZHANG Peng, HU Jing-mei and ZHOU Dong-sheng* Surgical management of penetrating pelvic trauma: a case report and literature review *Chinese Journal of Traumatology* 2012;15(6):364-366.
4. Tuhan KURTULMUfi, Necdet SALAM, Gürsel SAKA, Mehmet ÇMAM, Fuat AKPINAR Tips and tricks in the diagnostic workup and the removal of foreign bodies in extremities *Acta Orthop Traumatol Turc* 2013;47(6):387-392 doi:10.3944/AOTT.2013.2979.